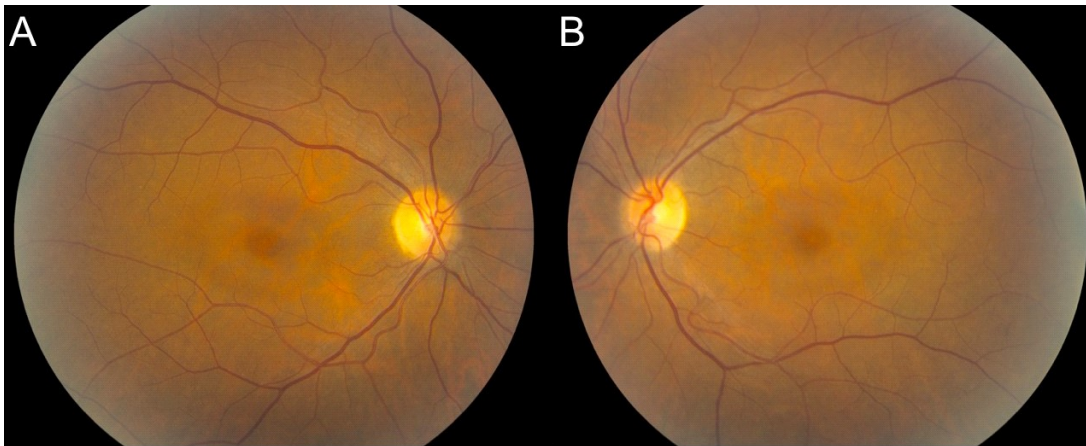

Examples of examination findings indicating medication-induced toxicity

- **Fundus photo/retinal exam:**

Example showing abnormal mild paracentral depigmentation of the RPE that spares the central fovea



- **Auto-fluorescence imaging by scanning laser ophthalmoscope (SLO):**

Example showing an abnormal increase in signal in the parafoveal region

