



TFOS DEWS II Management and Therapy Report



Lyndon Jones, FCOptom, PhD ^{a, 1, *}, Laura E. Downie, BOptom, PhD ^b, Donald Korb, OD ^c, Jose M. Benitez-del-Castillo, MD, PhD ^d, Reza Dana, MD ^e, Sophie X. Deng, MD, PhD ^f, Pham N. Dong, MD ^g, Gerd Geerling, MD, FEBO ^h, Richard Yudi Hida, MD ⁱ, Yang Liu, MD ^j, Kyoung Yul Seo, MD, PhD ^k, Joseph Tauber, MD ^l, Tais H. Wakamatsu, MD, PhD ^m, Jianjiang Xu, MD, PhD ⁿ, James S. Wolffsohn, FCOptom, PhD ^o, Jennifer P. Craig, MCOptom, PhD ^p

^a Centre for Contact Lens Research, School of Optometry and Vision Science, University of Waterloo, Waterloo, Canada

^b Department of Optometry and Vision Sciences, University of Melbourne, Parkville, Victoria, Australia

^c Korb & Associates, Boston, MA, USA

^d Department of Ophthalmology, University of Complutense, Madrid, Spain

^e Department of Ophthalmology, Harvard Medical School, Massachusetts Eye and Ear Infirmary, Boston, MA, USA

^f Stein Eye Institute, UCLA, Los Angeles, CA, USA

^g Department of Corneal and External Disease, Vietnam National Institute of Ophthalmology, Hanoi, Viet Nam

^h Department of Ophthalmology, University Hospital Duesseldorf, Germany

ⁱ Department of Ophthalmology, Santa Casa de Sao Paulo, University of Sao Paulo, Sao Paulo, Brazil

^j Schepens Eye Research Institute, Massachusetts Eye & Ear, Boston, MA, USA

^k Department of Ophthalmology, Yonsei University Medical College, Seoul, South Korea

^l Tauber Eye Center, Kansas City, MO, USA

^m Department of Ophthalmology and Visual Sciences, Paulista School of Medicine, São Paulo Hospital, Federal University of São Paulo, São Paulo, Brazil

ⁿ Department of Ophthalmology and Visual Science, Eye, and ENT Hospital, Shanghai Medical College, Fudan University, China

^o Ophthalmic Research Group, Aston University, Birmingham, UK

^p Department of Ophthalmology, New Zealand National Eye Centre, The University of Auckland, Auckland, New Zealand

ARTICLE INFO

Article history:

Received 2 May 2017

Accepted 3 May 2017

Keywords:

Dry eye disease
Dry eye workshop
Management
TFOS DEWS II
Therapy

ABSTRACT

The members of the Management and Therapy Subcommittee undertook an evidence-based review of current dry eye therapies and management options. Management options reviewed in detail included treatments for tear insufficiency and lid abnormalities, as well as anti-inflammatory medications, surgical approaches, dietary modifications, environmental considerations and complementary therapies. Following this extensive review it became clear that many of the treatments available for the management of dry eye disease lack the necessary Level 1 evidence to support their recommendation, often due to a lack of appropriate masking, randomization or controls and in some cases due to issues with selection bias or inadequate sample size.

Reflecting on all available evidence, a staged management algorithm was derived that presents a step-wise approach to implementing the various management and therapeutic options according to disease severity. While this exercise indicated that differentiating between aqueous-deficient and evaporative dry eye disease was critical in selecting the most appropriate management strategy, it also highlighted challenges, based on the limited evidence currently available, in predicting relative benefits of specific management options, in managing the two dry eye disease subtypes.

Further evidence is required to support the introduction, and continued use, of many of the treatment options currently available to manage dry eye disease, as well as to inform appropriate treatment starting points and understand treatment specificity in relation to dry eye disease subtype.

© 2017 Elsevier Inc. All rights reserved.

* Corresponding author.

E-mail address: lwjones@uwaterloo.ca (L. Jones).

¹ Subcommittee Chair

1. Introduction

This report summarizes the management and therapeutic options for treating dry eye disease (DED). The goals of this committee were to review appropriate methods for the management of DED and recommend a strategy for their clinical application, based on an evidence-based review of the literature. The level of evidence for supporting data from the literature is evaluated according to the modified American Academy of Ophthalmology Preferred Practices guidelines (Table 1).

Wherever possible, peer-reviewed publications, rather than abstracts, have been used to guide management recommendations. In some instances, due to the relatively recent introduction of the therapy under discussion, this was not possible. The report was reviewed by all subcommittee members and made available for constructive critique by the entire Tear Film and Ocular Surface Society's Dry Eye Workshop II (TFOS DEWS II) membership. Comments and suggested revisions were discussed by the subcommittee members and incorporated into the report where deemed appropriate by consensus.

Advances in our understanding of the risk factors, etiology and pathophysiology of DED have contributed to an evolution in treatment strategies over time. In the years following publication of the original TFOS Dry Eye Workshop (DEWS) Management and Therapy Report [1], there has been a growing realization of the important contribution of meibomian gland dysfunction (MGD) to both symptoms and signs of DED [2].

While classification is discussed in greater depth in other sections of this report [3], it is important to note that diagnostic labels have a significant bearing on subsequent management and treatment. It is generally believed that rather than representing two distinct categories, most people with symptoms related to ocular surface disease (OSD) suffer from variable combinations of both abnormal meibomian gland physiology (resulting in evaporative DED) and tear underproduction (resulting in aqueous deficient DED). Estimates of the degree of overlap of these two categories have ranged from 30 to 70%, but these are estimates made by clinicians using clinical judgment. One published study found patients with DED were over three times more likely to be subclassified as having evaporative dry eye (EDE) than aqueous deficient dry eye (ADDE), and over 30% of patients had both types of DED [4].

Regardless of the accuracy of these figures, clinicians around the world recognize the necessity to treat “dry eye patients” in a comprehensive way, taking into account their symptoms, meibomian gland physiology, tear film lipid quality and quantity, meibomian gland orifice patency, and also tear production, loss and runoff [5–9]. If only one of these two broad categories of OSD (EDE and ADDE) is addressed therapeutically, patients may continue to

suffer symptoms and report dissatisfaction with the prescribed treatment. It is necessary to first diagnose patients accurately, with respect to recognizing the major cause behind their DED, before crafting a treatment plan. Further information on diagnosis of OSD is covered in the TFOS DEWS II Diagnostic Methodology Report [10].

2. Treatments for tear insufficiency

Historically, DED was considered to be largely due to tear insufficiency and was treated by prescribing tear replacement products or by conserving the tears via punctal plugs. More recent treatments have included the use of methods to stimulate tears.

2.1. Tear replacement approaches

Tear replacement with ocular lubricants is traditionally considered a mainstay of DED therapy and there are numerous topical formulations available. Over-the-counter (OTC) products are often termed “artificial tears” which, as their name suggests, attempt to replace and/or supplement the natural tear film. However, these products do not target the underlying pathophysiology of DED, and the mechanisms of any palliative actions are generally poorly understood.

2.1.1. Artificial tear substitutes

Tear substitutes comprise a wide variety of products, which typically aim to target one or more layers of the tear film. The wide variety of properties of these ocular lubricants has been reviewed elsewhere [11–15].

Ocular lubricants are largely regarded as safe, although there are some reported side effects, most notably blurred vision, variable levels of “ocular discomfort” and foreign body sensation [16]. There are relatively few randomized controlled trials (RCTs) that have compared the relative superiority of a particular OTC product to others for DED therapy [17]. A recent Cochrane systematic review, which sought to evaluate the effect of OTC tear supplement products for treating DED, included 43 randomized controlled trials that had compared artificial tear formulations to no treatment, or placebo [16]. The primary outcome measure was patient-reported symptoms. The authors reported that the overall quality of evidence was low for the various tear supplement formulations compared in the review, and concluded that while artificial tears may be effective for treating DED, there was still a need for future research to enable robust conclusions to be drawn about the effectiveness of individual OTC artificial tear formulations.

2.1.1.1. Aqueous supplementation. While ocular lubricant formulations may vary in osmolarity, viscosity and pH, most share similarities in their major components. The most abundant component

Table 1
Research evidence grading scheme.

Clinical Studies	
Level 1	Evidence obtained from at least one properly conducted, well-designed, randomized, controlled trial, or evidence from well-designed studies applying rigorous statistical approaches
Level 2	Evidence obtained from one of the following: a well-designed controlled trial without randomization, a well-designed cohort or case-control analytic study, preferably from one or more centers, or a well-designed study accessible to more rigorous statistical analysis
Level 3	Evidence obtained from one of the following: descriptive studies, case reports, reports of expert committees, expert opinion
Basic Science Studies	
Level 1	Well-performed studies confirming a hypothesis with adequate controls published in a high-impact journal
Level 2	Preliminary or limited published study
Level 3	Meeting abstracts or unpublished presentations

in lubricant eye drops is the aqueous base. To enhance lubrication and prolong the retention time on the ocular surface, a variety of viscosity enhancing agents are frequently incorporated.

2.1.1.1.1. Viscosity-enhancing agents. The viscosity-enhancing agents used in tear supplement formulations include carbomer 940 (polyacrylic acid), carboxymethyl cellulose (CMC), dextran, hyaluronic acid (HA), HP-guar, hydroxypropyl methylcellulose (HPMC), polyvinyl alcohol (PVA), polyvinylpyrrolidone (PVP) and polyethylene glycol.

Viscosity enhancers are considered beneficial to the ocular surface in DED through a range of reported mechanisms. These include increasing tear film thickness, protecting against desiccation, promoting tear retention at the ocular surface, protecting the ocular surface, maintaining physiological corneal thickness, improving goblet cell density and relieving dry eye symptoms [18,19]. Although there are scores of formulations and products available, which vary by geographic region, there does not appear to be any substantial difference in effectiveness among them [16,20]. However, the differences in the viscosity of the drops can influence utilization. Eye drops with high viscosity can increase retention time on the ocular surface, but may also cause transient visual disturbances and result in unwanted debris on the eyelids and lashes, leading to decreased tolerance and compliance. Very high viscosity eye drops are typically recommended for overnight use, with low-viscosity drops being used in the daytime.

2.1.1.1.1.1. Carboxymethyl cellulose (CMC)

CMC is a cellulose derivative with carboxymethyl groups and is formed from the cell walls of plants. It is often used as its sodium salt, sodium carboxymethyl cellulose, and is also termed carmellose sodium. It is a very commonly used viscosity-enhancing agent in ocular lubricants as well as in pharmaceuticals, foods and cosmetics [21].

CMC can bind to corneal epithelial cells and promote epithelial cell healing [22,23]. CMC-based products have been proven to be successful in the management of mild-to-moderate dry eye in a number of studies [24–26].

2.1.1.1.1.2. Hydroxypropyl methylcellulose (HPMC)

Cellulose ethers are viscoelastic polysaccharides that increase the viscosity of the tears. Of these, HPMC has been used for many years in artificial lubricants and remains one of the most common ingredients. It is available in a wide variety of concentrations (from 0.2 to 0.8%) and is used in combination with many other components in modern ocular lubricants [11,14]. Due to its wide availability and use over many years, multiple studies have explored its potential to manage patients with DED [16]. A review of its performance shows that it is a safe and effective lubricant for those with low-to-moderate symptoms of DED [16].

2.1.1.1.1.3. Hyaluronic acid (HA)

Hyaluronic acid (HA), also termed hyaluron and sodium hyaluronate, is a naturally occurring anionic, non-sulfated glycosaminoglycan that is distributed widely throughout connective, epithelial, and neural tissues. It can be very large, with its molecular weight often reaching several million Daltons. HA is an important component of articular cartilage and is found in abundance in synovial fluid around joints, in the vitreous and aqueous humour [27]. A number of studies have demonstrated its ability to bind to ocular surface cells and its potential wound healing properties [28–33].

HA is used in a variety of tear supplements to increase viscosity and provide enhanced lubrication. HA exhibits non-Newtonian shear-thinning properties [34], where viscosity varies with shear rate. For HA-based solutions, the viscosity decreases with increasing shear rate, as occurs during a blink.

As the range of commercial products that contain HA increases, a growing number of Level 1 and 2 clinical studies have been published that demonstrate good tolerability and the ability to

improve dry eye symptoms [35–42].

2.1.1.1.1.4. Combination of CMC and HA

As described above, there are a number of publications supporting the use of topical drops that contain CMC or HA in the management of DED. Optive Fusion™ (Allergan, Parkway Parsippany, NJ, USA) contains a combination of 0.5% CMC and 0.1% HA in a single topical formulation. In a murine dry eye study, mice administered CMC + HA topically showed significantly lower corneal fluorescein staining and higher goblet cell density than mice treated with drops containing CMC or HA alone [43]. In a 3-month, double-masked, multicenter study involving 305 subjects with DED, the commercially available combination of CMC + HA improved symptoms and signs of DED more than a commercially available topical formulation based on CMC alone [44].

2.1.1.1.1.5. Hydroxypropyl-guar (HP-guar)

HP-guar is a non-ionic, polymeric thickener that can rapidly confer high viscosity, through a pH-dependent process [45,46]. One HP-guar-based product, Systane® ULTRA (Alcon, Ft Worth, TX, USA), includes two demulcents (polyethylene glycol 400 and propylene glycol), and sorbitol, and is buffered with borate, resulting in a partially crosslinked borate/HP-guar gel in the bottle [47]. The pH of Systane ULTRA is 7.9 but when instilled onto the ocular surface, the reduction in pH, and dilution of the sorbitol concentration, increases the density of the borate/hydroxypropyl-guar crosslinks, producing a very low viscosity gel [45].

HP-guar-based products have been shown to improve dry eye symptoms, increase mucous layer thickness, reduce inflammation and protect the ocular surface [47–53].

2.1.1.1.1.6. Combination of HA and HP-guar

A formulation containing the demulcents propylene glycol and polyethylene glycol and a dual polymer combination of HA and HP-guar (Systane® ULTRA HYDRATION; Alcon, Ft Worth, TX, USA) has been shown to be effective in desiccation protection and retention on the ocular surface in a corneal cell-based laboratory study [54].

2.1.1.1.1.7. Hydroxypropyl cellulose

The concept of using a dissolvable hydroxypropyl cellulose insert on the ocular surface to manage DED was first approved by the Food and Drug Administration (FDA) over 30 years ago, but for many years lost favour due to discomfort and relatively poor efficacy [55]. The newest version of this concept is LACRISERT™ (Bausch & Lomb, Rochester, NY, USA), which is a sterile, translucent, rod-shaped, water soluble, preservative-free, slow-release lubricant that is placed into the inferior cul-de-sac with the aid of a reusable applicator. It begins to soften within minutes, dissolving over the course of about 12 h and thickening the precorneal tear film. It is recommended for use in patients with moderate to severe DED, is usually inserted once a day and is contraindicated in patients who are hypersensitive to hydroxypropyl cellulose.

A multicenter, 2-visit, open-label, 4-week study was conducted to determine the acceptability of the inserts in 520 subjects with DED [56]. There was a significant improvement in symptoms, corneal fluorescein staining, conjunctival staining and tear volume. Contact lens wearers reported significant improvements, similar to non-wearers. Reported complications include transient blurring of vision, discomfort or irritation (particularly if not located appropriately), expulsion in patients with shallow conjunctival fornices and matting or stickiness of the eyelashes.

2.1.1.1.2. Osmotic agents. The original TFOS DEWS report drew attention to the importance of tear osmolarity, demonstrating that raised tear osmolarity is associated with DED [57]. Since that time, many studies have examined the link between DED and osmolarity. However, relatively few studies have investigated the impact of tear supplement hypo- or hyper-osmolar drops on tear osmolarity and any improvements in DED. Gilbard conducted a number of experiments to show that the use of a hypo-osmolar ocular lubricant

could reverse various ocular surface changes (notably reduced goblet cell density) induced in a dry eye rabbit model [58–60]. Two more recent studies using hypotonic hyaluronic acid-based ocular lubricants demonstrated an improvement in both symptoms and various signs of DED [61,62]. However, more studies linking the ability of lubricants to reduce tear film osmolarity and their impact upon DED symptoms and signs are warranted.

A number of published studies demonstrate the potential to improve tear osmolarity with DED treatments [63–70], even in the absence of a change [71,72], or in association with negative outcomes [68,73,74], in other clinical features.

Since the publication of the first TFOS DEWS report, several examples of tracking dry eye therapy with tear osmolarity have been published. A study investigating the effects of a combination therapy of methylprednisolone and preservative-free 0.1% HA four times a day demonstrated a significant reduction in osmolarity at eight weeks that paralleled significant reductions in IL-1 β and IL-8, as well as tear break up time (TBUT), corneal and conjunctival staining [75]. The authors concluded that measuring the changes in cytokine levels and tear osmolarity could objectively evaluate the anti-inflammatory effects of topical methylprednisolone applied in the treatment of patients with moderate to severe dry eye syndrome. A similar eight-week trial of a modified HA applied three times daily resulted in significant improvements in Ocular Surface Disease Index (OSDI) score, TBUT, conjunctival goblet cell density, corneal and conjunctival damage and tear osmolarity [66].

Tear osmolarity has also been shown to parallel improvements in dry eye symptoms and signs when patients use topical cyclosporine [63,76,77], HA [40,66,78–80], osmoprotective drops [40,67,69], and PEG/HP-Guar drops [81].

2.1.1.1.3. Osmoprotectants. Osmoprotectants (e.g., L-carnitine and betaine) are a group of compatible solutes that protect cells under extreme osmotic stress by balancing the osmotic pressure without disturbing cell metabolism [82–85]. The osmoprotective effect depends on the amount of drug uptake and its retention time, and combinations of osmoprotectants with different pharmaceutical kinetics may function better than individual osmoprotectants.

There are a number of studies demonstrating that osmoprotectants have a beneficial effect on the treatment of DED. An *in vitro* study showed that the osmoprotectants L-carnitine and erythritol can protect cultured human corneal epithelial cells from hyperosmolar conditions by lowering levels of activated mitogen-activated protein kinases [86]. The osmoprotectants also showed inflammatory-suppressing properties under hyperosmotic stress [87]. A dry eye mouse study showed that osmoprotectants can reduce corneal staining, decrease cell apoptosis and inflammatory cytokines and increase the number of goblet cells [88].

Trehalose is a naturally occurring disaccharide, present in numerous non-mammalian species, which allows cells to survive in unfavorable environments. It is implicated in anhydrobiosis, which relates to the ability of plants and animals to withstand prolonged periods of desiccation. It has very high water retention capabilities and has the dual properties of both bioprotection and osmoprotection [89–94]. *In vitro* and *in vivo* studies have shown that trehalose protects corneal cells from desiccation [95], as well as protecting corneal and conjunctival cells against apoptosis [90,96]. Trehalose has also been shown to protect corneal cells against ultraviolet (UV)-induced oxidative damage by accelerating corneal healing [97], and reducing conjunctival inflammatory cytokines in a murine model of DED [92]. It also helps to restore osmotic balance to the ocular surface, as well as preventing denaturation of cell membrane lipid bilayers and proteins to maintain the homeostasis of corneal cells [90–92].

A new eye drop formulation that contains both HA and trehalose has been developed to capitalize on the lubricant properties of HA

and bioprotectant properties of trehalose [98].

2.1.1.1.4. Antioxidants. The presence of oxygen free radicals in the tears of patients with DED [99] has resulted in exploration of the potential application of antioxidants for the management of DED.

In an animal study, topical acetylcysteine, an amino acid with antioxidant activity, decreased inflammatory cytokine expression in ocular surface tissues of a mouse model of DED, but did not alter corneal staining [100]. Another antioxidant eye drop, vitamin A (retinyl palmitate), showed significant effects in improving blurred vision, TBUT, Schirmer score, and impression cytology findings in subjects with DED in a prospective, randomized, controlled, parallel study [101]. However, vitamin A metabolites are also known to cause MGD in animal models, including glandular keratinization and atrophy, reduced quality of meibum, reduced tear film break up time, increased tear film osmolarity, and dry eye symptoms (further details are included in the TFOS DEWS II Iatrogenic Dry Eye Report) [102].

A study using stratified human corneal limbal epithelial cells showed that several antioxidants may be beneficial if incorporated into topical ocular lubricants [103]. Quercetin, epigallocatechin gallate, n-propyl gallate, and gallic acid displayed good bioavailability, were effective at quenching reactive oxygen species and might be effective in protecting the corneal epithelium from oxidative damage.

Visomitin is the first registered drug with antioxidative properties that targets oxidative stress in mitochondria and is available as a topical drug in Russia. A recent multicenter, randomized, double-masked, placebo-controlled clinical study showed that a 6-week course of topical Visomitin reduced corneal staining and improved symptoms in 240 subjects with DED [104]. It may act through reducing reactive oxygen species on the ocular surface, but further studies are required to confirm this.

Selenoprotein P (SelP) is a secreted glycoprotein that is involved in the transport or storage of selenium, and is involved in oxidative stress metabolism [105]. In a rat dry eye model, the use of SelP eye drops for 3 weeks suppressed markers of oxidative stress and tears collected from human subjects with corneal staining were lower in SelP [106]. The authors concluded that tear SelP is a key molecule to protect the ocular surface against environmental oxidative stress.

2.1.1.1.5. Preservatives. Multidose artificial lubricants typically require a preservative to prevent microbial growth, whereas unit dose vials that are discarded after a single use do not. However, unit dose vials are more expensive and may be more difficult for less dextrous individuals to open. A number of new products are now available that utilize dispensers that incorporate unidirectional valves that allow multidose bottles to be unpreserved.

Increasing attention has been directed to the relationship between the chronic use of topical therapies, such as glaucoma medications, and OSD. Chronic exposure of the ocular surface to preservatives is now well recognized to induce toxicity and adverse changes to the ocular surface [107–112]. Benzalkonium chloride (BAK) is the most frequently used preservative in eye drop preparations. There are many *in vitro* and *in vivo* studies demonstrating that BAK can induce corneal and conjunctival epithelial cell apoptosis, damage the corneal nerves, delay corneal wound healing, interfere with tear film stability and cause loss of goblet cells [113–115]. In an *in vitro* study, a BAK concentration in excess of 0.005% significantly impaired lipid spreading and compromised the morphology of the tear lipid layer [116]. Sufficient evidence exists to confirm that patients with DED, particularly those with severe DED who require frequent dosing with lubricants or who use ocular lubricants in conjunction with other chronic topical therapies, such as glaucoma medications, should avoid the use of ocular lubricants preserved with BAK [102].

To avoid issues with long-term exposure to preservatives, newer

variants of preservatives designed to have a lower impact on the ocular surface have been developed, including oxidative preservatives (sodium chlorite; Purite[®] and OcuPure[™] and sodium perborate; GenAqua[™]), polyquaternium-1 (Polyquad[®]) and SofZia[™]. Sodium chlorite degrades to chloride ions and water upon exposure to UV light after instillation and sodium perborate is converted to water and oxygen on contact with the tear film. Some reports suggest that even these so-called “disappearing preservatives” can show some negative effects on the ocular surface [117]. Therefore, preservative-free drops may be a better choice for patients who have pre-existing ocular surface conditions and/or need frequent instillation of eye drops. Preservative-free eye drops have shown greater effectiveness than preserved drops in decreasing inflammation on the ocular surface and increasing the antioxidant contents in tears of patients with DED [118]. While ideally all prescribed dry eye products would be supplied in unit dose or unpreserved multi-dose bottles, cost considerations and product availability often prevent this from being possible.

Further information on preservative interactions with the ocular surface can be found in the TFOS DEWS II Iatrogenic Dry Eye Report [102].

2.1.1.1.6. Inactive agents

2.1.1.1.6.1. Buffers

The stability of commonly used ophthalmic solutions is controlled largely by the pH of their environment. In addition to stability, pH can influence comfort, safety, and activity of the product. Dry eye products contain a wide variety of buffers to control pH, including citrate, phosphate and borate buffers. The concentration of such buffers is critical, as reports exist of corneal calcification following extensive use of a dry eye product preserved with elevated levels of calcium phosphate [119].

Sodium borate, also known as sodium tetraborate or disodium tetraborate, is a salt of boric acid. Boric acid is a weak acid that is used as a buffering agent in some eye drops. Studies have shown that contact lens multipurpose solutions (MPS) containing boric acid may exhibit corneal epithelial cytotoxicity [120]. However, others have reported that MPS-induced ocular surface defects may be incorrectly attributed to boric acid [121]. The potential benefits, or otherwise, of boric acid or indeed any other buffers in dry eye formulations remain unclear. However, of note is that boric acid at ocular surface pH also acts as a cross-linking agent and electrostatically binds to hydroxypropyl guar (HP-guar) [122,123].

2.1.1.1.6.2. Excipients

Due to the delicate structure of the ocular tissues, the number of acceptable excipients for eye drops is limited, and consists mainly of ionic and non-ionic isotonic agents. There are limited published studies concerning the effect of excipients on the ocular surface [124]. Recently, macroglycerol hydroxystearate 40 (MGH 40), has been used in preservative-free eye drops as a solubilizing excipient. An animal study showed that MGH 40 is well tolerated [125]. However, a prior *in vitro* study revealed that MGH 40 triggers similar detrimental effects in cells as that seen with BAK [126]. Another study examined the role of poly(L-lysine)-graft-poly(ethylene glycol) (PLL-g-PEG) as a novel polymer excipient in artificial tears [127]. A single-center study showed that PLL-g-PEG was effective in prolonging non-invasive break up time (NIBUT) 15 min after instillation [127]. More studies are needed to clarify the impact of the various excipients on the ocular surface.

2.1.1.1.6.3. Electrolytes

The pre-corneal tear film is a complex milieu that is rich in electrolytes, including sodium, potassium, chlorine, magnesium and calcium [128]. When secreted, tears are isotonic with serum, although the proportions of ions are somewhat different, especially potassium [129,130]. In DED, the concentration of electrolytes in the tear film typically increases due to evaporation and/or reduced

aqueous production.

Electrolytes perform critical roles in ocular surface homeostasis. Observations suggest that the relatively high potassium levels in tears may play a role in protecting the corneal epithelium from UV-B radiation [131,132]. Potassium has also been shown to be necessary to maintain normal corneal thickness, and decreases in the potassium concentration may result in an increase in corneal thickness [133]. Finally, the quality of the corneal epithelial surface integrity and light scattering properties, as measured by specular microscopy, have been shown to be dependent on electrolyte composition [134]. The epithelial surface is best maintained with a buffered solution containing potassium, calcium, magnesium, phosphate, bicarbonate and sodium chloride, with potassium being particularly important [134].

Certain tear lubricants, such as TheraTears[®] (Akorn Lake Forrest, IL, USA) and Bion[®] Tears (Alcon Ft Worth, TX, USA), have an electrolyte profile that is intended to reflect that of the tear film. Some of the commonly used electrolyte salts include sodium chloride, potassium chloride, calcium chloride, magnesium chloride, zinc chloride, sodium borate, sodium phosphate and boric acid. Sodium bicarbonate is used to buffer the solution, but also has an electrolyte effect [135]. An electrolyte-based artificial tear formulation has been shown to increase conjunctival goblet cell density and corneal glycogen content in a rabbit model of DED [58,59]. Other studies have shown that the inclusion of potassium with HA in non-preserved artificial tears enhances corneal wound healing in a mechanical scraping model [33]. The addition of bicarbonate to an isotonic, non-preserved artificial tear solution promotes recovery of the corneal epithelium compared with the same solution buffered with borate or without a buffer [136]. A separate study showed that addition of bicarbonate promoted recovery of epithelial barrier function and maintained normal corneal and mucin layer ultrastructure after exposure to BAK [137]. To date, *in vitro*, animal and human studies would suggest that certain electrolyte compositions could have a positive role in the management of DED with ocular lubricants.

2.1.1.2. Lipid supplementation. The lipid layer of the tear film has an important role to play in preventing tear evaporation [138]. Lipid-containing eye drops are growing in both availability and popularity [139,140], primarily due to the increased attention being paid to MGD and lipid deficiency. A variety of oils, such as mineral oils and phospholipids, have been incorporated in ocular lubricant formulations to help restore the lipid layer of the tear film [46,141,142].

Lipid-containing drops are formulated as emulsions. Emulsions are defined as non-soluble liquids that are finely dispersed within another liquid, such as oil and water [143]. Emulsions are not readily formed and extreme shear forces and pressure must be applied with the appropriate surfactants to overcome the effects of surface tension [143].

Emulsions can be broadly categorized into three types, based upon the droplet size. Macroemulsions contain droplets larger than 100 nm (nm), nanoemulsions have droplets between 10 and 100 nm and microemulsions have droplets < 10 nm. Macroemulsions are cloudy because the large droplet sizes scatter light and these formulations can induce blur when applied topically. To minimize the potential blurring effect on vision, as well as the stability of the emulsion upon instillation, particle size, concentration and type of lipids can be manipulated. Smaller droplet sizes minimize blurring on installation because the droplet structures are smaller than visible wavelengths, which prevents scattering. A number of commercial products employ meta-stable emulsions to minimize blur time and therefore require the dispensing bottle to be inverted or shaken to enhance uniformity of the emulsion prior to application.

Emulsions have been demonstrated to effectively deliver lipophilic drugs, a task that is challenging for aqueous-based carriers. Newer approaches employ cationic submicron oil-in-water (o/w) vectors, which exploit the negative charges at the mucin layer [144]. A cationic o/w nanoemulsion is a biphasic formulation that comprises positively charged oil nanodroplets (the oil phase) dispersed in water (the continuous phase). The positive charge of the oil nanodroplets is brought about by a cationic surfactant that localizes itself at the oil interface. It is believed that when a cationic o/w nanoemulsion eye drop is instilled, the resultant electrostatic attraction between the positively charged oil nanodroplets and the negatively charged ocular surface mucins manifests itself macroscopically as an improved spreading and retention time [145]. It is possible that this interaction could be modified by exposure to cationic tear film proteins, such as lysozyme. This is of particular interest for patients with MGD who exhibit reduced tear film stability due to lipid deficiency within their tears [146].

Even in the absence of an active ingredient, these cationic o/w nanoemulsions have been observed in preclinical studies to have an inherent benefit on the ocular surface [147,148]. Cationorm® (Santen Osaka, Japan) is a preservative-free cationic emulsion indicated for the treatment of DED. The cationic excipient is cetalkonium chloride, an alkyl derivative of BAK that is lipophilic [148]. Some studies have shown that Cationorm is well tolerated by human corneal epithelial cells in culture [146,149]. However, another *in vitro* study demonstrated that corneas treated with Cationorm suffered epithelial loss and alterations to the superficial corneal stroma [150]. Cationic-based nanosystems incorporating chitosan provide alternative formulation strategies [151–153].

The long-term safety of nanoemulsions on the ocular surface remains to be evaluated.

2.1.1.2.1. Types and properties of lipids. Different types of lipids have been proposed to try to best mimic natural meibum. The types of lipids used include phospholipids, saturated and unsaturated fatty acids, and triglycerides [154]. Mineral oil in various concentrations, castor oil, olive oil, glycerin carbomers, coconut oil, soybean oil and lecithin, in combination with various emulsifying agents and surfactants, have been described [155–161].

Phospholipids can be neutral (zwitterionic), negatively (anionic) or positively (cationic) charged. Systane® Balance (Alcon Ft Worth, TX, USA) contains a polar phospholipid, DMPG (dimyristoylphosphatidylglycerol). Many types of phospholipids exist and, of these, two are commonly found in the tears - phosphatidylcholine and phosphatidylethanolamine [162–172]. It appears that anionic phospholipids have a greater ability to increase lipid layer thickness than zwitterionic compounds [46,173]. A possible reason is that negatively charged phospholipids contribute to a stable interface between non-polar lipids at the surface of the hydrophilic aqueous layer [174]. This supports a suggestion that polar phospholipids help to form a stable multi-molecular lipid film [175]. Studies suggest that lower levels of the two polar phospholipids are present in individuals with tear film deficiencies [165,176]. Further information can be obtained in the TFOS DEWS II Tear Film Report [128].

Multiple studies have shown that lipid-based drops and liposomal sprays can improve signs and symptoms of dry eye (Table 2) [65,141,142,177–182].

2.1.2. Biological tear substitutes

2.1.2.1. Autologous serum

2.1.2.1.1. Background. Serum is the fluid component of blood that remains after clotting. Although the topical use of autologous serum was described in the 1970's [183], it was only popularized for the management of severe OSD such as that associated with chemical burns, Stevens-Johnson syndrome and Sjögren syndrome

many years later [184–186]. More recently, it has also been used for several less severe conditions, including post-laser epithelial keratomileusis (LASEK), recurrent corneal erosions, late onset bleb-leaks after trabeculectomy or tissue necrosis after orbital implants [187–189].

The advantage of autologous serum is that many of its biochemical characteristics, including pH, nutrient content, vitamins, fibronectin, growth factors such as epithelial growth factor (EGF) or nerve growth factor (NGF), are similar to that of human tears. Several *in vitro* and *in vivo* studies have shown that serum and other blood derivatives enhance corneal epithelial wound healing, probably due to these factors [190–194]. Serum was also found to inhibit the release of inflammatory cytokines and to increase the number of goblet cells and mucin expression in the conjunctiva in a clinical case series [195,196]. While evidence from cell cultures suggests that proliferation of epithelial cells is enhanced by diluting the serum to 20% or less, epithelial migration and extracellular matrix deposition from fibroblasts is better stimulated by 50% or 100% serum [197,198]. In a rabbit model, undiluted serum was more effective than diluted serum in healing a corneal epithelial wound [192].

The widespread use of autologous serum is limited by a number of factors. Production of blood products is regulated by national laws, which may differ significantly between countries. The process is frequently performed by blood banks and is centralised in some countries [199–201]. Legal requirements include serological testing for human immunodeficiency virus (HIV), hepatitis and other conditions, to minimize the risk of disease transmission during production or application by others, since unknown systemic infectious diseases have been observed in more than 3% of blood products [202]. The composition of the autologous serum obtained depends on a number of production parameters, including clotting or centrifugation time, and this is likely to have an impact on the epitheliotropic effects [203]. To optimize the product and to permit comparison between studies, standardized protocols have been developed based on *in vitro* work, but these have not yet been confirmed in clinical comparative studies [204,205]. In addition to production issues, further issues exist around product storage, as the concentration of growth factors in autologous serum can reduce over time when stored at 4 °C [206]. At –20 °C the composition of autologous serum was found to be stable for up to 9 months [206–208]. Finally, the cost for autologous serum can prove to be problematic, as a 2–3 month supply can cost hundreds of dollars [205,209]. However, despite these issues, use of autologous serum in the management of severe OSD has gained widespread acceptance and thus may gain increased insurance-coverage in the future [210,211].

2.1.2.1.2. Clinical performance. In a Level 3 study, autologous serum improved symptoms of dry eye within 10 days in approximately 60% of patients and within two months in 79% of patients [212]. This effect was sustained throughout a 12-month follow-up using various symptom questionnaires.

Table 3 presents the results from 14 clinical studies (Levels 1 & 2) on the efficacy of autologous serum in DED [184,186,213–224]. In these, 349 patients received autologous serum, predominantly for severe DED due to Sjögren syndrome. Between these studies there is substantial variation for production parameters, endpoints, dosing frequency and duration of treatment. In all of the trials, with a follow-up between 1 and 3 months, subjects showed significant improvement in symptoms, with 60–80% of patients showing a positive response. Typically, TBUT, corneal fluorescein staining and conjunctival impression cytology improved, while Schirmer scores remained unaltered.

Prospective comparative cohort studies showed that autologous serum was less effective in patients who were classified, historically, with secondary compared to primary Sjögren syndrome and

Table 2
Comparative studies investigating lubricating eye drops and liposomal sprays for the management of dry eye disease.

Author, Year	N	Study period	Treatment groups	Parameters with significant improvements	Parameters without significant effect
Korb et al., 2005 [141]	40	15 min	Soothe ^a , Systane	LLT improved with both drops. (Soothe ^a 107%; Systane 16%)	None
Scaffidi & Korb, 2007 [142]	41	15 min	Refresh Dry Eye Therapy drops; Soothe ^a drops	LLT improved with both drops; Soothe ^a > increase than Refresh Dry Eye Therapy	NA
Wang et al., 2007 [177]	67	4 weeks	Carbomer-based, cellulose-based, and mineral oil-based artificial tear formulations	Total scores, symptoms, signs, and Schirmer all improved. Symptoms improved with Carbomer-based formulation.	None
Craig et al., 2010 [178]	22	30, 60, 90, 135 min	Tears Again (Optrex ActiMist) liposomal spray Control: saline spray	LLT, tear film stability, NIBUT, comfort.	TMH
Wang et al., 2010 [179]	30	4 weeks	Carbomer-based lipid-containing gel (CBLG), HP-guar gel	Schirmer and patient subjective assessment were both improved. CBLG > HP-guar. TBUT were improved equally with both	None
Pult et al., 2012 [180]	80	10 min	Optrex ActiMist (AM), DryEyesMist (DEM), TearMist (TM)	OSDI, NIBUT were both improved by AM	DEM & TM decreased comfort and NIBUT
Tomlinson et al., 2013 [65]	37	2 weeks	Carmellose sodium, carmellose sodium with lipid, glycerine with lipid drops	Evaporation, TBUT, osmolarity, symptoms. Lipid evaporation rate improved with lipid drops compared to non-lipid. Carmellose sodium with lipid was superior to others.	None
Mutalib et al., 2015 [181]	9 (rabbits)	2 weeks	Virgin coconut oil, Tears Naturale II, Saline Control: contralateral eye	None	NIBUT redness, corneal staining, pH, Schirmer
Simmons et al., 2015 [182]	256	3 months	1 marketed lipid drop, 2 non-marketed lipid drops	Symptoms, OSDI, TBUT	Corneal staining, conjunctival staining, meibomian glands, Schirmer

LLT – lipid layer thickness, N - number of subjects; NIBUT – non-invasive break up time; OSDI – ocular surface disease index; TBUT – tear break up time.

^a The Soothe formulation used in these studies is marketed today as Soothe XP.

that chronic OSD was more likely to recur after cessation of the autologous serum than acute OSD [184,186].

In a retrospective case control study (Level 2) of 16 patients with corneal neuropathy and photoallodynia (increased light sensitivity) associated with dry eye, *in vivo* confocal microscopy revealed a reduced sub-basal corneal nerve length and number [222]. Treatment with autologous serum for 3–4 months resulted in significantly decreased symptom severity and substantial improvements in a variety of nerve parameters. These findings support the positive effects reported for autologous serum in neurotrophic keratopathy in a clinical cohort of 42 subjects (Level 3) [225].

2.1.2.1.3. Complications and conclusion. Although contamination of autologous serum is frequent after extended use (30 days) of dropper bottles, complications arising from contamination are generally rare [226–228]. However, the lack of a universally accepted methodology for the preparation of autologous serum and contamination concerns have hindered regulatory approval and limited its widespread adoption by clinicians. To overcome this, 100% autologous plasma from plasmapheresis, which minimizes contamination, has been proposed [229].

In summary, autologous serum contains specific epitheliotrophic factors such as EGF, NGF, and others, in addition to a high concentration of proteins such as albumin and fibronectin. Autologous serum directly supports the proliferation and migration of epithelial cells or indirectly enhances epithelial viability by binding and neutralizing inflammatory cytokines. The majority of clinical trials and case series studying autologous serum suggest that it can be effective in the management of OSD secondary to DED, probably due to its anti-inflammatory, epitheliotrophic and neuro-trophic functions, significantly improving signs and symptoms within a few weeks. While the treatment is resource-intensive, it has few complications, but OSD can recur after cessation of treatment.

2.1.2.2. Adult allogeneic serum. Concerns have been raised

regarding the use of autologous serum when patients have active systemic inflammation, or fear of venipuncture, or in infants, the very elderly, or those with chronic anemia [230]. Allogeneic serum can be an alternative for these patients, and, as it can be prepared from previously stored blood, is quicker to produce and thus potentially more convenient. However, concerns remain in using allogeneic sources for proteins due to the theoretical risk of an immune response to foreign antigens.

Limited clinical data evaluating the role of allogeneic serum for the treatment of DED exists. In a series of 16 patients with graft versus host disease (GVHD), improvements in symptoms as measured by the OSDI, corneal fluorescein staining, TBUT, goblet cell density, and tear osmolarity were seen after treatment with 20% allogeneic serum eye drops prepared from the patient's spouse or related donors and used 6–8 times a day for 4 weeks [231]. Harritshoj and colleagues reported a series of 20 patients with DED due to GVHD, rheumatoid arthritis and other systemic immune diseases, and found that 16/20 (80%) of these patients showed improvements in objective signs and subjective symptoms of DED with 20% allogeneic serum treatment 6 times a day for 2–4 weeks [232]. These investigators used ABO specific male donors to exclude the risk of immune reactivity of ABO antibodies with ocular surface antigens. However, non-matched serum drops from mixed gender AB blood group donors have been used in New Zealand since 2007, with no reported adverse events [233]. To date, there have been no reports of significant complications associated with unmatched allogeneic serum, used topically, in the literature.

2.1.2.3. Umbilical cord serum. Umbilical cord serum has similar advantages to allogeneic serum, in that it can be prepared in large quantities (up to 250 ml) from a single donor and be used for many patients. Moreover, it is useful in patients with systemic inflammation, anemia or chronic diseases, who may not be ideal candidates for autologous serum drops. To prepare umbilical cord serum,

Table 3
Clinical studies investigating the use of autologous serum for the management of dry eye disease.

Author	Evidence level	N	Indication	Follow-up	% Serum and diluent	Controls	Improved	No improvement
Noble et al., 2004 [213]	RCT (Level 1)	16	SS & KCS	3 M	50% (0.9 NaCl)	Crossover: Lubricants	Symptoms, GCD	
Kojima et al., 2005 [214]	RCT (Level 1)	10	SS & non-SS according to Jap DEG	2 W	20% (0.9% NaCl)	AT upre	Symptoms, TBUT, CFS	Schirmer score
Noda-Tsuruya et al., 2006 [215]	RCT (Level 1)	12	LASIK	6 M	20% (0.9% NaCl)	AT	TBUT, CFS	Symptoms, Schirmer score
Yoon et al., 2007 [216]	RCT (Level 1)	41	SS, non-SS	2 M	20% (0.9 NaCl)	Umbilical cord serum	Symptoms, TBUT, CFS, GCD; Better symptoms, CFS (at 2 M)	Schirmer score, corneal sensitivity, tear clearance
Urzua et al., 2012 [217]	RCT (Level 1)	12	Severe non-SS based on DEWS criteria	2 W (cross over after 7 day washout)	20% AS	AT	Symptoms (OSDI)	Fluorescein staining, TBUT
Celebi et al., 2014 [218]	Double-masked RCT (Level 1)	20	Schirmer < 5 mm, TBUT <5s, OSDI >40, CFS ≥1	1 M	20% (0.9% NaCl)	Cross-over, Refresh upre	Symptoms, TBUT	Schirmer score, CFS
Hussain et al., 2014 [219]	Retrospective chart review	63	Any patient using AS between June 2008 and January 2013 for at least 3 months	Up to 48 M	50% (0.9% NaCl)	None	Schirmer score, OSDI, CFS	
Hwang et al., 2014 [186]	Cohort comparison (Level 2)	20	1° SS*	1 M	50%	2° SS*	1° SS*: Symptoms, CFS, TBUT	2° SS*, possibly due to increased pro-inflammatory cytokine levels
Jirsova et al., 2014 [220]	Interventional (Level 2)	17	Schirmer I < 5mm/5min; TBUT < 5 s; severe symptoms as defined in DEWS	3 M	20%	None	Schirmer score, various symptoms, CFS, Impression cytology	TBUT, TMH, dryness, discomfort
Lopez-Garcia et al., 2014 [221]	RCT (Level 1)	26	SS	2 M	20% (0.9 NaCl)	AS 20% diluted with HA in contralateral eye	Symptoms, TBUT, CFS, GCD improved in both, but better in HA-AS	Schirmer score, VA
Semeraro et al., 2014 [184]	Cohort comparison (Level 2)	26	Acute OSD (Dry eye, neurotrophic keratitis, Recurrent erosion)	16–31 W	50% (0.9% NaCl)	Chronic OSD	Epithelial defects all healed	18% recurrence in chronic OSD after cessation of AS
Aggarwal et al., 2015 [222]	Interventional (Level 2)	16	Photoallodynia (excluded those with OSD)	3 M	20% AS	None	Subbasal corneal nerve density & morphology, symptoms of photophobia	GCD density
Li et al., 2015 [223]	RCT (Level 1)	18	SS Schirmer <5 mm, TBUT <5s, CFS >5	6 W	50% (0.9 BSS)	Silicone hydrogel contact lens	Symptoms, TBUT, CFS, but symptoms and CFS better in control	Schirmer score, BCVA
Mukhopadhyay et al., 2015 [224]	RCT (Level 1)	52	Schirmer < 5 mm	18 W - 6 on and 12 off treatment)	20% (0.9% NaCl)	(1) AT (2) cord blood serum	Symptoms, TBUT, CFS	Schirmer score

1°/2° - primary/secondary (*historical classification); 2 M - 2 months; AS - autologous serum; AT - Artificial tears; CFS - corneal fluorescein staining; CL - contact lens; GCD - Goblet cell density; GVHD - Graft versus host disease; HA - Hyaluronic acid; KCS - keratoconjunctivitis sicca; Jap DEG - Japanese Dry Eye Group; LASIK - laser in-situ keratomileusis; M - Months; N - number of subjects treated with serum; NaCl - saline; OSD - Ocular surface disease; OSDI - ocular surface disease index; Oxford - punctate epitheliopathy score; RCT - Randomized controlled trial; s - seconds; SS - Sjögren syndrome; TBUT - tear breakup time; upre - unpreserved; VA - visual acuity; W - Weeks.

umbilical cord blood is taken from the umbilical cord vein after delivery. After centrifugation, the serum is diluted to a 20% concentration and administered 4–6 times per day [234].

Umbilical cord serum has a higher concentration of tear components such as EGF, NGF and transforming growth factor (TGF)- β compared to peripheral blood serum [235]. Symptom scores, TBUT, corneal fluorescein staining and impression cytology findings have been shown to improve significantly after application of umbilical cord serum eye drops in patients with DED resistant to conventional treatment [235] and in ocular GVHD [236]. Comparison of umbilical cord serum with autologous serum administered 6–10 times a day showed that although both serum drops resulted in improvement, umbilical cord serum resulted in lower symptom and corneal fluorescein staining scores in severe DED and higher goblet cell density in Sjögren syndrome than did autologous serum [216], thought to be due to a higher concentration of growth factors and cytokines.

2.1.2.4. Platelet preparations. Platelets are a reservoir of biologically active growth factors. Hartwig and colleagues initially suggested the potential use of platelet preparations to treat ocular surface disorders [193,194]. Liu et al. compared the growth factor content of fresh frozen plasma and platelet releasate to that of serum and evaluated their effects on proliferation, migration and differentiation of corneal epithelial cells, in an *in vitro* system [237]. They found that the growth factor content was higher in platelet releasate than plasma or serum, with better cell proliferation, but that serum had better cellular migration and differentiation owing to its higher content of fibronectin and vitamins.

There are many different platelet preparations used in clinical studies, including platelet-rich plasma, plasma rich in growth factors and platelet lysate. These preparations differ widely in their method of processing [193,194,237–241].

In a prospective study, Alio and associates reported that the use of platelet-rich plasma 4–6 times a day in 18 patients with DED led to an improvement in symptoms in 89% and reduced corneal staining in 72% of patients after 1 month [242]. Plasma rich in growth factors, administered 4 times a day to 16 patients with DED, was found to be effective in reducing symptoms in 75% of patients after 3 months of treatment [243]. Platelet lysate (30%) applied 4 times a day was effective in a series of 23 patients with refractory GVHD, with improvement in corneal fluorescein staining in 70% of patients after 6 months of use [244]. Platelet Rich Plasma improves symptoms and signs of DED after laser in-situ keratomileusis (LASIK) [242]. However, the preparation is more complex and the beneficial effects and indications of using platelet-derived products over serum in the management of DED have not been addressed in the literature.

2.1.3. Other agents

2.1.3.1. Mucolytics. Mucolytics are a group of substances that depolymerize mucin and include ambroxol (Mucosolvan® Boehringer Ingelheim, Ingelheim am Rhein, Germany) and bromhexine that are used in the management of lung complaints that result in excess mucous production. A small clinical trial in subjects with Sjögren syndrome demonstrated that oral ambroxol improved dryness symptoms [245]. Another mucolytic eye drop, acetylcysteine, which also has antioxidant properties [246], has been reported to have a better effect in reducing subjective symptoms of DED than artificial tears, but had no effect on the objective signs [247]. In addition, mucolytics can be used for palliative treatment of filamentary keratitis, which is a potential complication of DED [248].

2.1.3.2. TRPV1 receptor antagonist. A transient receptor potential vanilloid type 1 (TRPV1) channel has been found in ocular surface tissue, which can be activated by hypertonicity to induce pain and

inflammation [249,250]. Topical administration of SYL1001, a short interfering (si) RNA targeting TRPV1 (at a dose of 1.125% once a day), produced a significant decrease in symptom scores in subjects with DED compared with placebo [251]. Selective inhibition of the production of the TRPV1 receptor may reduce dry eye symptoms and may provide a novel therapeutic opportunity for the relief of dry eye, but further research is necessary to investigate this hypothesis.

2.2. Tear conservation approaches

2.2.1. Punctal occlusion

The concept of temporary or permanent occlusion of one or both puncta is to retain tears on the ocular surface by blocking their drainage.

2.2.1.1. Indications and contraindications. Any condition that would benefit from aqueous retention on the ocular surface is a reasonable indication for either unilateral [252], or bilateral, punctal occlusion [253]. These conditions include symptomatic contact lens wear [254,255], dry eye related to refractive surgery [256–258], ADDE secondary to a variety of systemic diseases (including Sjögren syndrome, GVHD, autoimmune diseases) [259,260], dry eye associated with a rapid TBUT [252], systemic medications that reduce tear film production, superior limbic keratoconjunctivitis [261], any corneal irregularities or scarring that affect tear stability, lid palsy or lid closure abnormalities, and toxic epitheliopathy [262].

The use of punctal occlusion in the presence of ocular surface inflammation is controversial, because theoretically occlusion of tear outflow could prolong the presence of pro-inflammatory cytokines on the ocular surface and treatment of the inflammation prior to occlusion is therefore recommended. However, a recent study showed that punctal occlusion in 29 individuals with moderate DED for 3 weeks resulted in reduced corneal fluorescein staining and symptom scores, without elevation of cytokine or matrix metalloproteinase (MMP)-9 levels, questioning whether cytokine levels would necessarily elevate with punctal occlusion over short periods of use [263].

2.2.1.2. Punctal occlusion with plugs. Punctal occlusion is most commonly undertaken using punctal plugs. The plug can be located at the level of the punctal opening or deeper within the canaliculus. While it is relatively simple to understand the rationale for using punctal plugs for ADDE, its use in the management of EDE remains controversial and the results are equivocal as to its effectiveness in improving meibomian gland status and lipid layer instability [264–267].

2.2.1.2.1. Types of devices. Punctal plugs are differentiated into absorbable and non-absorbable devices.

Absorbable devices are temporary inserts that are typically used as “test” devices to determine the efficacy of occlusion, prior to permanent occlusion being undertaken. Collagen-based plugs, which absorb in one to 16 weeks, are the most commonly used [253,268,269]. Atelocollagen is a collagen solution that is extracted from animal dermal tissue, from which antigenic telopeptides attached to both ends of the collagen molecule are eliminated by pepsin treatment [270]. At temperatures of 4 °C or under, atelocollagen dissolves in a neutral phosphate buffer solution. If this solution is injected through the punctum, it turns into a white-colored gel at body temperature. The injectable atelocollagen plug has proven successful in a variety of studies [270–272]. Succinylated collagen plugs [273], and hypromellose 2% [274], may be promising alternatives for temporary punctal occlusion.

Non-absorbable or “permanent” plugs are often silicone-based and exist in a wide variety of designs. The Freeman style plug

consists of a surface collar resting on the punctal opening, a neck, and a wide base, while the Herrick plug is a cone-shaped intracanalicular silicone plug [275]. Some silicone plugs have an interior channel for partial occlusion, which might permit limited drainage. The cylindrical SmartPlug™ is an intracanalicular plug made from a thermolabile polymer that changes size and shape when inserted into the punctum [276–279]. The FORM FIT® (Oasis Medical, Glendora, CA, USA) intracanalicular plug is made from an injectable hydrogel that hydrates *in situ* over a 10 min period and expands to conform to the shape of the canaliculus [280], removing the requirement for selecting a plug of the appropriate size. The plug is supplied on a pre-loaded inserter that dispenses the plug from within a polyamide sheath.

In addition to devices, certain types of cyanoacrylate adhesives can be used for temporary punctal occlusion, prior to determining if longer-term occlusion is warranted [281,282]. For permanent occlusion, there are a variety of surgical options that can be used, as described in section 2.2.1.3.

2.2.1.2.2. Complications. The most common complication of punctal occlusion is spontaneous plug extrusion [265,283–286], which may occur in as many as 60% of cases [287–289]. Other reported complications include infection [290–292], canalicular migration of the plug [286,290], pyogenic granuloma, punctal enlargement [286], and, rarely, tumors [293]. Infections (such as keratitis, conjunctivitis, canaliculitis or dacryocystitis) occur more commonly with intracanalicular devices [291,294]. Other less serious complications, frequently due to the mechanical presence of the device, include conjunctivitis, subconjunctival hemorrhage, chemosis, epiphora, punctal erythema, discomfort and foreign body sensation [294].

2.2.1.3. Surgical punctal occlusion. Permanent surgical closure of the punctum is typically reserved for patients who are unable to retain or tolerate punctal plugs. A wide variety of surgical methods exist [281], including total or partial thermal cauterization [295–298], punctal occlusion with a conjunctival flap [299] or graft [300], punctal plug suturing [301], total destruction (extirpation) of the canaliculus [302], and canalicular ligation [303]. The thermal methods include cautery, diathermy and use of an Argon laser, and these may be performed deep within the canaliculus or superficially on the external portion of the puncta [259,297,298]. Today, disposable, hand-held thermal cautery is the most widely used method in clinical practice.

There are currently no Level 1 studies and only a limited number of Level 2 reports regarding the efficacy of surgical closure of the puncta for treating DED. Comparative case series have demonstrated that permanent closure of the puncta by cauterization significantly improves symptoms, Schirmer scores, corneal fluorescein staining, rose bengal scores and TBUT in patients with GVHD and Stevens-Johnson syndrome [259,304].

Very few complications are reported with cauterization. Epiphora can be a potential problem if both the upper and lower puncta are totally and permanently closed. To avoid this, incomplete occlusion of the puncta can be achieved with thermal cautery. In patients with Sjögren syndrome, this partial occlusion technique has resulted in improved symptoms, TBUT, conjunctival staining and corneal fluorescein staining [298]. Recanalization can occur, depending on the technique used and the inflammatory response that occurs, and in such cases a repeat procedure is necessary to completely close the punctum [297]. It appears that techniques involving superficial cauterization have a higher rate of recanalization [305], and that deeper surgical procedures may increase the success rate [296].

2.2.1.4. Punctal occlusion summary. Punctal occlusion may be most successful when combined with other DED treatments [306]. A

systematic review of punctal occlusion for DED was conducted by Ervin et al., which included 7 studies with 305 subjects [307]. The author's conclusion was that, although punctal plugs provided symptomatic improvement and clinical outcomes improved from baseline measures, few studies demonstrated a benefit of punctal plugs over a comparison intervention. Further, these authors stated that although the evidence is very limited, the data suggest that silicone plugs can provide symptomatic relief in severe dry eye and that temporary collagen plugs appear similarly effective to silicone plugs on a short-term basis [307].

To date, there are no large scale, Level 1 studies to support the contention that punctal occlusion of any form is effective in the management of DED. However, 14 supportive Level 2 studies are listed in Table 4 [252,257,263,270,272,274,283,308–313].

2.2.2. Moisture chamber spectacles and humidifiers

Moisture chamber spectacles are eyeglasses specially designed to slow evaporation of the tears, by providing a humid environment and minimizing airflow over the ocular surface. A number of such devices are available. While the clinical efficacy of moisture chamber spectacles has been reported in case reports [314,315], to date, no high level studies have investigated the therapeutic value of these devices, but it does appear that they can prove to be a potential adjunct to prescribed treatment, especially in adverse environments [316].

Locally placed humidifying devices have also been proposed to enhance humidity or local air quality. However, only one controlled study lends support to their effectiveness in the management of dry eye thus far [317].

2.3. Tear stimulation approaches

Several topical pharmacologic agents that stimulate aqueous, mucin and/or lipid secretion are commercially available in certain markets, or under development.

2.3.1. Topical secretagogues

2.3.1.1. Aqueous secretagogues. Diquafosol tetrasodium (Diquas®; Santen, Osaka, Japan) is approved as an ophthalmic solution at 3% concentration in Japan and South Korea for the treatment of dry eye. It is a purinergic P2Y2 receptor agonist that stimulates water and mucin secretion from conjunctival epithelial cells and goblet cells, leading to improved tear film stability in dry eye [14,318,319]. Several randomized controlled trials have demonstrated that the application of topical diquafosol significantly improves objective markers of DED, such as corneal and conjunctival fluorescein staining and, in some studies, TBUT and Schirmer scores [38,320,321]. Diquafosol has potential utility in various specific dry eye disorders, including Sjögren syndrome [322], ADDE [323], short TBUT dry eye [324], MGD [325], dry eye following LASIK [326], and cataract surgery [327], as well as in contact lens wearers [325]. Recently, Byun et al. demonstrated that diquafosol is effective in promoting corneal epithelial wound healing and that this effect may result from epidermal growth factor receptor/extracellular-signal-regulated kinase stimulated cell proliferation and migration via P2Y2 receptor mediated intracellular calcium elevation [328]. In studies in the USA, 2% diquafosol tetrasodium did not achieve its primary and secondary endpoints and failed to achieve FDA approval [329].

Lacritin is a glycoprotein that has prosecretory activity in the lacrimal gland and mitogenic activity at the corneal epithelium and is reduced in the tears of patients with Sjögren syndrome [330], and other forms of dry eye [128]. Topically administered lacritin has therapeutic potential for the treatment of ADDE [331].

Table 4
Level 2 studies of punctal occlusion in dry eye disease.

Author	Subject group	N	Treatment duration (months)	Reported benefits	Comments
Balaram et al., 2001 [283]	Dry eye with plug	50	6	Improved symptoms	37% plug loss; more likely to lose plugs inserted in upper puncta
Kojima et al., 2002 [308]	Dry eye with silicone plug	51	21	Improved symptoms, epithelial damage	55.9% plug loss
Nava-Castaneda et al., 2003 [309]	Dry eye with collagen and silicone plug	61	2	Improved symptoms, vital staining	
Farrell et al., 2003 [310]	Dry eye with collagen plug	62	0.3	Improved symptoms, tear function	Benefit of occluding only lower puncta
Altan-Yaycioglu et al., 2005 [311]	Dry eye with collagen and silicone plug	24		Improved tear function	Similar results with both types
Miyata et al., 2006 [272]	Dry eye with atelocollagen plug	28	2	Improved tear function, vital staining, TBUT, Schirmer score	
Chen et al., 2007 [312]	Dry eye with Smart plug	54	13	Improved symptoms, vital staining	
Hirai et al., 2012 [270]	Dry eye with atelocollagen plug	37	2	Improved symptoms, ocular surface status	
Yung et al., 2012 [257]	Dry eye post-LASIK with plug	18	3	Improved symptoms, tear function	
Kaido et al., 2012 [252]	Short TBUT patients with plug	43	1	Improved symptoms, tear function, vital staining	
Shi et al., 2013 [313]	Dry eye with silicone plug	65	6	Improved symptoms, corneal staining, TBUT and Schirmer score	
Capita et al., 2015 [274]	Dry eye SS with hypromellose occlusion	38	2	Improved symptoms, corneal staining and Schirmer score	
Tong et al., 2016 [263]	Moderate dry eye with punctal plug	29	0.75	Improved symptoms, corneal staining	No changes in tear cytokines

LASIK - laser in-situ keratomileusis; N - number of subjects; SS - Sjögren syndrome; TBUT - tear break up time.

2.3.1.2. Mucin secretagogues. There are a number of drugs that specifically target mucin deficiency in DED, including diquafosol tetrasodium (see section 2.3.1.1).

Rebamipide ophthalmic suspension (Mucosta[®]; Otsuka Pharmaceutical, Chiyoda, Japan) is currently approved in Japan for the treatment of dry eye. It is a mucin secretagogue that promotes the production of mucin-like glycoproteins in human corneal epithelial cells, increasing MUC1, MUC4 and MUC16 expression levels through signals involved in epidermal growth factor receptor activation [14,332]. In a multicenter, open-label, single-arm study, a total of 154 patients received 2% rebamipide four times per day for 52 weeks [333]. Lissamine green conjunctival staining, corneal fluorescein staining, TBUT and subjective symptoms improved significantly at week 2 compared with baseline, and further improvements were observed at every visit up to week 52. Topical rebamipide is also potentially effective in treating other ocular surface disorders such as short TBUT dry eye [334], lid wiper epitheliopathy [335], and alkali ocular damage [336,337]. Rebamipide has also proven to be effective at improving the ocular surface appearance and optical quality in patients with dry eye undergoing refractive surgery [338]. Although approved in Japan, phase III trials for rebamipide in the USA failed to provide the data necessary for FDA approval [329].

Galectin-3, a member of the lectin family, is a carbohydrate-binding protein that controls multiple biological processes within the epithelium of the ocular surface. It has been shown that individuals with DED have a higher concentration of galectin-3 protein in their tears compared with normals and it was concluded that the release of cellular galectin-3 into tears was associated with the development of epithelial damage [339]. The placental extract-derived dipeptide (JBP485), a dipeptide that promotes galectin-3 production, promotes the expression and secretion of the gel-forming mucin 5AC (MUC5AC) in rabbit conjunctival epithelium [340]. JBP485 has also been shown to elevate the expression of membrane-bound mucins (MUC1/4/16) in rabbit corneal epithelium. JBP485 induced tear secretion in the rabbit model and

resulted in reduced corneal epithelial damage in a mouse dry eye model. Thus, JBP485 promoted both mucin and aqueous tear secretion improvements in animal models [340].

Mycophenolate mofetil (MMF) is a lymphocyte inhibitor commonly used in the treatment of autoimmune diseases and transplant rejection. It has been reported that a low concentration of MMF can promote human conjunctival goblet cell proliferation, and increase messenger RNA (mRNA) production of MUC5AC *in vitro* [341], but clinical studies are yet to be undertaken.

Eupatilin is a type of flavonoid. It has potent effects on inducing secretion of mucins in conjunctival cells, in both *in vitro* and *in vivo* studies, suggesting that it might have potential as a future treatment for DED [342,343].

Trefoil factors are secretory products of mucin-secreting cells. It has been found that the levels of Trefoil factor family peptide 3 (TFF3) are elevated in the tears of patients with DED. In an *in vitro* study, some proinflammatory cytokines, but not hyperosmolarity, were shown to also induce the production of TFF3, suggesting that TFF3 could be a potential target for the treatment of DED [344,345].

NGF regulates the growth, proliferation and maintenance of certain neurons. In an *in vitro* study, NGF was shown to stimulate conjunctival epithelial cell differentiation and mucin production [346].

2.3.2. Lipid stimulation

Insulin-like growth factor 1 (IGF-1) has lipid-stimulating effects on meibomian gland cells *in vitro* [347]. Androgens have been found to upregulate genes involved in lipid metabolic pathways, and downregulate those related to keratinization, in human meibomian gland epithelial cells in a number of laboratory-based studies [348–351]. Phase 2 clinical trial results show that treatment of patients with MGD with topical testosterone improves the quality of meibomian gland secretions and reduces ocular discomfort [352]. Additional clinical trials for the treatment of MGD with topical testosterone are currently underway in Europe.

More details on the impact of androgens and IGF-1 can be found

in the TFOS DEWS II Sex, Gender, and Hormones Report [353].

2.3.3. Oral secretagogues

Two orally administered cholinergic agonists, pilocarpine and cevimeline, are commercially available for the treatment of Sjögren syndrome-associated DED. People with Sjögren syndrome have autoantibodies that bind to muscarinic acetylcholine receptors in the exocrine glands and pilocarpine and cevimeline are muscarinic acetylcholine receptor agonists (parasympathomimetics) that aim to overcome this effect.

People with Sjögren syndrome treated with oral pilocarpine for 12 weeks experienced a beneficial effect on symptoms and reduction in rose bengal staining, but an increase in tear production was not substantiated [354]. Other studies have shown an improvement in symptoms, corneal fluorescein staining, rose bengal staining, goblet cell density and TBUT, but again no improvement in tear production was shown by Schirmer testing [355,356]. However, oral pilocarpine was able to increase tear meniscus height (TMH) in people with Sjögren syndrome [357]. The most commonly reported side effect from this medication was excessive sweating, which occurred in up to 25% of patients [358].

Petrone et al. evaluated the safety and efficacy of 2 doses of cevimeline for the treatment of xerostomia and dry eye in patients with Sjögren syndrome in a 12-week double-masked, randomized, placebo-controlled study [359]. Patients taking cevimeline three times per day had significant improvements in subjective assessment of ocular dryness, dry mouth, and increased salivary and lacrimal flow rates [359]. Frequently reported adverse events included headache, increased sweating, abdominal pain, and nausea [359,360].

The efficacy of oral secretagogues seems to be greater in the treatment of oral dryness than ocular dryness [361,362]. Patients with Sjögren syndrome have been found to be more likely to continue cevimeline than pilocarpine on a long-term basis due to fewer reported side effects with cevimeline. Therapeutic failure of one secretagogue did not predict similar results with the other, with second time users more likely to continue long-term treatment [358].

2.3.4. Nasal neurostimulation

Neuromodulation is a therapeutic strategy that involves interfacing directly with the nervous system through electrical, electromagnetic, chemical, or optogenetic methodologies [363,364]. The goal is the long-term activation, inhibition, modification, and/or regulation of neural input to correct organ or tissue dysfunction and manage disease symptoms. The nasolacrimal reflex upregulates tear production following chemical or mechanical stimulation of the nasal mucosa [365,366]. The nasolacrimal reflex arc begins in the sensory nerves lining the nasal cavity (the afferent arm) and terminates with the parasympathetic innervation of key target tissues that contribute to tear production (the efferent arm) [367]. In a prospective, case-control study in patients with normal tear production, anesthetizing the nasal mucosa was shown to reduce basal tearing by 34% compared with a saline control [368].

An intranasal tear neurostimulator has been developed to induce normal tear production via stimulation of the nasolacrimal reflex. This device consists of a hand-held stimulator unit equipped with a disposable two-pronged hydrogel tip and an external charger. The intranasal tear neurostimulator allows self-delivery of minute electrical currents to the anterior ethmoidal nerve, thereby stimulating immediate natural tear production in patients with DED [366]. Forty subjects with mild-to-severe DED used a prototype intranasal tear neurostimulator in an open-label, single-arm, non-randomized, 180-day pilot study [369]. Subjects were instructed to perform stimulation with the device 2 times per day or more, as needed. At day 180, stimulation with the device

significantly increased mean Schirmer scores compared to unstimulated basal tear production scores. At the end of the follow-up period, mean conjunctival staining and symptom scores were significantly reduced from baseline. Preliminary results have also shown a positive effect of the neurostimulator on goblet cell function [370].

The TrueTear™ Intranasal Tear Neurostimulator (Allergan, Parkway Parsippany, NJ, USA) was recently cleared by the FDA with an approved indication for providing a temporary increase in tear production during neurostimulation in adult patients. A number of other studies are ongoing and results are awaiting publication [371,372].

2.3.5. Various tear stimulation methods

A variety of other novel methods to stimulate tear production have been reported. These include abdominal breathing for 3 min, which reportedly increased the tear meniscus volume in healthy women [373].

Corneal cold thermoreceptors are activated by drying of the ocular surface and stimulation of these receptors could increase tear production [374,375]. The existence of Transient Receptor Potential Cation Channel, Subfamily M, Member 8 (TRPM8) on the nerve terminals of the cold thermoreceptors on the cornea is consistent with the finding that their stimulation by menthol and cool temperatures could increase tear production [376,377]. Finally, caffeine, probably the most widely consumed psychoactive substance, appears to stimulate tear secretion in healthy, non-dry eye subjects [378].

3. Treatments for lid abnormalities

3.1. Anterior blepharitis

3.1.1. Lid hygiene

Appropriate lid hygiene is important in the management of a variety of lid conditions that result in dry eye (particularly blepharitis) and, if used appropriately, can reduce lipid by-products and lipolytic bacteria associated with these conditions [379–385]. Lid scrubs using a mild dilution of baby shampoo applied with a swab or cotton bud have been the most widely accepted therapy [382,386,387]. A recent Level 1 study demonstrated the efficacy of lid scrubs for removal of crusting in anterior blepharitis, with both a commercial lid cleanser and dilute baby shampoo [388]. However, relative to the baby shampoo, the dedicated lid cleanser showed reduced ocular surface MMP-9 levels, improved lipid layer quality and was better tolerated. Baby shampoo was further reported to be associated with a reduction in ocular surface MUC5AC levels, suggesting that baby shampoo may have an adverse effect on goblet cell function [388]. In preference to using baby shampoo, there are now a wide variety of proprietary lid cleansing products available, which utilise a diversity of delivery mechanisms, including scrubs, foams, solutions, and wipes; their individual description is outside the scope of this review.

The report of the TFOS MGD Workshop reported that “lid hygiene is widely considered an effective mainstream therapy for MGD and blepharitis” [389]. However, compliance with following lid hygiene instruction is notoriously poor. A recent cross-sectional study of 207 subjects who were prescribed lid hygiene procedures (daily warm compresses and eyelid scrubs) found that only 55% were compliant after 6 weeks of use [390].

Despite the fact that various professional organisations suggest ways to clean the eyelids, to date, there are no universally accepted guidelines for lid cleansing and peer-reviewed evidence for such advice is lacking, suggesting that this is an area worthy of study. Caution should be exercised when cleaning lids that have make-up

on them, to avoid subsequent contamination of the ocular surface [391–393].

Table 5 reports Level 2 studies related to lid cleansing methods and their impact on blepharitis or dry eye (combinations with other pharmacological treatments are not included) [386,387,394–400].

3.1.1.1. Bacterial overcolonisation

3.1.1.1.1. *Topical antibiotics.* Lid hygiene to reduce the bacterial load on the lid margin is commonly undertaken in the management of DED associated with blepharitis [401]. However, achieving this through prescribing topical antibiotic drops or ointment (such as fusidic acid) alone is not commonly recommended over the longer term, but is adopted by some practitioners [402] and a short dose of a topical antibiotic has been recommended in consensus-based reports [403]. A recent Level 2 study demonstrated that an ofloxacin-based ointment was valuable in the management of patients with obstructive MGD. Topical azithromycin (a macrolide antibiotic) has been used in the management of DED, but it is believed to have an anti-inflammatory action rather than simply reducing the bacteria lid flora (see Section 4.5). More Level 1 studies are required to examine the potential for prescribing topical antibiotics alone in managing DED.

3.1.1.2. *Demodex infestation.* Demodex infestation is a causative factor in many cases of intractable blepharitis and is often associated with dry eye symptoms [404], although there is currently no evidence to show a direct association with the development of MGD [389]. Historically, the treatment of ocular Demodex included a wide variety of products, most of which had no high level evidence to support their use. These included topical 2% metronidazole gel [405,406], 1% mercury oxide ointment [407], and 4% pilocarpine gel [408]. More recently, appropriate management has been found with the use of topical products containing tea-tree oil or oral ivermectin, as summarized in Table 6 [409–415].

3.1.1.2.1. *Tea tree oil.* Tea tree oil (TTO) is a natural, essential oil from steamed *Melaleuca alternifolia* leaves (from the narrow-leaved Paperbark or Tea tree, which is native to Australia) that exhibits antimicrobial, anti-inflammatory, antifungal, and antiviral properties [416], and is toxic to Demodex [417]. In a Level 2 clinical study, a weekly lid scrub with 50% TTO accompanied by a daily lid scrub with tea tree shampoo was more effective at eradicating ocular Demodex than a daily lid scrub with a 50% concentration of baby

shampoo [417]. However, TTO can be toxic to the eye and causes ocular stinging and irritation if used in its pure form. The active component of TTO is 4-Terpineol [418,419], and pre-formulated wipes are now commercially available that are equivalent to 25% whole TTO. These reduce the risk of toxicity to the ocular surface compared with using stronger concentrations of TTO. Several studies have shown a considerable reduction in the number of Demodex on the eyelashes after treatment with TTO [409,410,413,414,417].

To date, very limited information exists in relation to the positive impact of TTO on dry eye symptoms and signs [420], and more studies are needed on this topic.

3.1.1.2.2. *Ivermectin.* Ivermectin is a broad-spectrum antiparasitic drug primarily used to treat strongyloidiasis and control onchocerciasis. It is a low cost, single dose medication that is very well tolerated by patients. One oral dose of ivermectin has been shown to successfully reduce the number of Demodex found adjacent to the lashes of patients with blepharitis [411,412]. Performance has been improved by combining the use of ivermectin with metronidazole [415], or with permethrin cream [421]. More studies are needed to confirm the role of ivermectin for treating DED symptoms and signs.

3.2. Meibomian gland dysfunction

The 2011 definition of MGD by the TFOS MGD Workshop highlighted the importance of terminal duct obstruction in MGD [2], which has encouraged the use of treatments to remove obstruction from the terminal duct and ductal system of the meibomian glands. Thus, there exists a significant role for conventional treatments in the management of MGD, including ocular lubricants, lid hygiene and warm compresses.

3.2.1. Ocular lubricants

As MGD results in decreased lipid layer thickness, it may be beneficial to replace the lipids with ocular lubricant eye drops or sprays that contain lipids. A number of studies have found an improvement in signs and symptoms with the use of lipid-based drops in dry eye (Table 7) [65,141,142,157,182,422–427]. A Level 1 study has confirmed increased lipid layer thickness grade and NIBUT in normal eyes treated with a liposomal spray [178]. To enhance the potential performance of lipid-based drops, nano-

Table 5
Level 2 studies of lid hygiene in dry eye disease.

Author	Subject group	N	Lid hygiene variations	Treatment duration (months)	Reported benefits
Paugh et al., 1990 [394]	MGD	21	Lid scrub + massage	0.5	Improved TBUT
Key et al., 1996 [386]	Chronic blepharitis (80% wore CL)	25	Lid scrub vs hypo-allergenic bar soap	4	Improved symptoms and lid appearance
Romero et al., 2004 [387]	MGD	37	Lid hygiene + heated saline + AT	1.5	Improved symptoms and TBUT
Guillon et al., 2012 [395]	Blepharitis and MGD	40	Lid hygiene with wipes (Blephaclean)	3	Improved eyelid margin status
Guillon et al., 2012 [396]	Blepharitis and MGD	40	Lid hygiene with wipes (Blephaclean)	3	Improved symptoms
Doan et al., 2012 [397]	Chronic blepharitis	33	Lid hygiene with cleansing solution (Blephagel)	0.75	No changes in TBUT and VA; routine was well tolerated
Khairuddin et al., 2013 [398]	Chronic blepharitis and contact lens wear	53	Lid hygiene (baby shampoo)	1	Improved symptoms
Arrua et al., 2015 [399]	Chronic blepharitis	45	Lid hygiene neutral shampoo	2	Improved symptoms and signs
Ngo et al., 2017 [400]	DED	20	Combination of AT, lid cleanser (TheraTears SteriLid) and oral omega-3 supplements (TheraTears Nutrition)	3	Improved symptoms and signs

AT – artificial tears; CL – contact lens; MGD – meibomian gland dysfunction; N - number of subjects; TBUT – tear breakup time; VA – visual acuity.

Table 6
Level 2 studies related to management of Demodex and dry eye disease.

Author	Subject group	N	Treatment variations	Treatment duration (months)	Reported benefits
Kheirkhah et al., 2007 [409]	Chronic blepharitis with ocular Demodex	6	TTO 50% weekly lid scrub + daily TT shampoo	2	Reduced Demodex count, improved ocular irritation and inflammatory corneal signs
Gao et al., 2007 [410]	Ocular Demodex	11	TTO 50% weekly lid scrub + daily TT shampoo	1	Reduced Demodex count
Holzchuh et al., 2011 [411]	Refractory blepharitis with ocular Demodex	12	Oral ivermectin	1	Reduced Demodex count, improved tear functions
Filho et al., 2011 [412]	Chronic blepharitis with ocular Demodex	19	Oral ivermectin	3	Reduced Demodex count
Koo et al., 2012 [413]	Ocular Demodex	106	TTO daily lid scrub	1	Reduced Demodex count, improved ocular comfort
Gao et al., 2012 [414]	Ocular Demodex	24	TTO 5% ointment massage	1	Reduced Demodex count, improved ocular itching
Salem et al., 2013 [415]	Ocular/skin Demodex	30	Oral ivermectin vs ivermectin + metronidazole	1	Reduced Demodex count

N - number of subjects; TT - tea tree; TTO - tea tree oil.

technology concepts have been incorporated into lipid emulsion eye drops [147,428].

3.2.2. Warm compresses

Despite the proven efficacy of warm compresses in many clinical studies, compliance is often poor due to the time required and the difficulty in maintaining the temperature of the compress for an extended period of time [389,390,429–432]. One method to extend the length of time over which a facecloth can retain heat is to wrap

several cloths around each other in a bundle format [433].

The ability for heat from a warm compress to soften or liquefy the secretions in obstructed glands in the case of MGD is supported by Level 2 and 3 evidence [433–436]. The temperature and time required for melting obstructive material within the meibomian gland excretory duct has not been definitively established. Preliminary evidence from multiple studies has reported a range of melting points (32°–45 °C) for the contents of the meibomian glands, reflecting in part that meibum is a highly complex lipid

Table 7
Studies of lipid-containing eye drops in dry eye disease.

Author	Evidence Level	Patient group	N	Treatment duration	Reported benefits	Comments
Korb et al., 2005 [141]	2	Mild to severe DED	40	Single drop of each type	Increased LLT emulsion > aqueous drop	Test 1 = oil-in-water emulsion, Test 2 = aqueous eye drop
Scaffidi et al., 2007 [142]	2	Mild to severe DED	41	Single drop of each type	Increased LLT	Test 1 and 2 = two oil-in-water emulsions
Maissa et al., 2010 [157]	3	10 DED, 5 normals	15	Single drop	Improved symptoms, castor oil detected up to 4 h post eye drop instillation	Test = oil-in-water emulsion
McCann et al., 2012 [422]	1	Mild to moderate EDE	75	90 days	Improved symptoms, evaporation, increased lipid layer and TBUT emulsion > sodium hyaluronate, decreased corneal staining and osmolarity with emulsion	Test 1 = aqueous drop with sodium hyaluronate, Test 2 = aqueous drop with HPMC, Test 3 = oil-in-water emulsion
Tomlinson et al., 2013 [65]	1	Mild to moderate DED, age and sex-matched controls	38	2 weeks	Improved OSDI, evaporimetry, TBUT, osmolarity	Test 1 = aqueous eye drop, Test 2 and 3 = two oil-in-water emulsions
Sindt et al., 2013 [423]	2	Mild to moderate MGD	49	4 weeks	Improved symptoms, corneal staining, TBUT, meibomian expression	Test = oil-in-water emulsion
Aguilar et al., 2014 [424]	1	Mild to moderate EDE	49	4 weeks	Improved TBUT, corneal staining, conjunctival staining, meibomian expression	Test = oil-in-water emulsion, control = sodium chloride
Kaercher et al., 2014 [425]	3	Mild to severe ADDE, EDE and mixed DED	1209	4 weeks	Improved symptoms, OSDI, TBUT, Schirmer score, decrease in severity of dry eye	Test = oil-in-water emulsion
Guthrie et al., 2015 [426]	1	Symptomatic contact lens wearers	106	1 month	Improved comfort, wearing time, lid wiper epitheliopathy, corneal staining emulsion > control drops	Test = oil-in-water emulsion, control = non-lipid containing contact lens drops
Simmons et al., 2015 [182]	1	Mild to moderate DED (2 with SS)	288	3 months	Improved subjective dryness symptoms, OSDI, TBUT	Test 1, 2, 3 = three oil-in-water emulsions
Ousler et al., 2015 [427]	2	Moderate to severe DED	42	2 weeks	Improved symptoms, corneal staining, conjunctival staining, conjunctival redness	Test = oil-in-water emulsion

ADDE - aqueous deficient dry eye; DED - dry eye disease; EDE - evaporative dry eye; HPMC - hydroxypropyl methylcellulose; LLT - lipid layer thickness; MGD - meibomian gland dysfunction; N - number of subjects; OSDI - Ocular Surface Disease Index; SS - Sjögren syndrome; TBUT - tear breakup time.

mixture [434,435,437–439]. Meibomian gland material causing severe obstruction has a higher melting point than material from less obstructed glands [434,437,440]. Level 2 and 3 evidence suggests that heating the individual meibomian gland to a temperature of $\geq 40^\circ\text{C}$ is likely to be required for optimal warm compress treatment [433,437,441]. The 40°C recommendation refers to the temperature of the palpebral conjunctiva and the gland, not the temperature on the contact surface of the treatment device or the temperature of the external skin of the eyelids.

Arita and colleagues evaluated the impact of 5 commercially available eyelid-warming devices in 10 subjects with MGD and 10 controls over a 2–4 week period [442]. The 5 devices consisted of 2 dry (non-moist) methods and 3 moist methods. A single application of all 5 devices improved symptom scores, increased TBUT and increased ocular surface temperatures, but only for up to 30 min. The moist devices resulted in “wetness” of the surface of the eyelid skin, resulting in evaporative cooling that tended to limit the beneficial effects of lid warming. Their results showed that repeated eyelid warming with a non-moist device improved tear film function in normal individuals and may have beneficial effects on both tear film and meibomian gland function in MGD patients. They concluded that repeated non-moist warming for 2 weeks or 4 weeks was required to achieve a stable improvement in normals and in those with MGD respectively [442].

A prospective, randomized, contralateral eye study recommended that warm compresses, heated to 45°C , should be applied to the outer lid for a minimum of 5 min. Optimal contact between the compress and eyelid should be achieved and the compresses should be replaced every 2 min to ensure the temperature is maintained [443]. Several preliminary studies on non-dry eye participants have investigated the effect of different warm compresses on eyelid temperature [433,444]. All of the compresses showed an increase in temperature at the lower lid conjunctival surface and none caused any damage to the eyelids. However, only the continuous layered application of warm bundled towels heated in a microwave was able to maintain a temperature of 40°C on the lower lid conjunctival surface [433]. This study concluded that a wet surface improved heat transmission through the lid and should be used versus dry treatments [433]. Care should be taken not to heat the eyelid skin to more than 45°C to avoid thermal damage [445,446]. Fortunately, a safeguard is the individual's pain response, that protects against extensive thermal damage to the eyelid skin as a patient will not tolerate a cloth that is excessively hot [447].

Of possible concern is the heating of the cornea from approximately 36°C to 39.4°C after approximately 8 min [448]. If eye rubbing occurs when the corneal temperature is elevated, corneal deformation and visual blur can result [449]. The risks of ocular massage with elevated corneal temperature have been deemed to require patient instruction on how to optimally perform the procedure [448,450].

A study of subjects with MGD showed that 12 weeks of lid warming therapy resulted in a therapeutic benefit, with excess ocular surface phospholipase activity (which is detrimental to tear film stability) being reduced [451].

In addition to homemade compresses, a wide variety of devices are now commercially available for the management of lid anomalies that will raise the lid temperature for a longer period of time [431,432].

3.2.2.1. Blephasteam. Blephasteam[®] (Thea Pharmaceuticals, Newcastle under Lyme, UK) resembles a swimming goggle and is plugged into an electrical outlet to provide latent heat, without pressure, on the eyelids. A moistened insert is placed into each sealed watertight chamber to provide a warm, high humidity

environment over each eye. A preliminary study on normal subjects found that the device increased the temperature of the eyelids [433], and a study on dry eye patients reported that tear film evaporation was reduced 32% immediately after treatment [452]. Two randomized, controlled, investigator-masked studies found greater efficacy with Blephasteam[®] than with warm towel treatment [429,453] and a randomized, investigator-masked, crossover study conducted on healthy volunteers found Blephasteam[®] warmed the lower eyelid for a significantly longer period of time than warm compresses [453]. Visual acuity also significantly improved after use of Blephasteam[®] [453]. Two prospective, non-randomized studies found improved symptoms in patients with MGD [430,454] and increased TBUT. Decreased acinar diameter and area were also observed in individuals unresponsive to warm compress treatment [430].

3.2.2.2. MGDRx EyeBag[®]. The MGDRx EyeBag[®] (The EyeBag Company, West Yorkshire, UK) is a reusable warm compress, consisting of a cotton and silk bag containing flax seeds, that is heated in a microwave for 30 s. Studies conducted in normal eyes found the MGDRx EyeBag[®] achieved higher ocular temperatures than another heating mask [455], and also maintains heat longer than a simple heated face cloth in both *in vitro* and *in vivo* studies [431,432]. A randomized, investigator-masked, contralateral study reported an improvement in symptoms after using MGDRx EyeBag[®] twice a day for two weeks [456]. The benefits lasted for up to 6 months, with occasional retreatment sessions leading to greater comfort.

3.2.2.3. EyeGiene[®] mask. The EyeGiene[®] mask (Eyedetec Medical, Danville, CA, USA) uses disposable pressure-activated warming units [455]. A randomized, controlled, examiner-masked study found the EyeGiene[®] mask was similar in efficacy to a warm towel, but not as effective as Blephasteam[®] [429] or as effective in raising ocular temperature as a flaxseed-based eye mask [457].

3.2.2.4. Infrared warm compression device. The infrared warm compression device consists of an eye mask with two rigid patches over the eyes. Each patch has 19 light emitting diodes, emitting near infrared radiation from 850 to 1050 nm, with a peak at 940 nm. The infrared warm compression device was used to treat 37 subjects with obstructive MGD in a prospective, non-comparative interventional case series for 5 min, twice a day, for 2 weeks with closed eyelids. Total subjective symptom scores improved and there was also significant improvement in tear evaporation rates during forced blinking, fluorescein and rose bengal staining and meibomian gland orifice obstruction score [458].

3.2.3. Physical treatments

The purpose of applying physical treatment to the meibomian glands is to improve and/or restore the function of the glands by ameliorating or removing ductal obstruction, thus allowing the glands to become functional [459]. Physical expression for therapeutic amelioration of obstructive material should not be confused with diagnostic expression, where minimal forces are used to determine if the gland is functional [441].

There are three established methods for physically treating ductal obstruction; warm compresses and various heating devices use heat to raise the temperature to soften or preferably liquefy the obstructive material, physical force is used to compress the glands to physically express the material from the obstructed gland, and intraductal probing introduces a thin wire into the obstructed orifice and then uses force to expel the obstructive material.

3.2.3.1. Forceful expression. There is a long history describing a variety of methods for forceful expression of the meibomian glands

without the application of heat [460–462]. These methods include isolating the eyelid to be expressed between the examiner's fingers and applying force by squeezing the eyelids against each other, or utilizing a rigid object on the inner surface of the eyelid and the thumb or finger or another rigid object on the outer lid to apply force [460,463]. However, a limiting factor with all these methods is pain experienced by the patient, which is only minimally relieved by topical anesthetics. The amount of pain increases rapidly as the force of expression exceeds 5 pounds per square inch (PSI) [464]. The usual maximal tolerable force is 15 PSI, which is frequently marginal or inadequate to express obstructive material [464].

A study investigated the efficacy of four in-office forceful expressions over a period of 6 months in conjunction with daily warm compress therapy [461]. The number of expressible glands, quality of secretion and lipid layer thickness significantly improved and all patients reported improved comfort and decreased symptoms associated with DED [461].

3.2.3.2. LipiFlow. LipiFlow[®] (TearScience, Morrisville, NC, USA) was designed to bypass the impediments to heat transfer through the eyelid tissue and simultaneously evacuate the gland contents, while heating the glands to therapeutic levels of 42.5 °C [459,465]. It has been demonstrated, in both randomized controlled and uncontrolled clinical trials, that the single 12-min procedure of the LipiFlow[®] system is safe and effective for treating MGD and that the effect can be sustained [465]. The first prospective, open-label, randomized, crossover, multicenter study compared a single LipiFlow[®] treatment to daily warm compress therapy [459]. The group undergoing LipiFlow[®] treatment showed a significant improvement in symptoms, meibomian gland secretion and TBUT at one month, while the warm compress group showed improvement only in symptoms. After receiving the crossover treatment, the warm compress group also demonstrated significant improvement in gland function and TBUT.

More recently, a prospective, randomized, crossover, observer-masked clinical trial, compared a single LipiFlow[®] treatment to a robust 3 month regime of twice-daily warm compresses combined with both lid massage and lid hygiene [72]. These subjects were evaluated for six months, demonstrating that a single LipiFlow[®] treatment performs at least as well as the rigorous twice-daily hygiene, heat and massage regime and that the effects of the single LipiFlow[®] treatment were sustained for six months [466]. A more recent prospective, multicentre, open-label 12 month clinical trial randomized 200 subjects (400 eyes) and reported that the single LipiFlow[®] treatment effect, with improved gland function and dry eye symptoms, can be sustained for up to 12 months [467]. An uncontrolled single center, observational study found significant and sustained improvement in meibomian gland function and symptoms for up to 3 years after a single treatment [468].

3.2.3.3. Intense pulsed light (IPL). Intense pulsed light (IPL) has been used in dermatology to deliver intense pulses of non-coherent light from 500 nm to 1200 nm in wavelength to treat various conditions, including skin pigmentation, sun damage and acne [469]. A hand held computer-controlled flashgun delivers the appropriate light, which is filtered for specific action.

IPL was first reported anecdotally over 15 years ago for the treatment of MGD. A more recent prospective, double-masked, placebo-controlled, paired-eye study compared the effect of multiple pulses of IPL on one eye while the other eye received a sham treatment. The treatment imparted an improvement in tear film quality and a reduction in symptoms [470]. A retrospective analysis of medical records has independently shown a 77% improvement in meibomian gland function in at least one eye and an 89% improvement in dry eye symptoms when IPL was used in

combination with manual meibomian gland expression [471]. A retrospective multicentre cohort review of 100 patients with MGD treated with IPL showed similar clinical improvements and concluded that IPL therapy was a safe and effective treatment for EDE [472].

3.2.3.4. Intraductal probing. Intraductal meibomian gland probing was first described in 2010 [473]. This initial publication reported data from a retrospective chart review of 25 consecutive patients who all had signs and symptoms of obstructive MGD. Immediate post-probing relief was experienced by 24 of the 25 patients and all patients had relief from symptoms by 4 weeks after the procedure. Five patients required one or two retreatment sessions. The patients who underwent a single treatment were followed up on average at 11.5 months post treatment. All of the patients were symptom free at their last follow-up visit [473]. A prospective, longitudinal study performed probing on one eye of 16 individuals presenting with MGD, while the fellow eye was used as a control. Break-up time, vision, pain and photophobia all improved at one week and 6 months post-treatment [474]. A study of three patients with refractory obstructive MGD investigated the amount and change in meibum viscosity after probing. All patients showed improvements in lipid levels and viscosity and 2 of the 3 showed improved TBUT [475]. A study also reported improvement in symptoms after probing for 10 patients with ocular rosacea, MGD, and surface disease refractory to conventional management. Symptoms improved in approximately 50% of subjects at 1 and 6 months, doxycycline was discontinued in 9 of 10 patients and all patients reported decreased use of ocular lubricants [476].

While further research is indicated, especially in view of the invasive nature of the procedure, the possibility of damage to a complex ductal system and the small sample of subjects thus far reported on, the data reported suggest that intraductal probing may offer relief to MGD patients who are unresponsive to conventional treatment.

3.2.3.5. Debridement scaling. One of the primary mechanisms driving obstruction of the meibomian glands is hyperkeratinization of the eyelid margin and duct orifices [477]. As keratinized material is built up around and within the orifice, the gland is obstructed and meibum cannot be delivered from the gland to the tear film. Debridement of the line of Marx, which marks the mucocutaneous junction and the keratinized lid margin, was first reported in 2013 [478]. It is believed that this technique works by mechanically removing accumulated debris and keratinized cells from the eyelid margin to allow increased flow of meibum into the tear film. The prospective, investigator-masked study by Korb and colleagues included a test group of 16 subjects and a control group of 12 subjects, all presenting with symptoms of dry eye and visible changes to the line of Marx [478]. The stained line of Marx and the entire width of the keratinized lower lid margin were debrided in the test group using a stainless steel golf spud. One month post-treatment, significant improvements in symptoms occurred in 22% of subjects and in MG function occurred in 46% of subjects [478]. A prospective, randomized, unmasked, controlled pilot study to determine the effect of lid debridement in subjects with Sjögren syndrome was recently published [479]. All 14 subjects were female, seven were randomized to the treatment group and seven were controls. One month after debridement scaling subjects reported improved symptoms, ocular staining was reduced, and re-establishment of meibomian gland function was demonstrated [479].

A lack of sham treatment and masking in both reported studies [478,479] must be considered. Larger studies and additional study designs are needed to confirm the mechanisms of action to explain the positive results reported to date.

3.3. Blinking abnormalities and ocular exposure

Incomplete blinking or an inability to close the eyes fully during sleep can result in drying of the ocular surface [480–482], and thus appropriate measures to address any blink or lid closure abnormalities are worthy of consideration in the management of the patient with signs or symptoms of DED.

Further details on the impact of abnormal blink patterns and eye closure on DED are detailed in the TFOS DEWS II Pathophysiology Report [483].

3.3.1. Treatment for corneal exposure

Studies investigating treatments for any form of inadequate lid closure are mostly Level 3 [481,484–487], and include the evaluation of tear supplements, ointments (typically instilled at night), moisture goggles, night time eyeshields that achieve mechanical closure of the lids, and forced temporary closure of the lids by patching or taping. For those unwilling or unable to perform eyelid physical taping overnight, such as those with contact dermatitis or those concerned with iatrogenic lash epilation [481,484], alternative methods exist. These methods include eyecups of a variety of different designs and materials, and the use of thin polymer films (such as plastic food wrap). Level 1 evidence suggests that films provide better protection to the exposed cornea, with fewer complications, than lubricants [488]. Mechanical closure of the eyelids by various methods in critically ill populations is reported to equally, or better, protect the exposed cornea, with fewer complications, than lubricants [488,489]. However, although it is universally accepted that mechanical closure of the eyelids is mandatory in the management of severe exposure keratopathy, there are no randomized prospective controlled clinical studies to establish the efficacy or superiority of different treatments.

Persistent or severe cases of corneal exposure may require one of a variety of surgical procedures, including implantation of upper lid weights [481,490,491], lid springs, lid reconstruction or partial/complete tarsorrhaphy. Rigid gas permeable scleral lenses can also be an option in cases of exposure keratitis, as detailed in section 3.3.3.2.

3.3.2. Entropion and ectropion

Entropion and ectropion result in ocular surface exposure and entropion often results in concurrent trichiasis, causing symptoms of dry eye [492]. Facial nerve palsy results in a paralytic lower lid ectropion and upper eyelid retraction due to reduced activity of the orbicularis oculi. Other causes include trauma, tumors, facial surgery and age-related lid laxity.

Management of both entropion and ectropion is usually surgical and techniques include tightening the canthal tendons and removing a cicatrix or other mechanical reason for eyelid malposition [493–497]. In a Level 2 study, correction of entropion improved vision, punctate keratopathy and TBUT, but not Schirmer results [498]. A further Level 2 study showed that tarsorrhaphy was a successful procedure for entropion and supported epithelial healing in severely dry eyes [499].

3.3.3. Contact lenses

Contact lens use for the correction of refractive error in healthy eyes may be accompanied by symptoms of dryness and discomfort and the options to manage such discomfort have been addressed in detail elsewhere [500]. Despite their association with dryness, contact lenses have a potential role in the management of DED. In the framework of the original TFOS DEWS report, contact lens use was listed with permanent punctal occlusion and serum tears as options for more advanced DED [1]. The main reason that contact lens wear was reserved for management of more severe forms of

DED is to acknowledge that OSD and contact lens wear are each risk factors for microbial keratitis, although the compounded risk factor is unknown. The mechanism by which contact lens wear is therapeutic has yet to be elaborated in detail, but relevant aspects include mechanical protection and reduction in corneal desiccation.

The decision to use a contact lens in the therapeutic management of DED must take into consideration the risks and benefits of the individual case. Reports of microbial keratitis occurring in patients fitted with contact lenses in the management of OSD have emerged [501], including cases that progressed to endophthalmitis [502]. Contact lenses worn for severe DED are often used on an extended wear basis, which is associated with an increased risk of microbial keratitis relative to daily wear [503–506].

The management of DED can be undertaken with either soft or rigid lenses. Depending upon the severity and nature of the OSD, therapeutic soft contact lenses, which are often termed bandage contact lenses, can be prescribed for short-term (days) or long-term (years) use and may be worn on either a daily wear or extended wear schedule.

3.3.3.1. Therapeutic soft contact lenses (bandage lenses). The purpose of a bandage contact lens is to improve ocular comfort and reduce the effects of an adverse environment. The availability of silicone hydrogel soft lens materials, with high oxygen transmissibility, has encouraged the application of these devices for the therapeutic management of OSD, and they are typically used on an extended wear basis [507].

Bandage contact lenses are considered a useful adjunctive management option for a range of ocular surface pathologies, including recurrent corneal erosion [508], corneal abrasion [509], bullous keratopathy [510], and after corneal surgery [511–514]. It has been suggested that bandage contact lenses may stabilize the tear film and assist with the restoration of epithelial cell turnover [515], and potentially aid in the management of corneal pain by insulating sensitized corneal nerves from environmental stimulation [516,517]. The exact mechanism by which a bandage soft lens relieves pain has not been elucidated, but likely involves direct shielding of nociceptors at the ocular surface or support of cellular structure and extracellular matrix elements that serve a shielding role. A protective effect may arise in preventing drying or cooling of the ocular surface or in shielding the ocular surface nociceptors from lid and tarsal conjunctival related trauma, for example in cicatrizing disease. The use of soft bandage contact lenses for DED is supported by Level 3 evidence that pain relief with bandage soft contact lenses can be achieved in corneal diseases other than DED [518], for example, when there is nociceptive pain after trauma and surgery [519].

There is currently a relative dearth of literature relating to the specific application of bandage contact lenses for the management of DED. A recent prospective, randomized (Level 1) study of 40 subjects with Sjögren syndrome that compared the efficacy of bandage contact lenses to autologous serum concluded that silicone hydrogel contact lenses (worn as a bandage contact lens), were effective in the management of Sjögren syndrome-associated DED [223]. After six weeks, subjects fitted with bandage contact lenses had a significant improvement in best-corrected visual acuity (which remained stable for up to six weeks after discontinuing contact lens wear) and significantly improved OSDI scores, compared with subjects treated with autologous serum. Both intervention groups also showed relative improvements in quality of life scores, tear break-up time and corneal staining, compared with baseline; there were no adverse events observed in either group. Furthermore, in a Level 2 study involving seven patients with GVHD and moderate to severe DED, the use of silicone

hydrogel lenses, worn on a seven-night continuous wear basis for one month, was found to reduce dry eye symptoms and improve visual acuity compared with pre-treatment [515].

Timely treatment of any corneal epitheliopathy is considered important for minimizing the risk of developing chronic pain; once there has been centralization of neuropathic pain, a bandage contact lens, which might reduce peripheral signalling, may be insufficient for reducing symptoms [516].

3.3.3.2. Rigid gas permeable scleral lenses. There is increasing appreciation that daily wear of a rigid gas permeable scleral lens may play an important role in the management of moderate to severe DED, possibly due to the fact that they can provide a reservoir of tears between the lens and the ocular surface. The use of scleral lenses has been investigated in other conditions such as chronic GVHD [520–522], and Stevens-Johnson syndrome [523]. Use of a scleral lens as a prosthetic device in a series of patients, including those with OSD, was first reported from the United States in 1990 [524], with similar reports emerging from around the world that same decade [525,526]. A case series (Level 3 evidence) has described the long-term application of scleral contact lenses as an alternative to tarsorrhaphy in three patients who had developed unilateral lagophthalmos and corneal anesthesia secondary to post-surgical facial nerve paralysis [527]. The scleral lens modality was reported to provide effective protection to the ocular surface and optimize visual function in these patients. The use of scleral lenses for OSD is more widely reported in a variety of reviews [528–530].

Recent clinical studies report success in the management of DED with scleral lenses, mini-scleral lenses and PROSE (Prosthetic Replacement of the Ocular Surface Ecosystem) [520,522,527,531–538].

4. Anti-inflammatory therapy

4.1. Topical glucocorticoids

Corticosteroids are successfully used in the treatment of a wide range of inflammatory diseases, including DED.

4.1.1. Basic research

Desiccating stress can induce ocular surface damage and generate innate and adaptive immune responses. These inflammatory cascades lead to further ocular surface damage and the development of a self-perpetuating inflammatory cycle. Inflammation can also cause alterations to the neurobiology of the ocular surface, as described in the TFOS DEWS II Pain and Sensation Report [539].

Steroids have been found to be useful in neural pain modulation, which may be beneficial in managing neuropathic pain, but this modulation has not been evaluated in the eye [540]. It is clear from numerous experimental studies in animal models that topical corticosteroids are effective in breaking the vicious cycle of immune responses in DED. Topical methylprednisolone (1%) treatment suppressed MMP-9 and inflammatory cytokine expression and mitogen-activated protein kinase activation in the corneal epithelium of experimental murine dry eye. As a result, desquamation of apical corneal epithelial cells was decreased and the integrity of corneal epithelial tight junctions was maintained [541,542]. In DED induced by intralacrimal gland injection of botulinum toxin-B in a mouse model, topical 0.1% fluorometholone alone or in combination with cyclosporine A, was able to partially restore tear production and significantly improve the ocular surface

[543]. Murine studies have explored new therapeutic agents for DED. One study showed that a significant decrease in corneal fluorescein staining was observed after topical treatment with 1% methylprednisolone, 5% interleukin (IL)-1R antagonist, and 0.05% cyclosporine A [544]. A significant decrease in the numbers of central corneal CD11b⁺ cells, corneal lymphatic growth, and corneal IL-1 β expression were also demonstrated after treatment with IL-1R antagonist and methylprednisolone, which were not observed after treatment with the vehicle [544].

Selective glucocorticoid receptor agonists can also be used as a therapeutic target for DED. In the atropine-induced dry eye rabbit model, selective glucocorticoid receptor agonists and 0.1% dexamethasone were fully efficacious, maintaining tear volume and breakup time [545]. Both agents showed no effects on intraocular pressure (IOP) or body weight, whereas dexamethasone significantly increased IOP and inhibited the increase of body weight due to muscle wasting [545]. Furthermore, selective cyclooxygenase-2/eicosanoid-prostanoid receptor (COX-2/EP receptor) inhibition is suggested as a therapeutic target in a murine DED model [546]. Topical COX-2/EP receptor inhibitors reduce the number of CCR7⁺CD11b⁺ cells on the ocular surface with inhibition of cellular lymph node homing and suppression of Th17 driven immune responses. Dry eye-induced loss of conjunctival goblet cells was reversed, and corneal erosion was improved by each topical treatment [546].

4.1.2. Clinical studies

A number of topical corticosteroid preparations can be used to modulate anterior segment inflammation and multiple studies have shown the clinical value of their short-term use in managing DED. Several RCTs have been published investigating the value of using various corticosteroid formulations in the management of DED (Table 8) [547–557].

Of recent interest is that imaging (rather than clinical evaluations typically associated with dry eye assessment) may also be valuable in establishing the predictive potential for the management of DED with topical corticosteroids [555,558].

4.1.3. Complications

While it appears that topical corticosteroids may be valuable in the management of DED, their long-term use is not without risk of complications. These include ocular hypertension, cataracts and opportunistic infections, even after short periods of use [547]. For patients with moderate-to-severe disease that is not controlled with other therapies, repeated short-term pulse therapy of corticosteroids can be an alternative approach. Fifty-three patients with Sjögren syndrome were treated with topical non-preserved 1% methylprednisolone 4 times a day for 2 weeks, and then re-evaluated and tapered off the medication until they demonstrated no corneal fluorescein staining or symptoms [559]. Most patients were in a disease-free state for a relatively long period (57 weeks) after the first pulse therapy, and 11 individuals (21%) experienced a recurrence of either symptoms or signs. After the second pulse therapy, a disease-free period of 72 weeks was observed and only 1.9% of patients had a recurrence. No serious complications (such as IOP elevation or cataract formation) were encountered during the entire follow-up period [559].

The use of topical steroids such as fluorometholone and loteprednol may also be considered, which have a lower likelihood of increasing IOP and inducing cataract formation [560–562]. However, even fluorometholone has been reported to cause cataract after a continuous 4-month application period [563]. A recent retrospective safety study, listing 77 published studies, concluded that topical treatment with loteprednol etabonate has minimal

Table 8
Level 1 and 2 studies of topical corticosteroids for managing dry eye disease.

Author	Subject group/Drug	N	Treatment duration	Reported benefits	Comments
Marsh & Pflugfelder, 1999 [547]	SS. Non-preserved 1% methylprednisolone	21	2 weeks	Improved symptoms, corneal staining, filamentary keratitis	Retrospective case series. Prolonged treatment for up to 6 months resulted in increased IOP and cataracts
Sainz de la Maza Serra et al., 2000 [548]	SS. Non-preserved 1% methylprednisolone	15	2 months	Improved symptoms, corneal staining	Prospective. 15 subjects treated with punctal plugs post corticosteroid. Further 15 subjects also treated with punctal plugs alone.
Avunduk et al., 2003 [549]	KCS with or without SS. 3 groups: ATS only; ATS plus NSAID (flurbiprofen); ATS plus topical corticosteroid (0.1% FML)	32	1 month	ATS plus corticosteroid group had improved symptoms, reduced CFS and rose bengal staining, improved goblet cell appearance and reduced inflammatory cells	Prospective, Single-masked, RCT
Pflugfelder et al., 2004 [550]	KCS. 0.5% loteprednol etabonate vs vehicle	64	1 month	Improved symptoms and hyperemia in more severe subjects	Prospective, double-masked, placebo-controlled, RCT. No increase in IOP over placebo
Lee et al., 2006 [551]	KCS. 0.1% prednisolone drops in one eye and 0.1% HA drops in the other	41	1 month	Improved symptoms, NGF levels and impression cytology scores in prednisolone-treated eyes only	Prospective, double-masked, RCT
Yang et al., 2006 [552]	KCS. 0.1% FML	30	1 month	Improved symptoms, CFS, Schirmer score, tear breakup time, conjunctival hyperemia	Prospective, non-masked
Jonisch et al., 2010 [553]	OSD. 0.01% dexamethasone (unpreserved)	31	3 months	65% reported moderate or complete resolution of symptoms, 22% had mild improvement and 13% had no change in symptoms. No relevant elevation in IOP.	Retrospective chart review
Sheppard et al., 2014 [554]	Mild to moderate DED. Loteprednol etabonate (LE) or ATS before the initiation of topical cyclosporine A (CsA) therapy	61	6 weeks	LE pre-treatment significantly reduced CsA stinging. Both groups showed significantly improved OSDI scores, with LE showing more OSDI improvement. Both pre-treatment strategies improved symptoms, Schirmer scores, CFS, lissamine staining, and adjunctive ATS use.	Prospective, multicenter randomized double-masked parallel group
Kheirkhah et al., 2015 [555]	KCS due to MGD. 3 groups: ATS only; loteprednol etabonate 0.5%; loteprednol etabonate 0.5% + tobramycin 0.3%	60	1 month	Subjects treated with ATS or loteprednol alone with near-normal baseline subbasal nerve fiber demonstrated significant improvement in symptoms and CFS	Prospective, double-masked, RCT
Lin & Gong, 2015 [556]	SS. 0.1% FML and 0.1% HA vs 0.5% CsA and 0.1% HA	40	2 months	Improved symptoms, CFS, conjunctival hyperemia, GCD, TBUT (FML > CsA)	Prospective, parallel-group, RCT
Pinto-Fraga et al., 2016 [557]	KCS. 0.1% FML vs PVA ATS	41	21 days	Subjects treated with FML maintained the status of their ocular surface after exposure to the adverse environment; those treated with PVA tears had notable impairment in corneal and conjunctival staining and hyperaemia	Prospective, double-masked, placebo-controlled, RCT. Included 2 h adverse environment exposure

ATS – artificial tear solution; CFS – corneal fluorescein staining; CsA – cyclosporine A; FML – fluorometholone; GCD – goblet cell density; HA – hyaluronic acid; IOP – intraocular pressure; KCS – keratoconjunctivitis sicca; MGD – meibomian gland dysfunction; N – number of subjects; NGF – nerve growth factor; NSAID – nonsteroidal anti-inflammatory drops; OSD – ocular surface disease; OSDI – ocular surface disease index; PVA – polyvinyl alcohol; SS – Sjögren's syndrome; TBUT – tear break up time.

effect on IOP when used in the treatment of a wide range of ocular surface and intraocular inflammatory disorders, including ocular allergy, DED, anterior uveitis, penetrating keratoplasty, endothelial keratoplasty, and postoperative pain and inflammation following ocular surgery [564].

4.1.4. Steroid pre-treatment

In a prospective, double-masked, multicenter RCT, 0.5% loteprednol therapy two weeks before the initiation of long-term topical 0.05% cyclosporine provided more rapid improvement in Schirmer score, corneal fluorescein staining, lissamine green staining, and symptoms, than topical cyclosporine or artificial tears alone [554]. Loteprednol etabonate induction therapy significantly decreased the incidence of severe stinging and discontinuation of topical cyclosporine [554]. Similarly, treatment with topical 1% methylprednisolone and cyclosporine for an initial three-week period provided faster symptom relief and improvement in ocular signs than topical cyclosporine alone [565].

4.1.5. Preservative-free options

It has become accepted that preservative use in DED is damaging to the ocular surface [98,566,567], and thus the use of preservative-free topical steroids is growing. In a randomized, parallel-group, case-control study, the efficacy of preservative-free 0.1% HA and 0.1% fluorometholone combined with 0.05% cyclosporine was compared with the efficacy of preserved 0.1% HA and 0.1% fluorometholone combined with 0.05% cyclosporine, in treating DED [118]. The preservative-free eye drops improved subjective symptoms, TBUT, Schirmer score and impression cytology findings more than preserved eye drops [118]. Similarly, a retrospective review of 31 patients treated with preservative-free 0.01% topical dexamethasone showed a significant subjective improvement in symptoms in 84% of the subjects with chronic ocular surface irritation, and/or tearing, refractory to various preserved topical steroids, including 0.2% loteprednol, 0.1% fluorometholone and 1% prednisolone [553]. Further details on this topic are covered in the TFOS DEWS II Iatrogenic Dry Eye Report [102].

4.1.6. Sex steroids

A considerable body of basic science and clinical research has investigated the roles of sex steroids (androgens, estrogens and progestins) in the regulation of ocular surface tissues and the adnexa. Clinical studies have also explored the efficacy of these hormones in the treatment of DED. This information is detailed in the TFOS DEWS II Sex, Gender, and Hormones Report [353].

4.2. Non-glucocorticoid immunomodulators

With the exception of cyclosporine, comparatively few clinical trials have been performed using immunomodulating medications in individuals with DED, but demonstration of efficacy within this therapeutic group offers potentially important clues into disease pathogenesis, and may stimulate further research that could lead to commercial development of compounds that may offer demonstrable patient benefit.

4.2.1. Cyclosporine A

The initial TFOS DEWS report noted the importance of ocular surface inflammation not only in the development of, but as a downstream effect and propagator of, DED, and reviewed a range of therapies that function, at least in part, by anti-inflammatory mechanisms of action [1].

Cyclosporine is understood to be an immunomodulatory drug with anti-inflammatory properties, as well as having other actions relevant to managing DED [568–570]. Cyclosporine is a fungal antimetabolite that inhibits IL-2 activation of lymphocytes [570]. It is used systemically as an anti-rejection treatment in patients with organ transplants [571,572], and in autoimmune diseases [573,574], as well as topically in the treatment of allergic, atopic, limbal stem cell dysfunction and autoimmune ocular inflammatory disease [575–578]. Topical cyclosporine was approved by the FDA for the treatment of moderate-to-severe DED in 2003, based on an improvement in tear production measured by the Schirmer test in 15% of patients, compared to 5% of vehicle-treated controls. Treatment with cyclosporine reduces many markers of inflammation [579,580] and also reduces elevated tear osmolarity [63]. Cyclosporine also has anti-apoptotic effects relevant to the known reversal of the normal epithelial cell/leukocyte relationship in DED [581,582], an effect not produced by corticosteroid treatment [583–585]. Additionally, cyclosporine treatment has been reported to result in recovery of reduced goblet cell density in the conjunctiva of subjects with DED [586,587].

A number of Level 1 [588–591] and Level 2 [592,593] studies (Table 9) and several meta-analyses [594–597] (Table 10) have

been published that support the efficacy of cyclosporine in the management of DED. However, the outcome measures (both symptoms and signs) and grading scales differ substantially among these studies, which complicates comparisons of the published work. Nonetheless, taken as a body of work, there is strong Level 1 evidence to support the use of topical cyclosporine in the treatment of DED. However, there are a number of exclusions and caveats. It is important to note that cyclosporine A has been reported to lack efficacy in treating DED from surgical procedures, contact lens use and in thyroid orbitopathy and furthermore has demonstrated amelioration of ocular surface damage in only 53% (9/17) of the randomized clinical trials [595].

Quality of life studies have concluded that topical cyclosporine is cost-effective for the treatment of DED as compared to the use of ocular lubricants [598]. A Level 1 study has also reported the additive value of topical cyclosporine therapy in patients fitted with punctal plugs [306]. Fewer studies have differentiated between ADDE patients and those with EDE, but several Level 1 studies [599–602] (Table 11) have reported positive results (again, with varied outcome measures and scales) following treatment with cyclosporine for evaporative DED/MGD.

Treatment of patients with DED using topical cyclosporine needs to be continued for extended periods of time, as evidenced by the rarity of a clinical “cure” (absence of symptoms following drug discontinuation) [603]. The poor water solubility of cyclosporine makes it difficult to formulate into a topical ocular drop. A novel formulation of cyclosporine 0.1% in an unpreserved single-dose cationic emulsion was recently released in Europe [604]. The active drug formulation was superior to vehicle for change in corneal fluorescein staining from baseline and inflammation reduction, as evidenced by human leukocyte antigen D-related (HLA-DR) response, over 6 months, but there was no symptom change over time by OSDI and 29% of subjects still experienced discomfort on instillation, compared with 9% of subjects using vehicle [604].

4.2.2. Tacrolimus

Tacrolimus, a macrolide produced by *Streptomyces tsukubaensis*, was discovered in 1984 in Japan while searching for new immunosuppressive and cancer chemotherapeutic agents. Like cyclosporine, it blocks T-lymphocyte activity, but its immunosuppressive potential is higher than that of cyclosporine [605].

In an open-label, prospective study with 14 patients with GVHD with severe DED and intolerance to topical cyclosporine, patients were instructed to instill 0.03% topical tacrolimus once a day for three months [606]. Dry eye symptoms and signs improved

Table 9
Level 1 and Level 2 studies of topical cyclosporine for the management of dry eye disease.

Author	Subject group	N	Treatment duration (months)	Reported benefits	Comments
Level 1 studies					
Baiza-Duran et al., 2010 [588]	Moderate to severe DED (Hispanics)	183	3.5	Improved dryness, tearing, FBS, TBUT, corneal staining, Schirmer score	Aqueous solution 0.1% and 0.05%
Chen et al., 2010 [589]	Moderate to severe DED (Chinese)	233	2	Improved dryness, FBS, corneal staining, Schirmer score	Emulsion formulation with BAK
Su et al., 2011 [590]	Mild to severe DED	100	6	Improved OSDI, TBUT, corneal staining, conjunctival staining, Schirmer score	Once daily vs. twice daily dosage
Deveci et al., 2014 [591]	SS	26	1	Improved pain, burning, TBUT, Schirmer score	
Level 2 studies					
Salib et al., 2006 [592]	Post LASIK DED	42	3	Improved Schirmer score	
Perry et al., 2008 [593]	Mild, moderate and severe DED	158	3	Improved OSDI, TBUT, Schirmer score, corneal staining, conjunctival staining	

BAK – benzalkonium chloride; DED – dry eye disease; FBS – foreign body sensation; LASIK – laser in-situ keratomileusis; N - number of subjects; OSDI - ocular surface disease index; SS - Sjögren syndrome; TBUT - tear break up time.

Table 10
Published meta-analyses of topical cyclosporine for the management of dry eye disease.

Author	# reviewed/ total # pts	Symptom benefit	Signs benefit	Comments
Alves et al., 2013 [594]	6 studies/1514	In all studies	In all studies	
Sacchetti et al., 2014 [595]	18 studies/ 2479	Improved symptoms in 100% of studies,	Improved Schirmer score in 72%, corneal staining in 53%, TBUT in 47%	Great heterogeneity in grading scales, duration of treatment
Zhou et al., 2014 [596]	12 studies/ 1660	Improved OSDI	Improved Schirmer score with anesthesia, TBUT	
Wan et al., 2015 [597]	12 studies/ 1367		Improved OSDI, TBUT, corneal staining, Schirmer score without anesthesia, GCD	

DED - dry eye disease; GCD – goblet cell density; TBUT - tear break up time; OSDI - Ocular Surface Disease Index.

Table 11
Level 1 studies of topical cyclosporine treatment for the management of evaporative dry eye/meibomian gland dysfunction.

Author	N	Treatment duration (months)	Symptom benefit	Signs benefit
Perry et al., 2006 [599]	33	3		Lid inflammation, MG inclusions
Rubin et al., 2006 [600]	30	3	Visual blur, burning, itching	Schirmer score, TBUT, secretion quality
Schecter et al., 2009 [601]	37	3	OSDI	TBUT, Schirmer score, corneal staining
Prabhasawat et al., 2013 [602]	70	3	OSDI	TBUT, lid inflammation, MG expressibility

MG – meibomian gland; N - number of subjects; OSDI - ocular surface disease index; TBUT – tear break up time.

significantly with tacrolimus and the authors concluded that topical 0.03% tacrolimus may be a viable alternative for patients with intolerance to topical cyclosporine or in patients where the response to topical cyclosporine is poor. In a prospective, double-masked study of 0.03% topical tacrolimus instilled twice daily in 24 patients with Sjögren syndrome-related dry eye, the average corneal fluorescein staining and rose bengal scores improved statistically after seven days of treatment and continued to improve over 90 days [607]. The Schirmer and TBUT values were unchanged up to 21 days post-treatment, but did show an improvement after 28 days of treatment, relative to baseline.

4.2.3. Non steroidal anti-inflammatory drugs

A variety of non-steroidal anti-inflammatory drugs (NSAIDs) have been used for DED treatment, including 0.1% pranoprofen [608], 0.1% diclofenac [609,610], 0.4% ketorolac [611], and 0.1% indomethacin [610]. The osmoprotective effect of different NSAIDs was evaluated by Sawazaki et al. in a rat model [612]. Diclofenac was able to suppress hyperosmolarity-induced apoptosis and cell growth arrest. In contrast, bromfenac did not exert such a protective action.

Clinical trials have shown that the use of NSAIDs is followed by a reduction in ocular discomfort in patients with DED [613]. However, sporadic case reports of corneal melting in individuals with severe DED have been published [614]. Thus, most published studies with NSAIDs in DED have a duration of no more than 1 month [608,611,613], despite DED being a chronic disease. The effect of NSAID treatment on corneal sensitivity in normal subjects and in patients with DED has been studied. The results of these trials seem to demonstrate that some NSAIDs, diclofenac in particular, have the effect of reducing corneal sensitivity both in normal subjects and in subjects with dry eye [615]. Therefore, it has been suggested that NSAIDs should be used with caution in patients with Sjögren syndrome [610,616].

In a single-masked, randomized, prospective clinical trial on 32 KCS patients, with or without Sjögren syndrome, Avunduk et al. investigated whether anti-inflammatory drops (corticosteroids and NSAIDs) have therapeutic effects [549]. Subjects randomized to receive artificial tears plus topical corticosteroidal drops had significantly lower symptom severity scores, corneal fluorescein

staining and rose bengal staining, and HLA-DR positive cells on days 15 and 30 compared with subjects in control groups. The authors concluded that topical corticosteroids, but not topical NSAIDs, had a beneficial effect on symptoms and signs in moderate-to-severe DED [549].

4.2.4. Biologics

4.2.4.1. Lubricin. Lubricin (proteoglycan-4) is a lubricating, mucin-like glycoprotein that was first identified in synovial fluid [617]. More recently, lubricin has been discovered on the ocular surface and in the meibomian glands [618]. It is a highly effective friction-reducing boundary lubricant, at both synthetic and tissue surfaces, functions synergistically with HA [619–621] and possesses anti-inflammatory properties [622–624]. Lubricin has been shown to reduce friction and prevent shear stress at the cornea-lid interface, while lubricin deficiency leads to increased shear stress and corneal staining [618]. Full-length recombinant human lubricin has recently been generated and characterized *in vitro* [625].

Currently, no lubricin-based lubricants are commercially available. A recent two-week, randomized, double-masked, parallel group study in 39 subjects with moderate DED compared a topical formulation of recombinant human lubricin to a 0.18% HA eye drop [626]. Recombinant human lubricin was found to demonstrate significant improvement in both signs and symptoms of DED compared to HA, with significant improvements in a number of clinical variables, including TBUT, corneal fluorescein staining and eyelid and conjunctival redness.

4.2.4.2. Recombinant human nerve growth factor (RH-NGF). NGF is involved in the regulation of growth, proliferation and survival of neurons and is found naturally in tears [627–629]. NGF has been reported to have trophic effects on the ocular surface, through activation of tropomyosin receptor kinase A (TrkA) and p75 neurotrophin receptor [630]. NGF and TrkA are expressed throughout the ocular surface, including corneal epithelial cells and sensory neurons [631,632].

Topical application of NGF may enhance the production and functional characteristics of the tear film by improving corneal sensitivity, with an improvement of ocular surface signs in dogs with surgically-induced dry eye [633]. In humans, corneal

sensitivity, tear production and visual acuity improvement has also been observed after topical administration of murine-derived NGF eye drops (at a concentration of 200 µg/ml every 2 h for 2 days followed by one drop six times daily until the ulcer healed) [634]. A study in rabbits showed that some of these improvements may be due to nerve regeneration. This study showed that topical NGF sped up the recovery of the subbasal nerve plexus after LASIK surgery [635].

Tavilermide (MIM-D3) is a small-molecule NGF peptidomimetic that increases tear and mucin-like fluids and reduces corneal fluorescein staining in a rat model of dry eye [14,636]. In a Phase 2 randomized clinical trial studying the effect of topical MIM-D3 in patients with DED after exposure to a Controlled Adverse Environment chamber to exacerbate dry eye severity, MIM-D3 1% reduced corneal fluorescein staining and conjunctival lissamine green staining after 28 days of treatment when compared to placebo [637]. Similarly, MIM-D3 5% reduced the symptoms of ocular dryness when compared to placebo. In patients with more severe symptoms, both MIM-D3 1% and 5% concentrations showed a significant reduction in symptoms compared to placebo [637]. However, it should be noted that the MIM-D3 clinical trial did not meet its pre-specified primary endpoints with respect to total corneal fluorescein staining and worst symptom score [637].

4.2.4.3. Tumor necrosis factor α -stimulated gene/protein-6 (TSG-6). Mesenchymal stem/stromal cells (MSCs) suppress inflammation in animal models of myocardial infarction, corneal injury and peritonitis [638–640]. It has been proposed that MSCs reduce inflammation through secretion of tumor necrosis factor (TNF)- α -stimulated gene/protein-6 (TSG-6), which has shown therapeutic effects in experimental models of corneal inflammation [641–643]. In a study that investigated the effect of TSG-6 in murine models of dry eye and Sjögren syndrome, topical application of TSG-6 improved tear production, reduced corneal fluorescein staining, and increased goblet cell density when compared to phosphate buffered saline-treated controls [644]. Additionally, TSG-6 reduced the levels of IL-2, interferon-gamma (IFN- γ), IL-1 β , and IL-6 in the intraorbital gland. On the ocular surface, TSG-6 significantly reduced the levels of IL-2, IFN- γ , IL-1 β , and IL-6 when compared to controls [644]. In a comparative study evaluating the effects of topical administration of TSG-6, cyclosporine and prednisolone in a mouse model of dry eye, TSG-6 showed a similar effect to cyclosporine and prednisolone, resulting in improved tear production and goblet cell density [642]. Additionally, TSG-6 and cyclosporine had a similar effect, reducing corneal fluorescein staining and repressing the levels of IFN- γ and TNF- α on the ocular surface and within the lacrimal gland [642].

4.2.4.4. Interleukin-1 receptor antagonist (IL-1Ra). Interleukin-1 receptor antagonist (IL-1Ra) is a protein produced mainly by activated monocytes and tissue macrophages, but also epithelial cells. This protein inhibits the pro-inflammatory action of IL-1 α and IL-1 β by competitively blocking their binding to the IL-1 cell receptor 1 (IL-1R1); when IL-1Ra binds IL-1R1 there is no signalling generated, hence it is an IL-1 antagonizing ligand [645–647]. The IL-1Ra gene is generally upregulated in inflammatory states [646]. Treatment with topical human recombinant IL-1Ra reduces inflammation in animal models of ocular surface inflammation [647–650]. In a murine model of dry eye, topical treatment with IL-1Ra was more effective than CMC in reducing lissamine green staining and increasing tear secretion. Topical IL-1Ra also reduced aberrant acidification of goblet cell mucins and pathological keratinization [651]. In a study that compared the effects of topical IL-1Ra, cyclosporine and methylprednisolone in mice with dry eye, the reduction of corneal fluorescein staining was comparable among the three treatments.

However, only IL-1Ra and methylprednisolone reduced the number of central corneal CD11b + cells, corneal lymphatic growth and the corneal expression of corneal IL-1b [544]. In a Phase 2 randomized clinical trial that evaluated the effects of topical IL-1Ra (anakinra; Kineret[®]) and vehicle three times a day for 12 weeks, treatment with IL-1Ra 2.5% significantly reduced corneal fluorescein staining when compared to baseline values, and significantly reduced symptoms when compared to the vehicle [652]. Additionally, treatment with IL-1Ra induced complete bilateral corneal fluorescein staining clearance in 29% of subjects, compared to 7% in subjects treated with the vehicle.

4.2.4.5. Anti tumor necrosis factor- α therapy (TNF- α). TNF- α is a cytokine with pro-inflammatory and co-stimulatory effects in multiple cell types; it regulates immune cell trafficking and activation [653,654]. TNF- α expression is elevated in the conjunctiva and tear fluid in animal models and in patients with Sjögren syndrome and other types of DED [655–657]. Some studies have evaluated the effect of systemic treatment with TNF- α blocking agents such as infliximab and etanercept, with conflicting results being reported [658–661]. A further study, which compared topical infliximab and balanced salt solution to treat mice with induced dry eye, showed that mice treated with infliximab had increased tear volume and decreased levels of conjunctival inflammatory cytokines IL-1 β , IL-6, IL-17, and IFN- γ , as well as improved goblet cell density [662]. Researchers have also shown that both TNF- α blockers HL036 and etanercept decreased inflammation in the lacrimal gland and cornea of mice with experimentally-induced dry eye by suppressing IFN- γ , IL-21, and IL-6 [663].

4.2.4.6. Anti Interleukin-17 (IL-17) therapy. Th17 cells have been implicated in the pathogenesis of numerous autoimmune diseases. An increased expression of Th17-associated cytokine IL-17 has been demonstrated to promote disruption of the corneal epithelial barrier, thus playing a role in the pathogenesis of DED [664–666]. In an *in vivo* model of dry eye, treatment with IL-17 antibody significantly reduced corneal fluorescein staining in mice [665]. Another study showed that antibody neutralization of IL-17 in mice with experimental dry eye ameliorates corneal epithelial barrier dysfunction (reducing fluorescein permeability) and expression of MMP-3 and MMP-9 [666]. Additionally, treatment with anti-IL-17 antibody has been shown to significantly reduce lymphangiogenesis in mice with dry eye, which may aid in reduction of DED-related immunity [667].

In summary, biologic molecules hold a promising future in the treatment of DED. However, although many biologics have been thoroughly investigated in animal models, human studies remain scarce and well-designed human trials are required to further assess their therapeutic role.

4.2.5. Neuropeptides

Substance P, calcitonin gene-related peptide (CGRP), neuropeptide Y (NPY) and vasoactive intestinal peptide (VIP) have been evaluated in a variety of lab-based studies and clinical studies on normal eyes and in DED. The decreased tear levels of NPY and CGRP in DED are related to impaired lacrimal function [629]. These findings suggest that NPY and CGRP could become useful biomarkers and have therapeutic activity in dry eye [629,668].

The effect of VIP has been tested on immortalized human meibomian gland epithelial cells [669]. The cells transcribe and translate VIP and mACh receptors; VIP activates the adenylyl cyclase pathway; VIP increases intracellular [Ca²⁺] in meibomian gland cells; and VIP stimulates meibomian gland cell proliferation when combined with forskolin.

Most of the studies investigating neuropeptides to date have

been performed in moderate and severe neurotrophic keratitis with concomitant DED, but not directly in individuals with DED [670].

4.2.6. Conclusions

The range of mechanisms of action of the medications discussed in this section, that have at least some demonstrable efficacy in the treatment of patients with DED, gives some insight into the complex pathophysiology of this disease. Clearly, further research is warranted.

4.3. Lymphocyte function-associated antigen 1 (LFA-1) antagonist

One strategy to inhibit or decrease T cell mediated inflammation in DED is to prevent T cells from interacting with other immunologically active cellular elements. Integrins are heterodimeric cell surface receptors, ubiquitous in a variety of cellular and physiologic processes, including cell adhesion, migration and activation, steps crucial for T cell activity and survival [671]. Of the 24 known integrin heterodimers, the $\beta 2$ subfamily of integrins is found only on lymphocytes [671]. Lymphocyte function-associated antigen-1 (LFA-1) is a member of this integrin family. The primary ligand for LFA-1 is the intercellular adhesion molecule 1 (ICAM-1), expressed on a variety of cells, including endothelial and epithelial cells and antigen presenting cells [672]. Binding between LFA-1 and ICAM-1 has been described as the “immunologic synapse” and a critical step in the pathway toward T cell activation [673].

4.3.1. Lifitegrast

Lifitegrast is a small molecule integrin antagonist, engineered to mimic ICAM-1's binding domain to LFA-1 and believed to act as a competitive antagonist to block binding between LFA-1 and ICAM-1, resulting in inhibition of T cell migration into target tissues, reduction of cytokine release, and reduction of further T cell recruitment [674–676].

Lifitegrast 5% ophthalmic solution has been studied as a topical treatment for DED and five clinical trials have been published to date. In a Phase 2 clinical trial on 230 patients [677], a significant response was observed for the pre-specified secondary endpoints of mean change from baseline to day 84 in inferior corneal staining and for a vision-related function subscale, but not for the primary efficacy endpoint of mean inferior corneal staining. In a Phase 3 clinical study (OPUS-1), involving 588 subjects with DED [678], a significant response was reported in the primary efficacy variable of mean change from baseline to day 84 in inferior corneal staining as well as other secondary efficacy endpoints (total corneal staining and conjunctival lissamine green staining). However, the study did not meet the co-primary endpoint for symptoms (the vision-related function subscale of OSDI), though significant improvement was reported for treated subjects in several secondary efficacy symptom endpoints. A second Phase 3 clinical study, OPUS-2, reported results from 718 participants treated with lifitegrast 5% or placebo over 84 days [679]. In this trial, significant improvement was reported in the primary efficacy endpoint (change from baseline to day 84 in Eye Dryness Score; visual analog scale) as well as the secondary symptom endpoint of ocular discomfort. However, improvement was not observed in lifitegrast-treated subjects in the co-primary endpoint of mean change from baseline to day 84 in inferior corneal staining, in contrast to the results from OPUS-1. The SONATA long-term safety study reported on 331 patients treated with lifitegrast twice daily or placebo for 350 days [680]. Lifitegrast appeared safe and well tolerated with no serious ocular adverse events reported and a safety profile that was similar to that of the previously published studies.

Taken together, these Level 1 studies demonstrated the efficacy

of lifitegrast, and the FDA approved Xiidra™ (lifitegrast 5% ophthalmic solution Shire, Lexington, MA, USA) in a single dose unit format, in July 2016, for the treatment of both signs and symptoms of DED.

4.4. Inflammatory modulation with systemic and topical antibiotics

4.4.1. Tetracycline therapy

Tetracycline and its analogues (minocycline, doxycycline) are broad-spectrum antibiotics that inhibit protein synthesis by inhibiting the binding of aminoacyl-tRNA to the mRNA-ribosome complex. It is hypothesized that a decrease in bacteria-producing lipolytic exoenzymes [681,682], and inhibition of lipase production [683], with resultant decrease in meibomian lipid breakdown products, may contribute to improvement in clinical parameters in MGD and anterior blepharitis associated with DED. These agents also have anti-inflammatory properties. They decrease the activity of collagenase, phospholipase A2, and several MMPs, and decrease the production of inflammatory mediators such as IL-1 and TNF- α in a wide range of tissues, including the corneal epithelium [541,542,684–686]. In experimental murine models of dry eye, topically applied doxycycline was found to preserve corneal epithelial smoothness and barrier function [541,542], and to alleviate ocular surface inflammation [687]. Similarly, minocycline decreases the production of diglycerides and free fatty acids in meibomian secretions [681]. However, evidence exists to suggest that doxycycline, tetracycline and minocycline do not duplicate the ability of azithromycin to stimulate differentiation and lipid accumulation in human meibomian gland epithelial cells [688].

Tetracycline and its analogues are often used to treat disorders that are associated with DED such as acne rosacea, MGD and blepharitis. Doxycycline and minocycline achieve a higher concentration in tissue and have a lower renal clearance, longer half-life and higher level of binding to serum proteins than tetracycline and oxytetracycline [689], and are often prescribed in cases of ocular inflammatory diseases because of these properties.

Rosacea, including its ocular manifestations, is an inflammatory disorder that occurs mainly in adults, with peak severity in the third and fourth decades. Evidence exists to suggest that it is strongly correlated with MGD [690] and that Demodex infestation may be associated with its development [691–694]. Strong evidence exists that topical azelaic acid, ivermectin, brimonidine, doxycycline and isotretinoin, and oral tetracyclines (doxycycline and minocycline) are effective treatments for rosacea [695,696]. However, strong evidence also exists to show that isotretinoin destroys human meibomian glands and induces keratinization of the meibomian gland ducts [477,697], and thus its topical use for treatment of the ocular surface may not be advisable.

Tetracycline and its analogues have been shown to reduce subjective symptoms and hyperemia associated with ocular rosacea in small clinical case series [698,699], with a single daily dose of doxycycline as low as 40 mg proving to be effective [700,701]. A prospective, randomized, double-masked, placebo-controlled, partial crossover trial, compared the ability of oxytetracycline to provide symptomatic relief of blepharitis, in 43 patients with and without rosacea [702]. Only 25% of the patients with blepharitis without rosacea responded to the antibiotic, whereas 50% responded when both diseases were present. A comparative prospective interventional study consisting of 44 subjects showed that elevated tear levels of MMP-8 on the ocular surface of individuals with rosacea was found to be reduced significantly after 4- and 8-week treatment with oral doxycycline [703]. A review suggested that additional Level 1 studies are necessary to further assess the efficacy of tetracyclines in the management of ocular rosacea [696].

Chronic blepharitis is typically characterized by inflammation of

the eyelids and there are many sub-types of this condition [381]. Tetracyclines are used to treat chronic blepharitis due to their antimicrobial and anti-inflammatory effects and several studies have described the beneficial effects of minocycline and doxycycline [681,683,704]. However, to-date there are no randomized, controlled, double-masked RCTs that demonstrate the efficacy of antibiotics over lid hygiene or other treatments [705,706].

The effects of tetracyclines in patients with MGD have been reported in a case report [707]. A randomized, unmasked prospective controlled study compared different doxycycline doses in 150 patients who had chronic MGD and who did not respond to lid hygiene and topical therapy for more than 2 months [708]. Subjects were randomized into three groups: a high dose group (doxycycline, 200 mg, twice a day), a low dose group (doxycycline, 20 mg, twice a day) and a control group (placebo). After one month, both the high- and low-dose doxycycline groups demonstrated statistically significant improvements in TBUT and symptoms.

A randomized, double-masked, placebo-controlled cross-over study was conducted to investigate the efficacy of low dose doxycycline at 20 mg twice daily to treat clinical symptoms of Sjögren syndrome [709]. Only 5 of the 16 subjects on doxycycline reported significant improvement in their symptoms. Another prospective, randomized unmasked clinical trial consisting of 60 subjects with moderate-to-severe MGD showed that minocycline at the daily dose of 50 mg significantly improved clinical signs of MGD, including TBUT, conjunctival and corneal staining, eyelid appearance and meibum quality, than a control group treated with ocular lubricants [710]. Ocular surface inflammatory mediators including IL-6, IL-1 β , IL-17 α , TNF- α , and IL-12p70 were found to be significantly reduced after two months of treatment [710].

4.4.1.1. Dosage and safety. The optimal dosing schedule of tetracyclines for treating DED has not been established, with a variety of dosing regimens having been proposed. These include 50 or 100 mg doxycycline once a day [711], 200 mg twice daily for 1 month followed by 200 mg daily, or an initial dose of 50 mg a day for the first 2 weeks followed by 100 mg a day for a period of 2.5 months, in an intermittent fashion [681–683,707]. Others have proposed the use of a low dose of doxycycline (20 mg) on a long-term basis [708].

In addition to the known side effects of tetracyclines, which include gastrointestinal symptoms and photosensitivity, safety issues associated with long-term antibiotic therapy have been raised. To minimize risks, a recent study suggested that a three-month course of 100 mg of minocycline might be sufficient to bring significant meibomianitis under control, as continued control was maintained for at least three months after cessation of therapy [707]. Doxycycline (40 mg daily) is the only tetracycline approved

by the FDA for up to 16 weeks in the treatment of rosacea. Long-term doxycycline treatment at this level does not exert antibiotic selection pressure on the microbiota, preventing the development of antibiotic resistance [712,713]. These recommendations may be tempered by reports that, in women, the risk of developing breast cancer and breast cancer morbidity increases cumulatively with duration of antibiotic use, including tetracyclines [714,715], although another study did not substantiate these findings [716]. Additional studies are needed to determine if there are risks with long-term tetracycline use.

4.5. Macrolide therapy

Some reports exist concerning the positive impact of systemic azithromycin in the treatment of MGD, especially in people suffering from intolerance to other systemic antibiotics [717–720]. A recent laboratory-based study compared the effect of azithromycin, doxycycline, minocycline or tetracycline for 5 days on immortalized human meibomian gland epithelial cells [688]. Azithromycin, but not the other antibiotics, significantly increased the cellular accumulation of cholesterol, cholesterol esters, phospholipids, and lysosomes. The authors concluded that the stimulatory effects of azithromycin on human meibomian gland epithelial cell function are unique and not duplicated by the other antibiotics evaluated [688].

Azithromycin can be a valuable option when MGD occurs in association with rosacea [721–723], and it is believed that its anti-inflammatory properties may help control bacterial flora and lid inflammation [706,724–726]. The most common side effects of oral azithromycin are diarrhoea, nausea and vomiting.

The ideal dosage of systemic azithromycin is still controversial and there is no universal agreement. Previous studies have shown efficacy with a daily oral dose of 250 mg or 500 mg for the treatment of rosacea [721,723,727]. A pulse treatment with oral azithromycin for pustular acne has been proposed [728,729], and the same concept appears to be successful for MGD management, using 500 mg per day for 3 days in 3 cycles with 7-day intervals [720]. Further double-masked RCTs must be performed to clarify long-term efficacy and ideal dosing.

Table 12 summarizes several clinical studies investigating the use of both oral and topical azithromycin in the management of DED [720,730–735]. Where available, topical 1% azithromycin is well tolerated and appears to be effective in the management of MGD and evaporative DED, although the low number of well-designed studies still makes this a somewhat controversial therapy. In a recent large scale study by Hosseini and colleagues evaluating 907 subjects with blepharitis, a combination of topical

Table 12
Level 1, 2 and 3 studies of azithromycin for managing dry eye disease.

Author	Subject group	N	Treatment variations	Treatment duration (months)	Reported benefits
Luchs et al., 2008 [730]	Blepharitis	21	Topical 1%	0.5	Improved symptoms and signs
Haque et al., 2010 [731]	Severe blepharitis	26	Topical 1%	1	Improved symptoms and signs
Igami et al., 2011 [720]	Severe blepharitis	13	Oral 500 mg/day for 3 days in 3 cycles with 7-day intervals	1.8	Improved symptoms and signs, tear function
Optiz et al., 2011 [732]	Blepharitis	33	Topical 1%	1	Improved symptoms and signs
Nichols et al., 2012 [733]	Contact lens dry eye	50	Topical 1%	1	Improved symptoms and signs
Fadlallah et al., 2012 [734]	Severe blepharitis	67	Topical 1.5%	3	Improved symptoms and signs
Hosseini et al., 2016 [735]	Blepharitis	907	Topical 0.1% dexamethasone; topical 1% azithromycin; combination of both; vehicle	0.5	Improved symptoms and signs in the combination and 0.1% dexamethasone groups

azithromycin–dexamethasone used for 14 days twice daily was safe and well tolerated [735]. This combination drop achieved complete clinical resolution in a greater percentage of patients (8.2%) than 1% azithromycin (5.2%), 0.1% dexamethasone (5.7%), or vehicle (4.7%).

Whether there is benefit in combining systemic and topical azithromycin to improve the treatment of evaporative DED, especially in the management of refractory or severe cases, requires further study.

To date, two studies have compared the efficacy of doxycycline and azithromycin for the management of MGD [717,736]. A five-day oral azithromycin regimen was compared to one month of doxycycline (200 mg) in one study (Level 2 evidence) [717]. Although both treatments significantly improved clinical scores and symptoms, azithromycin appeared to be more effective in improving clinical signs. In the second Level 2 study, both topical 1% azithromycin for four weeks and twice daily 100 mg oral doxycycline for two months significantly decreased the clinical signs of MGD. Oral doxycycline treatment was slightly less effective in improving foreign body sensation and the signs of plugging and secretion than topical azithromycin [736].

Of note, is a recent report that evaluated the role of oral antibiotics for meibomian gland-related OSD [737]. This review concluded that there is no Level 1 evidence, and only scant evidence overall, to support the use of oral antibiotics in the management of meibomian gland-related OSD.

5. Surgical approaches

5.1. Tarsorrhaphy

Tarsorrhaphy refers to a temporary or permanent surgical procedure in which the eyelids are partially or totally closed using sutures. In addition to temporary closure with sutures, a temporary tarsorrhaphy can also be achieved with adhesive tape, glue or levator paralysis by botulinum toxin injection [738]. Any form of tarsorrhaphy decreases ocular surface exposure, reduces evaporation of the tear film and ultimately results in reduced ocular surface desiccation and drying. The procedure is mainly performed in cases of persistent epithelial defects and reserved for severe dry eye that is refractory to medical treatments and punctal occlusion [499]. Possibly due to the fact that it is normally reserved as the last step when all other treatments have failed, only 20% of patients reported being unhappy with the aesthetic effects [739].

To-date, there are no studies comparing the efficacy of tarsorrhaphy to other treatment modalities in DED.

5.2. Surgical treatment for conjunctivochalasis

Conjunctivochalasis is characterized by loose, redundant, non-edematous inferior bulbar conjunctiva that is located between the globe and the eyelid. This is an age-related ocular disorder, which is often overlooked and negatively impacts quality of life [740]. Conjunctivochalasis is a common finding in dry eye, with a reported prevalence of 54% in individuals with DED [741], and another report suggesting that its presence has a positive predictive value of 93% in the diagnosis of DED [742]. The severity of conjunctivochalasis can be graded by recording the lid-parallel conjunctival folds (LIPCOF) score, with a higher grading positively correlating with more severe dry eye symptoms [743]. The mechanism linking conjunctivochalasis with dry eye symptoms could relate to its impact on the lower TMH [744,745]. Epiphora is also a symptom of conjunctivochalasis, especially when it is located medially, and can be alleviated by correction of conjunctivochalasis [746,747].

In severe cases of conjunctivochalasis that do not respond to

ocular lubricants, topical cyclosporine or punctal occlusion, resection of the excessive conjunctival tissue may be considered [748]. Several approaches to reduce the excessive conjunctival folds have been reported, including electrocoagulation or thermal cauterization [749,750], simple fixation to the sclera [751], and Argon laser conjunctivoplasty [752]. In all studies (Level 3 evidence), some level of improvement in symptoms has been reported in over 75% of patients.

5.3. Essential blepharospasm treatment with botulinum neurotoxin

Essential blepharospasm (EB) is a focal cranial dystonia involving the eyelid and forehead muscles. It has been reported that 40–60% of EB patients have dry eye symptoms and decreased Schirmer scores [753–756]. Additionally, pro-inflammatory cytokine levels in the tear fluid are also increased in dry eye patients with EB, compared to those with only DED [757].

Botulinum toxin A injection for the management of EB causes a temporary pharmacologic denervation of the orbicularis oculi muscle. Several case-control studies (Level 2 evidence) report amelioration of dry eye symptoms and an increase in TMH, TBUT and tear clearance time after botulinum toxin A injection [757–759]. However, these effects last for only 3 months [760]. In contrast, tear production can possibly be impaired by botulinum toxin A injections that occur too close to the lacrimal gland [753,761,762].

5.4. Lid corrections

5.4.1. Dermatochalasis

Dermatochalasis is a term used to describe the presence of loose and redundant eyelid skin and is a common sign of aging. Based on Level 2 and 3 evidence, 46–51% of patients with dermatochalasis have dry eye complaints and 55–86% of patients achieve subjective improvement in symptoms after upper eyelid blepharoplasty [763,764]. However, objective parameters have not been shown to change significantly after blepharoplasty [764], and the reported improvements may be purely psychological.

5.4.2. Blepharoptosis (ptosis)

Dry eye disease can be a risk factor for blepharoptosis, as it causes increased friction between the upper lid and the ocular surface, which may contribute to disinsertion or thinning of the levator aponeurosis. A prospective case-control study (Level 2 evidence) showed that a low Schirmer score occurs more often in patients with acquired aponeurogenic ptosis than in controls [765].

Despite surgical correction of ptosis, tear quality can continue to deteriorate. In an interventional case series, Schirmer scores and TBUT revealed a decrease in tear quantity and quality after surgery [766]. Tear volume may also decrease after ptosis surgery [767,768].

5.4.3. Lower lid blepharoplasty

Lower lid laxity and ectropion are common occurrences with increasing age and are most commonly treated with transcutaneous lower lid blepharoplasty. However, even after apparently successful surgery, patients often complain of dryness, epiphora and chemosis postoperatively [769–771].

Dry eye disease is one of the most common complications after any kind of eyelid surgery [102], with the exception of tarsorrhaphy [772]. Common causes of postoperative dry eye include chemosis, increased exposure of the ocular surface, lagophthalmos, lower eyelid malposition, or diminished blink reflex from surgical anesthesia or oedema [102,483]. These are described in more detail in the TFOS DEWS II Iatrogenic Dry Eye and Pathophysiology Reports.

5.5. Conjunctival surgery and amniotic membrane grafts

Individuals with conjunctival disorders such as pterygium, pingueculae, Stevens-Johnson syndrome, and mucous membrane pemphigoid often develop DED. Advanced pterygium results in an uneven distribution and focal evaporation of tears over the ocular surface, aggravating dry eye symptoms. Dry eye patients with severe ocular surface inflammation and cicatrization could benefit from surgical treatment with conjunctival reconstruction, as well as removal of the inflamed tissues and activated fibroblasts [773–775]. However, in patients with mucous membrane pemphigoid, any ocular surface and eyelid surgery should be performed after the disease is adequately controlled by systemic immunosuppression to avoid exacerbation of the disease. Conjunctival or limbal autograft reduces pterygium recurrence compared to bare sclera excision and amniotic membrane transplantation, and has become a standard treatment [776]. Concurrent application of mitomycin C application further reduces the risk of recurrence, however this is associated with potentially serious complications such as scleral thinning, ulceration, and delayed conjunctival epithelialization [777].

Severe DED can lead to persistent epithelial defects, corneal ulceration and corneal scarring. Amniotic membrane grafts could be considered for persistent epithelial defects in cases of ocular cicatricial pemphigoid, Stevens-Johnson syndrome and other severe OSD [499,775,778–782]. These membranes contain a wide variety of neuropeptides and neurotransmitters, including acetylcholine and catecholamine [783–787].

A particular form of amniotic membrane transplant is the PROKERA[®] and thinner PROKERA[®] SLIM (Bio-TissueDoral, FL, USA). These devices contain human amniotic membrane processed with a form of cryopreservation that retains the tissue's biological activity. The membrane is contained within a thermoplastic ring that permits the device to be inserted in a similar manner to a scleral lens and holds the tissue firmly in place. The grafts typically dissolve in approximately one week and the conformer ring can then be removed [788]. To date, only a few case studies have been published on its use [782,789,790]. One study did show sustained symptom improvement for four months in dry eye subjects who wore the PROKERA[®] SLIM for approximately five days on average [782]. The authors also reported reduced corneal and conjunctival staining and improved visual acuity.

5.6. Mechanical dacryoreservoirs

In severe DED, individuals with Schirmer scores of ≤ 1 mm may require the application of lubricating drops every few minutes, which seriously disrupts daytime activities and results in a marked reduction in quality of life. In these cases, mechanical devices that deliver lubricating drops from a reservoir through a catheter have been used to continuously lubricate the ocular surface. A rabbit study showed that a microinfusion pump, originally developed for insulin treatment in diabetics, was able to deliver a dose of artificial tears that was similar to that found in normal eyes [791]. In addition, eyes treated with corticosteroid delivered by this pump recovered faster than those treated with topical corticosteroid.

In a prospective, non-randomized trial of 21 subjects with a Schirmer score of ≤ 1 mm, a 60 ml reservoir was implanted under the subcutaneous tissues of the anterior abdominal wall and connected to a silicone catheter that ascended subcutaneously along the chest, neck and temple to the upper conjunctival fornix [792,793]. All subjects reported an improvement in symptoms and exhibited prolonged TBUT with a reduction in corneal staining and conjunctival hyperemia. Infections of the reservoir or the catheter, although not reported in this study, can occur, and may require

explantation of the device.

While rare, it is clear that mechanical dacryoreservoirs may be a valuable option in cases of very severe aqueous tear deficiency, where all other less invasive measures have failed to achieve sufficient subjective relief.

5.7. Major salivary gland transplantation

The aim of salivary gland transplantation is to provide some functioning exocrine tissue to a severely dry eye. Possible indications can include primary (congenital) alacrimia or severe aqueous deficiency secondary to cicatricial conjunctivitis (due to mucous membrane pemphigoid, Stevens-Johnson syndrome, chemical burns), surgical damage or radioablation of lacrimal tissue (such as that found in neoplastic disease of the head). Having a functional salivary gland will, in addition to being a constant source of lubrication, also provide epitheliotropic factors that are also present and functionally relevant in the tears [794].

The three major salivary glands, the parotid, submandibular and sublingual gland, have all been used to lubricate the ocular surface, although the approach of transplanting a sublingual gland to the subconjunctival space has failed to succeed, due to ischemia of the grafted tissue [795]. For the parotid gland and the submandibular gland the surgical approaches are entirely different and both require the expertise of an experienced oral surgeon.

5.7.1. Parotid duct transposition

In this procedure, the secretory duct of the parotid gland is moved from its original premolar position in the mouth to the lower conjunctival fornix [796]. Since the innervation of the gland is maintained, a gustatory reflex epiphora of a purely serous secretion results. Evidence for its success is limited to retrospective case reports or series without quantitative follow-up data. Complications include blepharitis and keratitis from excessive secretion, for which measures such as systemic anticholinergics or parasympathetic denervation of the gland were found to be either impracticable or ineffective and this technique seems to have been abandoned [797].

5.7.2. Microvascular submandibular gland transplantation

A free partial or total submandibular gland with a vascular pedicle and the secretory duct are transferred to the temple. A microvascular anastomosis with facial vessels is created and the duct sutured into the conjunctival fornix [798,799]. While the procedure requires several hours of general anesthesia, it offers some major advantages over other procedures using salivary gland tissue, including (i) an established blood supply to ensure the glands' viability, (ii) a secretion capable of replacing the mucous and serous component of the tear film, (iii) absence of reflex salivation due to intraoperative sympathetic denervation of the graft and (iv) a maintained baseline secretion due to surviving parasympathetic intraglandular ganglion cells [800].

In rats and rabbits, transplanted submandibular glands remained viable and active for at least six months post transplantation [801,802]. Several groups have published clinical results in subjects with severe aqueous deficiency [798,799,803–807]. Despite the potential for microvascular complications, a reported 66–100% remained viable for at least five years, according to clinical ophthalmological examination or scintigraphy [808]. Allogeneic grafts require long-term immunosuppression [809]. Most reports come from maxillofacial or ear, nose and throat surgeons and often have only limited data on specific ocular surface findings. The most systematic evaluation to-date is a prospective, controlled case series with a follow-up of more than 40 months [805,807]. The results showed a substantial improvement in Schirmer score, TBUT,

use of tear substitutes and symptoms compared to controls (fellow eyes without a viable submandibular gland graft) from three months through to the end of follow-up. Neither visual acuity (probably due to pre-existing corneal scarring and other comorbidities) nor conjunctival inflammation or squamous metaplasia improved [807].

When comparing total versus partial submandibular glands transplantation, Qin and coworkers reported severe epiphora in 19 out of 22 patients with a total submandibular gland graft, versus 6 out of 20 eyes with a partial transplant [799]. Secretion from the gland was stimulated by heat or physical activity and could be blocked by anticholinergics [799,805,810,811]. Hypersecretion can also be controlled surgically by reducing the size of the gland or by partial ligation of the duct [805,812].

While the resulting lubrication contains many proteins and other components abundant in tears, it is very hypo-osmolar compared to tears and this hypo-osmolarity can induce microcystic epithelial oedema in cases with oversecreting transplants [190,794,807,813]. As a consequence, 100% of five corneal transplants performed following submandibular gland transplantation failed, due to rejection, infection, calcification or epiphora-associated epithelial oedema, with subsequent corneal perforation [807].

In summary, the submandibular gland is the only major salivary gland that is currently being used to supply lubrication to the eye by means of transplantation. It is only indicated in patients with absolute aqueous tear deficiency with persistent severe discomfort and when all other means have failed. These patients benefit from substantial relief of severe symptoms and some signs of dry eye, but the procedure does not enable successful visual rehabilitation.

5.8. Minor salivary gland autotransplantation

Oral and nasal mucosa can be used to reconstruct the fornices and to provide mucin to the ocular surface, but this procedure fails to provide sufficient lubrication to sustain a healthy corneal graft [814,815]. Labial mucosa (which lines the lips) has been used as a complex graft to the conjunctival fornix in severe dry eyes, with excellent success in terms of graft viability [795,797]. The secretion of the minor salivary glands is predominantly mucinous, with the buccal salivary glands showing the highest flow rate [816]. Transplantation resulted in an increase in Schirmer test score and TBUT and also provided symptomatic relief [817].

Marinho reported results of 14 and Sant' Anna, of 19 patients with severe DED secondary to Stevens-Johnson syndrome who had labial salivary gland transplantation [817,818]. Up to 14 months postoperatively, tear volume was improved in over 70% of patients. Corneal transparency and visual acuity improved in 72% and symptoms decreased in 54% and 100% respectively. Potential complications include temporal labial hypoesthesia or graft necrosis, the feeling of "watery" eyes or bulkiness and laxity of the eyelids leading to entropion, as well as donor site morbidity.

6. Dietary modifications

There is growing evidence that diet and nutritional supplementation play a role in DED. The contributions of general hydration status, and other interventions, such as lactoferrin and anti-oxidant supplementation, are also worthy of consideration.

6.1. General hydration state

Whole-body hydration status has been proposed to have a potential role in DED control. Tear osmolarity levels in healthy adults increase as a result of modest whole-body dehydration (2–3% body

mass loss) during exercise [819,820], an effect that is modifiable with fluid intake [819]. Observational data suggest that whole-body hydration status may also directly influence the clinical expression of DED. In a cross-sectional study of 111 participants aged at least 60 years, individuals classified as having DED were found to have higher plasma osmolality, indicating sub-optimal hydration, than individuals without DED [821]. Whether improving whole body hydration with fluid intervention confers a therapeutic benefit in people with DED requires further study. Specifically, there remains the need for controlled intervention trials to assess the efficacy and safety of optimizing hydration status as a non-drug therapy for DED.

6.2. Essential fatty acids

Essential fatty acids (EFAs) are termed 'essential' as they are necessary for healthy metabolic processes to occur [822]. Humans are unable to form EFAs *in vivo* and must ingest them from dietary sources. Two key EFAs are the 18-carbon omega-3 (ω -3) and omega-6 (ω -6) fatty acids. The ω -3 EFAs exist as both short (alpha-linolenic acid, ALA) and long-chain (eicosapentaenoic acid, EPA and docosahexaenoic acid, DHA) sub-types. Both subtypes can be consumed from food, with long-chain forms also capable of being produced from short-chain forms within the body, through the desaturation/elongation of short-chain EFAs. Common food sources for ALA include flaxseeds, walnuts, chia seeds and soybean oil. The long-chain ω -3 polyunsaturated fatty acids (PUFAs), EPA and DHA, are present in high concentrations in oily fish (such as tuna, salmon, trout, sardines and mackerel) and to a lesser extent in shellfish (such as prawns, oysters and mussels). The ω -6 EFAs are commonly derived from vegetable oils, such as safflower oil and corn oil, in the form of linolenic acid (LA), which, once ingested, is desaturated and elongated to gamma-linoleic acid (GLA) and arachidonic acid (AA) [823].

Within the body, ω -3 and ω -6 EFAs compete for the enzymes that regulate their metabolism, to produce eicosanoids that modulate systemic inflammation. Eicosanoids derived from the ω -6, AA-dependent pathway, including prostaglandin-E2 (PGE2), thromboxane-A2 and leukotriene-B4, are pro-inflammatory. While most ω -6 eicosanoids promote inflammation [824], metabolism of GLA can result in the production of prostaglandin-E1 (PGE1) and thromboxane-A1, which are anti-inflammatory mediators [824]. The potential effect(s) of ω -6 EFAs on inflammation is therefore complex. Long-chain ω -3 EFAs bias prostaglandin metabolism towards the production of anti-inflammatory eicosanoids, including resolvins and protectins, which are essential for limiting and resolving inflammation [825]. As such, the relative ratio of consumed ω -3 to ω -6 EFAs influences the overall inflammatory status of the body [824].

In modern times, the balance of ω -3 to ω -6 essential fatty acids (EFA) dietary intake has shifted, thereby altering the balance of inflammatory cytokines [826]. In current Western diets, the ratio of ω -6: ω -3 intake is typically 15:1, whereas an ideal ratio is generally considered to be 4:1 [827]. As a result, there has been scientific interest in understanding whether increasing systemic ω -3 EFA levels through nutritional intervention, to lower the ω -6: ω -3 ratio, can yield systemic anti-inflammatory effects that are beneficial for conditions with an inflammatory overlay, including DED.

6.2.1. Basic science studies

Omega-3 EFAs are recognized to have a broad range of systemic anti-inflammatory effects, including inhibiting the production of several key pro-inflammatory cytokines (such as IL-1, IL-2 and TNF- α) [828–830] and preventing T-lymphocyte proliferation [831,832], processes that have been implicated in the pathogenesis of DED.

Several laboratory studies have shown that fatty acid enrichment can impart lacrimal gland changes and alter the ocular surface response to pharmacologic-induced models of DED [833–838]. Two recent laboratory-based studies have evaluated the impact of EFAs on the function of human meibomian gland epithelial cells [833,834]. The study by Liu et al. showed that EFAs influence the quality and quantity of intracellular lipids, resulting in a 2.4- to 3.7-fold increase in the cellular content of triglycerides after ω -3 and ω -6 treatment, respectively. In rats, dietary supplementation with ω -3 (EPA + DHA) for three months was associated with their incorporation into lacrimal gland tissues [835]. Two-month dietary enrichment with combined ω -3 (EPA + DHA) and ω -6 (GLA) PUFAs, reduced corneal keratitis, minimized the overexpression of conjunctival major histocompatibility complex (MHC) II and inhibited upregulation of prostaglandin (PG) E1 and PGE2 in the lacrimal gland, after 28 days of scopolamine intervention [836]. In murine DED models, topical formulations of ω -3 EFAs have been shown to reduce levels of corneal fluorescein staining [837,838], and decrease both CD11b (+) cell numbers and conjunctival expression of IL-1 α and TNF- α [837]. Topical ω -3 EFAs, with and without added 0.1% HA, have also been found to improve corneal irregularity and reduce epithelial barrier disruption [838].

Experimental evidence supports the therapeutic potential of a class of endogenous lipid-derived immunomodulators, resolvins, derived from EPA (resolvin E1) and DHA (resolvin D1), as an anti-inflammatory treatment for DED [14,839,840]. Resolvins E1 and D1 promote the resolution of inflammation in cultured conjunctival goblet cells by reducing cysteinyl leukotrienes [839,840]. In murine DED models, resolvin E1 has been reported to increase tear production, improve corneal regularity and decrease macrophage infiltration [841], and to reduce corneal epithelial barrier disruption and attenuate conjunctival goblet cell loss [842]. Topical application of a prodrug of resolvin E1, RX-10045 (0.1%), which is rapidly hydrolyzed to its active form in biological matrices, can reduce corneal stromal haze after rabbit corneal injury [843]. In a recent clinical study RX-10045 failed to meet a primary endpoint related to corneal staining [329]. While investigations involving resolvin D1 are less prevalent, it should be noted that these agents have a role in corneal health. For example, a derivative of DHA, NPD₁, is important in nerve regeneration and corneal sensitivity [844,845].

6.2.2. Human observational data

The Women's Health Study, involving over 32,000 women, described an association between a low dietary intake of ω -3 EFAs and DED in women [846]. This study reported a 30% reduction in the risk of DED with each additional gram of ω -3 EFAs consumed per day. A higher ratio of dietary ω -6: ω -3s was also associated with an elevated risk of DED (for $\geq 15:1$ versus $<4:1$, odds ratio: 2.51; 95% CI: 1.13, 5.58, $p = 0.01$). Furthermore, it has been recently shown that the ratio of ω -6: ω -3 tear lipids is elevated in people with DED and that this occurs in proportion to the degree of tear film dysfunction and corneal staining [847]. The level of dietary ω -3 EFA intake is also associated with differences in the polar lipid pattern of meibomian gland secretions in women with Sjögren syndrome [848].

6.2.3. Clinical trials of EFA supplements

Clinical trials have been undertaken to assess the potential benefit of oral ω -3 and ω -6 EFA supplementation, both alone and in combination, for treating DED. Most of these intervention trials have been performed at single sites and with relatively small participant numbers (sample size <70). The clinical trials have had varying degrees of masking, of both participants and outcome assessors, with few being double-masked.

All of the clinical trials evaluating ω -3 EFAs alone (Table 13)

[849–859] have been undertaken for three months or less, with the exception of one pilot study that investigated the efficacy of short-chain ω -3 EFAs (ALA) for treating MGD and blepharitis over 12 months [849]. The ω -3 EFA interventions have varied both in terms of subtype (short- and/or long-chain formulations) and dose. To date, only one study has evaluated the relative efficacy of different forms of long-chain ω -3 EFAs for treating DED, comparing krill oil, in primarily phospholipid form, to fish oil, in triacylglyceride form [858]. This randomized, placebo-controlled clinical trial suggested that ω -3 EFAs in phospholipid form (krill oil) might confer additional therapeutic benefit in DED, with further clinical investigations needed to assess this potential. A variety of outcome measures have been examined, primarily involving quantifying changes to patient symptomatology and objective clinical measures relating to tear stability and/or production. More recently, beneficial effects with oral ω -3 EFA supplements in DED have also been demonstrated, with the specification of tear osmolarity as a primary outcome measure [858,859]. A recent pilot study has further demonstrated central corneal neuroprotective effects with a three-month supplementation of a moderate dose of ω -3s (1000 mg/day EPA + 500 mg/day DHA) in DED [860]. Attempting to summarize the best available evidence, a meta-analysis concluded that ω -3 EFA supplementation improves TBUT and Schirmer scores in individuals with DED, without significantly altering OSDI scores [861].

Although many patients self-medicate with ω -3 EFA supplements on the premise of their well-publicized health benefits, use of these supplements requires some precautions. There are several important systemic contra-indications, including liver disease, atrial fibrillation and bleeding disorders; in these cases, medical advice should be sought prior to commencing supplementation. There may be potential risks to health with high-dose ω -3 EFA intake (>2000 mg/day combined EPA + DHA), in terms of a heightened risk of bleeding [862], and people with hematological disorders should seek medical advice before consuming ω -3 EFA supplements [863]. The possibility that males with high serum concentrations of long-chain ω -3 PUFAs have a heightened risk of prostate cancer has also been raised [864], but remains contentious [865,866]. Both the FDA and the National Health and Medical Research Council (NHMRC) in Australia recommend an upper daily limit for omega-3 fatty acid consumption of 3 g (3000 mg); this includes omega-3 fatty acids derived both from food and supplements. It is important to note that this dosage relates to the amount of omega-3 fatty acid content, rather than the size of the supplement capsule *per se*. For example, many 1 g (1000 mg) fish oil capsules contain 180 mg EPA + 120 mg DHA; thus only about 30% of the content of the fish oil supplement capsule will be long-chain omega-3 fatty acids.

Interventional clinical trials that have evaluated ω -6 EFA formulations for treating DED have been performed at single-sites, ranging in duration from three weeks to six months, and with considerable variations in daily dose (Table 14) [867–871]. Most studies targeted study populations with Sjögren syndrome, with variable outcomes reported in relation to changes in dry eye symptoms, ocular inflammatory markers and other clinical signs (such as ocular surface staining, TBUT, Schirmer score).

Clinical trials that investigated supplementation with combined ω -3 and ω -6 EFAs have ranged in duration from three to six months and include both single-site and multi-center studies (Table 15) [872–877]. A 2014 meta-analysis that considered the overall efficacy of PUFA supplementation for treating DED concluded that, compared with placebo, these interventions resulted in a significant reduction in both symptom score (quantified using the OSDI) and in the rate of cells positive for HLA-DR [878]. A Cochrane systematic review protocol on this topic was also published in 2014 and is currently in progress [879].

Table 13Major published intervention clinical trials of oral ω -3 EFA supplementation for dry eye disease.

Author, Year	N	Study period	Oral ω -3 intervention (daily dose)	Control	Evidence level	Parameters with significant improvements relative to control ^g	Parameters without significant effect relative to control ^g
Macsai, 2008 [849].	38 ^f	12 months	Flaxseed oil 3300 mg	Placebo (olive oil)	1	Primary: Symptoms (OSDI)	Secondary: TBUT, meibum scores, Schirmer score, corneal staining.
Wojtowicz et al., 2011 [850]	36	90 days	EPA 450 mg + DHA 300 mg + flaxseed oil 100 mg	Placebo (wheatgerm oil)	1 ^e	Symptoms (OSDI)	Schirmer score, evaporimetry, lipid composition of MG secretions, TBUT
Bhargava et al., 2013 [851]	518	3 months	EPA 650 mg + DHA 350 mg	Placebo (corn oil)	1	Symptoms, TBUT and Schirmer score	Rose bengal staining and conjunctival impression cytology
Olenik et al., 2013 [852]	61 ^b	3 months	EPA 127.5 mg + DHA 1050 mg ^c	Placebo ^c (sunflower oil)	1	Symptoms (OSDI), TBUT, lid margin inflammation, MG expression and Schirmer score	None
Kawakita et al., 2013 [853]	27	12 weeks	EPA 1245 mg + DHA 540 mg	Placebo (middle chain triglycerides)	1	Symptoms and TBUT	Schirmer score, ocular surface fluorescein or rose bengal staining
Kangari et al., 2013 [854]	64	30 days	EPA 360 mg + DHA 240 mg	Placebo (middle chain triglycerides)	1	Primary: TBUT Secondary: Symptoms (OSDI) and Schirmer score	None
Pinazo-Duran et al., 2013 [855]	66 ^d	3 months	EPA 85 mg + DHA 700 mg + 60 mg DPA + antioxidant	None (open-label)	2	Not applicable	Reduced inflammatory tear cytokines (relative to baseline only)
Olenik, 2014 [856]	905	12 weeks	EPA 127.5 mg + DHA 1050 mg + DPA 90 mg	None (open-label)	2	Not applicable	Symptoms ^a (relative to baseline only)
Bhargava, 2015 [857]	256	45 days	EPA 720 mg + DHA 480 mg	Placebo (olive oil)	1	Primary: Symptoms. Secondary: TBUT and conjunctival cytology	Secondary: Schirmer score
Deinema et al., 2017 [858]	60	90 days	Krill oil (EPA 945 mg + DHA 510 mg) and Fish oil (EPA 1000 mg + DHA 500 mg)	Placebo (olive oil)	1	Primary: Tear osmolarity and symptoms (OSDI). Secondary: TBUT, Ocular bulbar redness, tear levels of the pro-inflammatory cytokine IL-17A.	Secondary: NIBUT, Schirmer score, TMH, levels of other tear cytokines IL-2, IL-4, IL-6, IL-10, IFN-gamma, TNF-alpha.
Epitropoulos et al., 2016 [859]	105	12 weeks	EPA 1680 mg + DHA 560 mg re-esterified ω -3 EFAs	Safflower oil (3136 mg)	1	Primary: Tear osmolarity. Secondary: TBUT, Symptoms (OSDI), MMP-9 positivity.	Secondary: Corneal fluorescein staining, Schirmer test.

DHA - docosahexaenoic acid; DPA - docosapentaenoic acid; EPA - eicosapentaenoic acid; IFN - interferon; IL - interleukin; MG - meibomian gland; MMP-9 - matrix metalloproteinase-9; N - number of subjects; NIBUT - non-invasive tear break up time; OSDI - ocular surface disease index; TBUT - tear break up time; TMH, tear meniscus height; TNF - tumor necrosis factor.

^a No objective clinical measurements were evaluated.

^b Study population involved only individuals with MGD.

^c Both the intervention and control groups were instructed to also undertake eyelid hygiene and use non-preserved artificial tears, each day, throughout the study.

^d Study population involved both individuals with DED (n = 30) and healthy controls (n = 36).

^e Double-masked, randomized controlled pilot study, which was inadequately powered to detect significant differences between the study groups.

^f Study population involved individuals with MGD and blepharitis.

^g Primary and secondary outcomes are specified when defined by the authors.

6.2.4. Summary of essential fatty acids

The role of ω -3 and/or ω -6 EFA supplementation for treating DED is not yet completely understood. Although a sizeable number of clinical trials have been conducted (Tables 13–15), most have been of short duration and show contrasting findings. There are few high-quality, randomized controlled clinical trials to inform practice. As a result, there is currently a lack of consensus in relation to the optimal protocol, in particular to the dose, composition or duration of treatment. Furthermore, most clinical studies have not measured compliance to the study interventions with blood serum fatty acid assays. This is considered essential to precisely assess the health effects of supplementation, particularly as common sources of ω -3 EFAs (such as fish oil supplements) have potential gastrointestinal side effects that include fishy after-taste and diarrhoea, which can negatively impact compliance [880]. A large-scale, multi-center, randomized, placebo-controlled trial (DREAM study) assessing the efficacy and safety of ω -3 PUFAs (dosed at 2000 mg EPA + 1000 mg DHA/day) over 24 months, funded by the National Institute of Health, is currently underway (<https://clinicaltrials.gov>

[ct2/show/NCT02128763](https://clinicaltrials.gov/ct2/show/NCT02128763)). This study is predicted to inform treatment recommendations for using high-dose ω -3 PUFAs for treating DED.

6.3. Lactoferrin

Lactoferrin is a multifunctional tear glycoprotein with anti-bacterial, anti-inflammatory and anti-angiogenic properties. Tear lactoferrin levels are considered an indicator of lacrimal secretory function [881]. Reduced tear lactoferrin levels have been reported in a number of clinical populations with DED [881–886], providing scientific rationale to evaluate the potential benefit of dietary supplementation with lactoferrin as a dry eye intervention. Oral lactoferrin preserves lacrimal gland function in aged mice by reducing oxidative damage and suppressing gland inflammation [887]. In a pilot study of seven individuals with Sjögren syndrome, oral lactoferrin supplementation (270 mg/day) for one month, improved dry eye symptoms, TBUT, ocular surface vital staining scores, corneal sensitivity and impression cytology scores, with

Table 14
Major published interventional clinical trials of oral ω -6 EFA supplementation for dry eye disease.

Author, Year	N	Study period	Oral ω -6 intervention (daily dose)	Control	Evidence level	Parameters with significant improvements relative to control ^f	Parameters without significant effect relative to control ^f
Manthorpe et al., 1984 [867]	36 ^c	3 weeks	<i>cis</i> -linoleic acid 365 mg + GLA 45 mg	Placebo	1	Schirmer test score	TBUT, lissamine green staining, tear lysozyme and corneal sensitivity
Oxholm et al., 1986 [868]	28 ^c	8 weeks	<i>cis</i> -linoleic acid 2190 mg + GLA 270 mg	Placebo	1	None	No improvements in Schirmer score, TBUT or lissamine green staining
Theander et al., 2002 [869]	90 ^c	6 months	Two doses tested: (1) GLA 800 mg; (2) GLA 1600 mg	Placebo (corn oil)	1	None.	No improvements with either dose for eye pain, dry eye symptoms, Schirmer test or lissamine green staining
Barabino et al., 2003 [872]	26 ^d	45 days	LA 57 mg + GLA 30 mg ^e	Placebo ^e	1	Symptoms, reduced conjunctival HLA-DR expression and lissamine green staining.	TBUT, Schirmer test score
Aragona et al., 2005 [870]	40 ^c	1 month	LA 112 mg + GLA 15 mg	Placebo (fructose)	1	Symptoms, increased levels of tear PGE1 and CFS	TBUT, tear basal secretion
Pinna et al., 2007 [871]	57 ^a	6 months	LA 28.5 mg + GLA 15 mg	None	2 ^b	Not applicable	Symptoms, MG secretion turbidity and MG obstruction (relative to baseline only)

CFS – corneal fluorescein staining; GLA - gamma-linolenic acid; HLA-DR - human leukocyte antigen D-related; LA - linolenic acid; N - number of subjects; PGE1 - prostaglandin E1; TBUT - tear break up time.

^a Study population involved only individuals with MGD.

^b Investigator-masked only.

^c Study population involved only individuals with primary Sjögren syndrome.

^d Study population involved only individuals with aqueous-deficient DED.

^e Both the intervention and control groups were instructed to use non-preserved artificial tears, each day, throughout the study.

^f Primary and secondary outcomes are specified when defined by the authors.

reversal of improvement upon treatment cessation [888]. A recent single-center, prospective, randomized, controlled clinical trial reported improvement in dry eye symptoms, TBUT and Schirmer scores, relative to placebo, with daily oral lactoferrin post-operatively for two months (350 mg/day) following small incision cataract surgery [889]. Further research is necessary to clarify the role of lactoferrin supplementation for treating DED.

6.4. Other dietary considerations

Oxidative stress, which generates cell-damaging reactive oxygen species, may be involved in the cellular injury that leads to OSD, including dry eye [890]. In a crossover, placebo-controlled, randomized trial involving an orally-administered antioxidant supplement (containing beta-carotene, vitamins E, C, B, B6, D,

Table 15
Major published intervention clinical trials of combined oral ω -3 and ω -6 EFA supplementation for dry eye disease.

Author, Year	N	Study period	Oral ω -6 intervention (daily dose)	Control	Evidence level	Parameters with significant improvements relative to control ^a	Parameters without significant effect relative to control ^a
Creuzot et al., 2006 [873]	71	6 months	EPA 28 mg + DHA 392 mg + GLA 82 mg + LA 126 mg	Placebo (basic oleic acid)	1 ^b	Reflex tearing and bulbar hyperemia	Schirmer score, TBUT, ocular surface fluorescein and lissamine green staining
Larmo et al., 2010 [874]	86 ^c	3 months	Sea buckthorn oil (2 g); long chain ω -3 EFAs 149 mg + ω -6 triglycerides 245 mg	Placebo (medium-chain triglycerides)	1	Bulbar redness and ocular burning	Tear osmolarity, Schirmer score, TBUT
Brignole-Baudouin et al., 2011 [875]	106	3 months	EPA 427.5 mg + DHA 285 mg + borage oil 15 mg + zinc 10 mg + vitamins	Placebo (medium-chain triglycerides)	1	Reduction in percentage of conjunctival HLA-DR positive cells.	Schirmer score, TBUT and ocular surface staining
Jackson et al., 2011 [876]	43	6 months	ALA 1000 mg + GLA 500 mg	ALA 1000 mg + GLA 500 mg + topical cyclosporine 2 \times daily for the last 3 months	2 ^d	Not applicable	Both groups showed improvements in symptoms and TBUT relative to baseline only
Creuzot-Garcher et al., 2011 [877]	181	6 months	EPA 28 mg + DHA 392 mg + GLA 82 mg + LA 126 mg	Placebo (basic oleic acid)	1	TBUT, reduced ocular fatigue score	Schirmer score, ocular surface staining.
Sheppard et al., 2013 [878]	38 ^c	6 months	ALA 196 mg + EPA 128 mg + DHA 99 mg + DPA 39 mg + LA 710 mg + GLA 240 mg	Placebo (sunflower oil)	1	Symptoms (OSDI), corneal surface asymmetry index and conjunctival HLA-DR expression	TBUT, conjunctival fluorescein and lissamine green staining, Schirmer score.

ALA - alpha-linolenic acid; DHA - docosahexaenoic acid; DPA - docosapentaenoic acid; EFAs – essential fatty acids; EPA - eicosapentaenoic acid; GLA - gamma-linolenic acid; HLA-DR - human leukocyte antigen D-related; LA - linolenic acid; OSDI – ocular surface disease index; N - number of subjects; TBUT - tear break up time.

^a Primary and secondary outcomes are specified when defined by the authors.

^b Masking procedures are unclear.

^c Both intervention and control groups included contact lens wearers.

^d Neither clinical outcome assessors or participants were masked (open-label study).

^e Study population involved only post-menopausal women.

zinc and copper) in individuals with marginal DED, relative improvements in tear stability, goblet cell density and squamous metaplasia were demonstrated at the one-month study endpoint [891]. Another small randomized, controlled clinical trial of a combination antioxidant and mineral (zinc) oral supplement reported improvements in TBUT and Schirmer scores, as well as reduced ocular symptoms in people with DED, compared with placebo over 12 weeks [892]. An open-label, non-controlled pilot trial involving 13 subjects with DED showed that daily oral antioxidant supplementation, with *Aristotelia chilensis* berry extract (30 mg), resulted in relative improvements in dry eye symptoms and Schirmer scores, compared with baseline, over two months [893].

Alpha-lipoic acid, a naturally occurring disulfide compound, also has anti-oxidant capacity [894]. In an animal model of post-menopausal dry eye, dietary supplementation with alpha-lipoic acid for 16 weeks was found to increase the activity of lacrimal peroxidase and improve lacrimal production [895]. Whether alpha-lipoic has clinical application in DED in humans remains to be investigated.

Kawashima and colleagues showed that calorie restriction preserves lacrimal gland function by attenuating oxidative damage in the lacrimal gland, suggesting that dietary changes and a reduction in calorific intake may prove beneficial in the management of dry eye [896]. More recent work from the same group in both a rat dry eye model and human clinical trial has shown the short-term value of dietary changes on dry eye signs and symptoms [897]. A recent cross-sectional single-visit study also supported the notion that increased body fat may result in an increase in dry eye symptoms [898]. Alcohol intake induces transient dry eye in healthy individuals [899], suggesting that its consumption may aggravate symptoms and signs of dry eye.

Recently, the use of spectacles containing extracts of four medicinal plants with reported antioxidant and anti-inflammatory properties, three times daily for eight weeks, was described to improve both subjective and objective signs of dry eye, compared with a placebo intervention, in individuals with mild DED [900]. Findings from these preliminary investigations require confirmation in sufficiently large, appropriately controlled, multi-center clinical trials.

7. Local environmental considerations

Several “environmental” factors have been implicated in DED, including systemic and topical medications, desiccating conditions, digital device use and contact lens wear [102]. Consideration of these risk factors is important because this information can provide additional information on a patient's individual response to prescribed therapy.

Modification to any relevant environmental issues are potentially useful early management options, as any initial ocular surface changes culminating in DED may be prevented or potentially reversed by removing the associated environmental risk factors.

7.1. Chronic topical medications

A number of studies have shown that preservatives may be associated with allergic, toxic or inflammatory reactions, particularly in patients using topical medications on a long-term basis. Preservatives such as BAK irritate the ocular surface [98], and both symptoms (such as burning, dryness and foreign body sensation) and signs are significantly more frequent in patients using preserved glaucoma medications [901,902]. Several studies have suggested that glaucoma medications may contribute to OSD and the development of dry eye [903,904], and the severity of OSD has been

correlated with the number of preserved medications in use and with glaucoma disease severity [905–907].

Two large multicenter European clinical trials showed that changing to preservative-free (PF) glaucoma medications resulted in patients experiencing significantly fewer signs and symptoms of OSD [901,902]. The PF medications available for glaucoma therapy include prostaglandin analogues (PGAs), tafluprost PF, beta-blockers, timolol maleate PF and a fixed dose combination in the form of dorzolamide/timolol PF. Preservative-free timolol has been available for several years in the USA and Europe and has fewer negative effects on OSD symptoms, signs and tear function tests [908]. Ciancaglini et al. undertook confocal microscopy of the conjunctiva and performed impression cytology to demonstrate that the use of unpreserved levobunolol was associated with fewer conjunctival changes [909]. Renieri et al. reported a crossover clinical trial of 2298 subjects switching from various BAK-preserved therapies to preservative-free dorzolamide/timolol and found improved local tolerability in 80% of the patients [910]. Uusitalo et al. switched 158 patients from BAK-preserved latanoprost to preservative-free tafluprost for 3 months [911]. They found significant decreases in symptoms, corneal fluorescein staining, conjunctival hyperemia, abnormal conjunctival cells (based on HLA-DR and MUC5AC) and improvements in TBUT and Schirmer scores.

In addition to the availability of PF drugs, alternative preservatives have been developed to minimize the toxic effect of BAK [912]. Polyquaternium-1 (Polyquad[®]) is a quaternary ammonium preservative considered less toxic to the ocular surface, based on studies examining toxicity to corneal and conjunctival epithelial cells. Labbe et al. [913] showed that Polyquad induced considerably less toxicity than BAK *in vivo* and produced similar results to the control for the Schirmer test, slit-lamp, corneal fluorescein staining and histology [913]. SofZia™ is an oxidative preservation system used in one preparation of travoprost and several studies have shown improvement in symptoms and signs of OSD after switching from BAK-preserved medications to sofZia-preserved drops [914–916].

Further information on preservative interactions with the ocular surface can be found in the TFOS DEWS II Iatrogenic Dry Eye Report [102].

7.2. Systemic medications

Many drugs used for treating chronic illnesses can contribute to DED. A higher incidence of dry eye has been reported in individuals using antihistamines, beta-blockers, antidepressants, diuretics, anxiolytics, antipsychotics, anti-Parkinsonian drugs, isotretinoin, estrogen therapy and systemic chemotherapy [102,917]. The strategies to reduce or eliminate systemic drug-induced side effects include changing the route of administration from oral to topical, discontinuation of the drugs, dose adjustments, switching to another medication or more aggressive management of the induced dry eye [102].

7.3. Decreased blink rate

Blinking is critical to maintain precorneal tear film homeostasis on the ocular surface [918]. Decreased blink rate or incomplete blinking affect tear dynamics, lengthening the period during which the ocular surface is exposed to water loss before the next blink, thus contributing to the development of DED [919,920]. A major factor that impacts blink rate is the use of video display terminals (VDTs) and other digital devices, reading and a variety of other visual tasks and cognitive functions. With the exponential increase of computer use in the workplace, a proportionate increase in the

number of reports on the epidemiology and pathology of this condition has been reported [921,922]. The percentage of office workers using VDTs and diagnosed with dry eye increased up to 10% in male and 20% in female Japanese office workers [923]. The main mechanisms by which VDTs may induce dry eye signs or symptoms include increased tear film evaporation rate, development of MGD at an earlier age, reduced tear volume [924,925], decreased MUC5AC concentration in the tears [926] and increase oxidative stress [927].

The main treatment for individuals exhibiting such ocular surface changes is prevention of desiccation, and frequent use of ocular lubricants without preservatives is often the initial treatment of choice. However, devices or computer software that stimulate blinking on a more frequent basis represent a potential mechanism for minimizing the effect of VDTs. Miura et al. showed that a novel light-emitting diode (LED) device increased blink frequency for both dry eye and control groups [928]. Cardona et al. presented a strategy in which reflex blinking was elicited by a sudden distortion of the screen text to increase the spontaneous blink rate [929]. Frequent breaks and blinking awareness training are recommended for VDT users requiring prolonged periods of visual demand. Ergonomic factors such as lowering the screen allows the digital device user to gaze downward, thus exposing less ocular surface area to ambient air, reducing tear film loss and reducing symptoms of dry eye [930].

7.4. Desiccating conditions and environmental pollutants

The ocular surface is the most environmentally exposed mucosal surface of the body, encountering challenges such as wind exposure, low relative humidity, temperature extremes, UV radiation, irritants, pollutants and tobacco smoke. Exposure to adverse ambient conditions such as low humidity and/or increased/decreased air temperature and/or air movement, leads to increased tear instability and evaporation [931]. These conditions promote the development of dry eye symptoms in normal individuals and also worsen symptoms and signs in those with DED [932–935]. Chronic dryness of the ocular surface results in a downstream cascade of events that promote inflammation, epithelial apoptosis, loss of goblet cells and changes in the meibomian glands. Studies have demonstrated the efficacy of certain treatments in response to unfavorable environmental conditions. These include the use of artificial tears [43,936,937], medications that suppress inflammatory responses [584,842,938–940], drugs that induce mucus secretion [941], and drugs that decrease apoptosis [942].

While avoiding exposure to adverse conditions that can increase tear instability and evaporation is the initial tactic, creating conditions that mimic an adequate environment for the ocular surface is also a valid approach. These include the use of humidifiers [317,943] and retention of tear fluid using moisture chamber spectacles, contact lenses and punctal plugs [307,944–946].

Increased air pollution is associated with dry eye [947] and factors such as cigarette smoking may result in a dysfunctional tear film [948–950]. Tobacco smoke contains many oxidizing and toxic substances, exposing inhalers to an enormous free radical load. Matsumoto et al. confirmed the deleterious effect of chronic cumulative tobacco smoke exposure on the tear film, resulting in an increase in tear hexanoyl-lysine levels, an oxidative stress marker for lipid peroxidation [951]. Similar findings were observed by Rummenie et al. following passive cigarette smoke exposure [952]. The adverse effects of passive tobacco smoke on the tear film is evidenced by an increase in tear inflammatory cytokines, lipid peroxidation products and a decrease in mucosal defense, resulting in instability and damage to the ocular surface epithelia [948,951]. Inhibition of the oxidative stress therapeutically might act to “break

the cycle” of cytotoxicity, inflammation and cell death.

7.5. Contact lens wear

There are many factors that contribute to contact lens related discomfort and DED, including issues relating to the contact lens (including lens material, design, fit, replacement period and lens care system) [953], and the ocular surface [954]. A previous TFOS report addressed strategies to reduce contact lens discomfort [500]. These strategies included adjusting the contact lens replacement frequency, eliminating or changing the care system, altering lens design, adding tear supplementation and punctal occlusion [500].

In conclusion, there are many environmental factors that clinicians need to consider when treating individuals with DED and suitable management strategies will often be a helpful supplement to any prescribed therapies.

8. Complementary medicines

Due to various economic, cultural and regulatory issues, many countries exhibit a shortage of approved drugs for DED. A range of complementary medicines have been used as alternative strategies for the management of DED.

8.1. Herbal and natural products

Topical and oral herbal and natural products have been widely used in many countries for thousands of years. However, relatively few RCTs have compared herbal medicine with conventional therapies due to the inherent challenges in the way herbs are prescribed. Many of these therapies are based on the traditional “yin” and “yang” theory of Chinese medicine, and therefore require that practitioners treat dry eye patients with a combination of different Chinese herbs [955]. While this potentially allows for treatments to be “tailored” to the individual, it also prevents them from being standardized, and therefore it is more difficult to study the efficacy of these products using the gold standard RCT approach. Some laboratory-based Level 1 studies have suggested that Chinese medicines may play a role in regulating the immune balance of Th1 to Th2 cells in serum, as well as the expression of aquaporin-1 and aquaporin-5 [956,957]. However, the mechanism of action of such products remains elusive and clear demonstration of the effectiveness of herbs in treating DED requires further work. There are also a number of reported side effects, including nausea, abdominal pain, diarrhoea, minor gastrointestinal symptoms, mild hepatic dysfunction and renal dysfunction that need to be considered when adopting such treatment options [958].

In a Level 1 study involving 80 participants, Chi-Ju-Di-Huang-Wan, a commonly prescribed herb, was shown to significantly improve the TBUT of dry eye subjects after 4 weeks [959]. Several Level 2 and 3 studies have investigated the optimal combination of herbs needed to treat Sjögren syndrome [444,955,958]. A Level 1 double-masked RCT with 240 subjects showed that a six-week course of ShengJinRun ZaoYangXue granules for primary Sjögren syndrome improved the symptoms of dry mouth, dry eye, and low tear flow rates, although there was no improvement in clinical signs [960].

8.2. Honey

For centuries, some cultures have considered that bee products, such as royal jelly and honey, exhibit medicinal properties. In a variety of lab-based and clinical Level 2 and 3 studies these products have been reported to have antibacterial, anti-inflammatory, antioxidant and wound healing properties [961–964]. Oral

administration of royal jelly can restore tear secretion capacity in a blink-suppressed rat dry eye model [965]. Topical application of Mānuka honey eye drops can reduce the number of bacteria isolated from the eyelid margin and conjunctiva in patients with DED [966]. A Mānuka honey Cyclopower microemulsion eye cream with antimicrobial activity confirmed in preclinical testing [967], has demonstrated safety in a Phase I human tolerability trial [968]. Although promising, further clinical trials are needed to assess the therapeutic role of this formulation and other bee products.

8.3. Milk

Breast milk is a relatively common traditional medicine for treating a variety of eye conditions in some countries [969,970]. Topical instillation of breast milk, especially colostrum, has been shown to be effective in treating infant epiphora in a Level 3 study [971], and preventing neonatal conjunctivitis in a Level 1 study [972], through inhibition of a variety of common ocular pathogens [973–975].

In a small Level 3 study, 10 of 11 patients reported improvement in dryness symptoms and demonstrated some improvement in clinical signs after being treated with bovine colostrum lactoserum [976]. A rabbit study showed that topical fucosyl-lactose, a natural oligosaccharide in human colostrum, can significantly improve tear volume and TBUT in an atropine-induced dry eye model [977]. Breast milk also contains abundant lactoferrin (see section 6.3), which makes it a potent candidate for a natural remedy for dry eye treatment.

8.4. Acupuncture

Acupuncture is a long-standing intervention in East Asian countries to treat a wide variety of conditions. However, there are no common methods for acupuncture, which makes it challenging to study in a systematic manner. It has been suggested that stimulation of the peripheral nervous system with a concomitant central effect could be the mechanism of pain relief, which might then impact pain perception, alter inflammation or peripheral sensations, or “retrain” peripheral nerves in pain sensation [978].

Acupuncture has been reported to improve TBUT, Schirmer scores and corneal staining to a greater degree than artificial tears in Level 1 studies [979,980], a Level 2 study [981], and a meta-analysis report [982]. Another Level 1 study demonstrated that tear volume, as assessed by changes in tear meniscus parameters, was significantly improved after a four week treatment with acupuncture [983]. Some studies have assessed the effects of related procedures in the management of DED. Two well-controlled clinical studies showed that both laser acupuncture and silver spike point (SSP) electro-therapy were as effective as traditional acupuncture in alleviating symptoms and increasing tear secretion in subjects with dry eye [984,985].

One shortcoming of many of these studies is that the control used to assess the relative efficacy of acupuncture was artificial tears, as opposed to sham needling. In one RCT, 42 participants with DED were enrolled to accept either “true” or sham acupuncture [986]. After four weeks, subjects from both groups reported a significant improvement in symptoms, with no significant differences between the two groups. This led the authors to conclude that sham and true acupuncture were equally effective for treating symptoms of DED.

9. Management of psychological aspects of DED

DED has been shown to be associated with psychological factors, such as depression and stress [987–989]. The prevalence of sleep

and mood disorders has been shown to be significantly higher in people with DED [990]. Recognizing the importance of positive psychology, the World Health Organization considers ‘happiness’ to be an important component of general health [991]. Positive psychology, including a state of happiness, is considered to improve human function and promote people to lead more successful lives [992]. These findings have led to research interest in the influence of ‘happiness’ on the clinical expression of DED.

A recent Japanese study reported that people with higher levels of subjective happiness also had fewer self-reported dry eye symptoms; this association was not evident for objective indicators of DED [993]. Furthermore, participants with the lowest happiness scores reported significant DED symptoms but showed no objective clinical markers of DED. The authors concluded that there was a need for future studies investigating whether positive psychological interventions may be beneficial in the management of DED.

Findings from a cross-sectional survey-based study describing an association between DED and lower levels of physical activity and sedentary behavior [994], has also raised the question as to whether physical activity may influence the quality of the tear film. Although exercise has been proposed to be a potentially useful adjunct in the management of DED [994], clinical evidence to support this approach is currently lacking. In broad support of this hypothesis, exercise training for eight weeks in a mouse model of type II diabetes, was found to increase tear secretion [995].

10. Staged management algorithm

The management of DED is complicated due to its multifactorial etiology. Expanding upon the simple credo that “diagnosis precedes therapy” means that clinicians must make their best efforts to identify the degree to which EDE (likely related to MGD), ADDE and/or other ocular surface conditions are contributing to the patient's presentation. This aspect of determining the major causative factors behind the DED is critical to appropriate management.

Fig. 1 presents, diagrammatically, an approach to the management of DED. Prior to selecting the appropriate management to undertake, questioning and diagnostic testing must be undertaken to determine that the patient does indeed have DED and then whether they are broadly showing more signs of EDE or ADDE. Further details on the appropriate tests to confirm a diagnosis of DED and then the major etiological factors can be found in the TFOS DEWS II Diagnostic Methodology Report [10]. Following confirmation of a DED diagnosis, disease severity along with etiological subtyping, will allow an appropriate treatment plan to be developed.

The majority of patients with DED show some relationship between symptom severity and signs. However, it is well established that a proportion of patients exhibit conflicting signs and symptoms [996–998]. In situations where there are chronic symptoms but limited signs that are refractory to treatment, then neuropathic pain, rather than DED, should be considered. This is described in greater detail in the TFOS DEWS II Pain and Sensation Report [539]. In contrast, in patients where there are few symptoms but clear signs of DED, then reduced corneal sensitivity, suggestive of neurotrophic keratopathy, is a possibility [999–1001], and prescribing treatment may be particularly important to avoid ongoing damage.

The ultimate aim of DED management is to restore homeostasis of the ocular surface, by breaking the vicious cycle of the disease, and offering long-term options to prevent a return to the vicious cycle and a resurgence of symptoms. While there are treatments that may be specifically indicated for one particular aspect of an individual patient's ocular surface condition, a number of treatments might appropriately be recommended for multiple aspects of a DED presentation. The management of DED typically involves

Dry Eye Disease Management

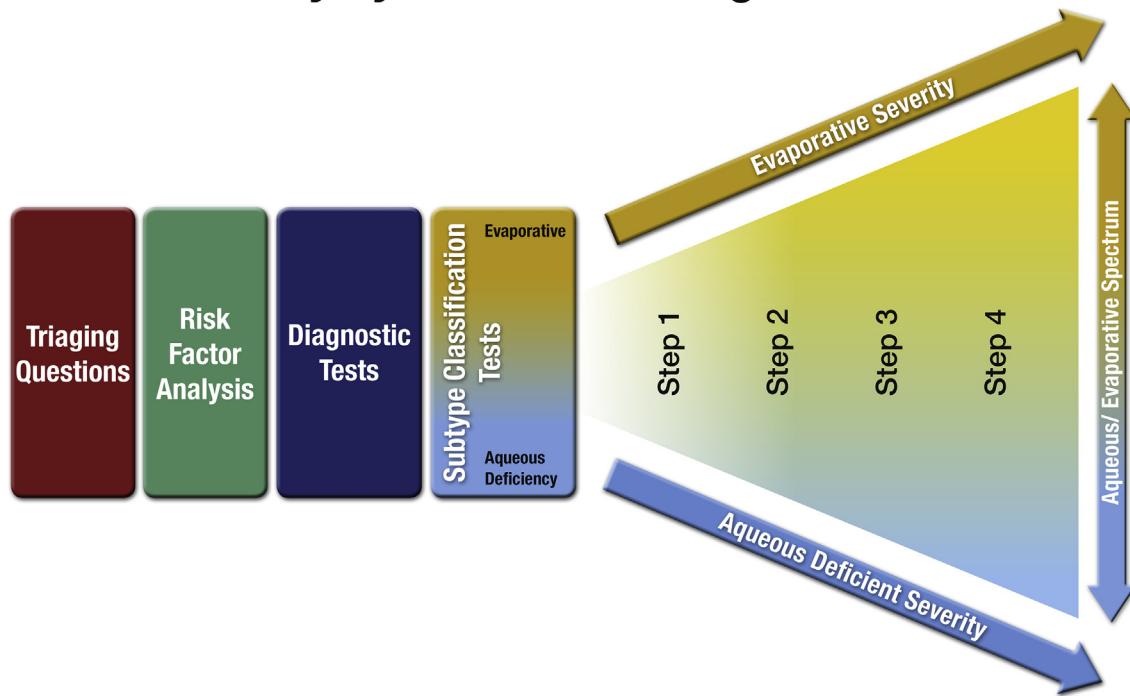


Fig. 1. Diagrammatic representation of the process associated with the management of DED.

dealing with chronic sequelae that require ongoing management, rather than short-term treatment, to eliminate the dry eye issues.

The management algorithm presented in this report does not represent a rigid stepwise approach, but rather should be viewed as an organizational tool to use when initiating treatment of DED, to select interventions likely to provide most benefit. The algorithm takes into account both disease etiology and severity, progressing from more generalized treatments for disease of mixed etiology, to more advanced and specific treatments aimed at particular aspects of the disease pathophysiology. Risk/benefit and cost considerations will also necessarily contribute to choices made between treatment options [5–9,17].

Management algorithms are often constructed to recommend a sequence of treatments according to the stage of disease, but this is not possible for DED as it is a complex condition that varies, both in severity and in character, from patient to patient. Nonetheless, with the intention of assisting eye care practitioners to fashion a logical, evidence-based treatment approach, the following management algorithm (Table 16) is proposed. For patients who do not respond to a given level of management, or who exhibit more severe DED, the next level of management is recommended and, in some cases, the previous therapy may be continued, in addition to any new therapies (Fig. 1 and Table 16). In general, management approaches begin with conventional, low-risk and commonly available therapies such as over-the-counter lubricants for early stage disease, and progress to more advanced therapies for more severe forms of DED [1002]. However, it is acknowledged that the significant heterogeneity that exists in the DED patient population precludes an overly formulaic approach and it would be anticipated that these recommendations would be adapted, by eye care practitioners, to best suit individual patients.

It is important, after initiating any of these management strategies, that careful follow-up occurs to ensure patients are successfully instituting the recommended management option(s) and to establish improvements in symptoms and/or signs. The time

frame over which therapy should be applied before it can be concluded that no improvement will occur is related to both the individual response and the therapy being considered. A review of the literature suggests that most studies are conducted for 1–3 months (with the exception of cyclosporine, where therapeutic action can take several months to occur and study periods are typically longer than 3 months) [595–597] and so changes beyond this time period for the majority of treatments would appear unlikely.

If there is clinical evidence of more severe complications associated with the dry eye presentation, such as advanced eyelid involvement (chalazia, trichiasis), corneal neovascularization or clinical signs of microbial infection, the clinician will need to consider additional approaches. Examples could potentially include intralesional steroid or excision of chalazia, eyelash epilation or cryotherapy for trichiasis, and antiangiogenic drugs for neovascularization. A full outline of these management strategies is beyond the scope of this report.

In summary, the management of DED remains something of an art, not easily lending itself to a rigid, evidence-based algorithm that accommodates all patients with dry eye symptoms and signs. All eye care providers who treat DED must exercise their clinical expertise to judge the significance of each of the varied pathogenic processes (aqueous deficiency, MGD, inflammation, etc.) that may manifest similar subjective complaints and similar signs of disrupted ocular surface homeostasis. On-going research will continue to improve our understanding of the relative treatment efficacy of different interventions for individual causes of DED, and determine synergistic therapeutic actions.

11. Future research directions

Since publication of the original TFOS DEWS report [1], the available options to treat DED have increased dramatically. The last decade has seen new developments in topical lubricants

Table 16
Staged management & treatment recommendations for dry eye disease^{a,b,c}.

Step 1:

- Education regarding the condition, its management, treatment and prognosis
- Modification of local environment
- Education regarding potential dietary modifications (including oral essential fatty acid supplementation)
- Identification and potential modification/elimination of offending systemic and topical medications
- Ocular lubricants of various types (if MGD is present, then consider lipid-containing supplements)
- Lid hygiene and warm compresses of various types

Step 2:

If above options are inadequate consider:

- Non-preserved ocular lubricants to minimize preservative-induced toxicity
- Tea tree oil treatment for Demodex (if present)
- Tear conservation
 - Punctal occlusion
 - Moisture chamber spectacles/goggles
- Overnight treatments (such as ointment or moisture chamber devices)
- In-office, physical heating and expression of the meibomian glands (including device-assisted therapies, such as LipiFlow)
- In-office intense pulsed light therapy for MGD
- Prescription drugs to manage DED^d
 - Topical antibiotic or antibiotic/steroid combination applied to the lid margins for anterior blepharitis (if present)
 - Topical corticosteroid (limited-duration)
 - Topical secretagogues
 - Topical non-glucocorticoid immunomodulatory drugs (such as cyclosporine)
 - Topical LFA-1 antagonist drugs (such as lifitegrast)
 - Oral macrolide or tetracycline antibiotics

Step 3:

If above options are inadequate consider:

- Oral secretagogues
- Autologous/allogeneic serum eye drops
- Therapeutic contact lens options
 - Soft bandage lenses
 - Rigid scleral lenses

Step 4:

If above options are inadequate consider:

- Topical corticosteroid for longer duration
- Amniotic membrane grafts
- Surgical punctal occlusion
- Other surgical approaches (eg tarsorrhaphy, salivary gland transplantation)

MGD – meibomian gland dysfunction; DED – dry eye disease.

^a Potential variations within the disease spectrum are acknowledged to exist between patients and the management options listed above are not intended to be exclusive. The severity and etiology of the DED state will dictate the range and number of management options selected from one or more steps.

^b One or more options concurrently within each category can be considered within that step of the dry eye disease state. Options within a category are not ranked according to importance and may be equally valid.

^c It should be noted that the evidence available to support the various management options differs and will inevitably be lower for newer management options. Thus, each treatment option should be considered in accordance with the level of evidence available at the time management is instigated.

^d The use of prescription drugs needs to be considered in the context of the individual patient presentation, and the relative level of evidence supporting their use for that specific indication, as this group of agents differs widely in mechanism of action.

(particularly lipid-containing drops), autologous serum options, and punctal plug designs. There have been many new developments to help with lid hygiene, as well as the availability of new treatments for demodex infestation, devices to manage MGD, and rigid gas permeable scleral lenses. In addition to the various options to manage the inflammatory processes associated with DED that have come to market, the impact of dietary modifications (particularly the value of EFA supplements) is better understood

and the potential value of various complementary medicines has come under discussion.

However, review of the published literature to date indicates that much more research is necessary to confirm the value of many of these treatment options. Clinical dogma concerning the prescribing of many management options is often poorly supported by Level 1 studies. Many studies have been conducted on small numbers samples of patients who are often poorly categorized. There are many opportunities for clinicians and researchers to conduct studies that would add to the body of knowledge available that would help guide the future management of patients with DED.

While the prescribing of OTC lubricants remains the mainstay of early treatment for DED, very few RCTs have compared inter-product superiority. With a wide variety of compositions now available, further work in this area is warranted. Of particular value would be studies comparing the efficacy of products with and without lipids in evaporative and in aqueous deficient DED. Studies to determine the impact of various formulations on tear film osmolarity and the duration of treatment required for changes to occur are also worthy of consideration, particularly for lubricants expected to influence tear film stability. Ocular surface compatibility comparisons between unit dose non-preserved formulations and formulations containing newer “softer” preservatives that are delivered in multidose bottles with one-way valves, are also missing from the literature. Finally, studies to look at the potential for topical antioxidants to impact the signs and symptoms of DED would be valuable.

The most widely used tear conservation approach is punctal plugging. However, given the acceptance of the importance of inflammation to the continued cycle of DED, little has been published on the potential for such a management option to impact ocular surface inflammation and this warrants some consideration. Other methods to enhance tear conservation include moisture chamber spectacles and local humidifiers, which are growing in popularity. However, very few studies have investigated their efficacy in a controlled manner.

Tear stimulation, via drugs or devices, is also of growing interest. Topical secretagogues are available in some markets and a novel intranasal tear neurostimulator device recently received FDA approval for acute tear production. Both approaches appear of potential value, but further Level 1 studies are needed to confirm their efficacy.

The value of lid hygiene to the successful management of DED is well accepted. However, careful review of the literature shows that very few Level 1 studies exist. What does the use of commercial lid scrubs do to the microbiota of the lids? Which bacteria are affected? How often and for how long should lid scrubs be performed? What does a maintenance regimen look like? What format of lid scrubs positively impacts tear osmolarity, tear film inflammatory markers or tear film stability? Is there an optimal combination of lid scrubs that can be used with other simple management options such as oral EFA supplementation and topical drops? Does the application of topical antibiotics to the eyelids in combination with lid scrubs have a positive impact on DED? What is the impact of tea tree oil based lid scrubs on ocular surface inflammation? This entire area is rich with opportunities for future study.

Since the TFOS MGD report was published [2], interest in the management of MGD has grown enormously. The value of warm compresses along with physical evacuation of the blocked glands is well accepted. However, the effectivity of warming devices appears to differ, and key features remain to be elucidated. Should heating be combined with massaging? How should in-office and at-home management be combined for optimum effect? In addition,

further work is needed in this area to determine if treatment with oral antibiotics is valuable in even lower severity cases, to what extent a maintenance regime is needed, and whether dietary modifications can help in the management of MGD. We might hope to understand more fully the role lipid-based lubricants can play in conjunction with physical therapies, the underlying pathophysiological process that explains why IPL can be successful, whether intraductal probing is damaging over the long term and how often it can be undertaken, and how long debridement scaling over the meibomian gland orifices lasts before it needs to be repeated. These, and many more studies, would enhance our ability to manage MGD in patients with DED.

Despite recognition of the role of inflammation in DED, there continues to be a shortage of Level 1 studies investigating the long-term role of newer topical steroids and NSAIDs on the management of DED. Further work is also required to investigate the potential for steroids or NSAIDs in a pulse-dose form to break the cycle of DED and to clarify appropriate dosing schedules.

The increasing availability of a variety of topical biologics and commercialisation of a new LFA-1 antagonist opens up many new opportunities to investigate the role of these new topical agents in ameliorating a wide variety of symptoms and signs in patients with DED.

The role of systemic antibiotics (tetracyclines and macrolides) in the management of DED is relatively poorly understood and optimal dosing schedules remain under intense debate, with a wide variety of suggestions published. Further work to understand their role and to predict which patients are most likely to benefit from their use is warranted.

There is growing evidence that dietary modifications, notably increased water intake and EFA supplementation, can impact DED. However, selection of the appropriate EFAs to ingest, their relative ratios, the daily dosing regimen, impact on tear film inflammatory markers, goblet cell density, tear stability and osmolarity all require further study.

Finally, a number of herbal and natural products are increasingly being used to manage patients with DED, with various herbs and honey showing promise. These topical and systemic agents, along with acupuncture, require more Level 1 studies to gain widespread acceptance as potential management options for DED.

Reflecting on all of the available evidence to date, a staged management algorithm (Table 16) that presents a step-wise approach to implementing the various management and therapeutic options according to disease severity was derived. While this exercise indicated that differentiating between aqueous-deficient and evaporative dry eye disease was important in selecting the most appropriate management strategy, it also highlighted challenges, based on the limited evidence currently available, in predicting relative benefits of specific management options, in managing the two DED subtypes. As diagnostic testing of signs and symptoms improves, and better differentiation of patients by DED subtype is achieved, there is a growing need to understand the relative benefits of the many available options in managing ADDE and EDE.

While much research is necessary to provide the answers to the questions posed above, the expanding range of possible solutions and the continued backing of industry and grant-funding agencies provides a positive outlook for affected patients moving forward.

Financial disclosures

L. Jones, Chair: Advanced Vision Research, Alcon, Allergan, Contamac, CooperVision, Essilor, Inflamax, Johnson & Johnson Vision Care, Ocular Dynamics, Oculus, Safilens, TearLab, TearScience (F); Alcon, CooperVision, Johnson & Johnson Vision Care (C) (R).

J. Benitez de Castillo Sanchez: Abbvie, Alcon, Allergan, Angelini, Bausch + Lomb, Dompé, Esteve, Horus, Laboratoires Théa, Novartis, Santen (F) (C).

R. Dana: Eleven Biotherapeutics (I); Alcon, Allergan, Cambium, Eleven Biotherapeutics, NovaBay, Rigel, Shire (C).

S. Deng: Chiesi Farmaceutici S.P.A. (C).

P. N. Dong: None.

L. Downie: Alcon, Allergan, CooperVision (F).

G. Geerling: TearLab, TearScience (F); TearLab (I); Allergan, Bausch + Lomb, Laboratoires Théa, Oculus, Santen, TearLab, TearScience (C).

R. Y. Hida: None.

D. Jacobs: BostonSight (E); TECLens (C).

D. Korb: Inventor relative to dry eye (P).

Y. Liu: Co-owner of patent with Schepens Eye Research Institute (P).

K. Y. Seo: None.

J. Tauber: Eleven Biotherapeutics, Kala, Shire (F); Shire (C); Allergan, Eleven Biotherapeutics, Shire (R).

T. Wakamatsu: None.

J. Xu: None.

J. P. Craig, Harmonisation member and Vice-Chair: Oculeve, Allergan, Manuka Health NZ, E-Swin, CooperVision, Alcon, Optima Pharmaceuticals, OPSM NZ, Akorn, Medmont (F); Carl Zeiss Meditec, Eye Institute Auckland (C).

F (Financial Support), I (Personal Financial Interest), E (Employment), C (Consultant), P (Patent), R (Recipient), N (No Commercial Relationship), S (non-remunerative).

Acknowledgments

The authors would like to thank the TFOS membership and, in particular, the following individuals for assistance with various sections of this report: Francisco Amparo, Penny Asbell, Caroline Blackie, Stephanie Cox, Teresa Douglass, Anat Galor, Pedram Hamrah, Jiaxu Hong, Deborah Jacobs, Ahmad Kheirkhah, Nino Longo, Amy Nau, Mark Rosenblatt, Benjamin Sullivan, Kunal Suri, Stephanie Wong, Sabrina Zappia.

References

- [1] Management and therapy of dry eye disease: report of the management and therapy subcommittee of the international dry eye Workshop. *Ocul Surf* 2007;2007(5):163–78.
- [2] Nelson JD, Shimazaki J, Benitez-del-Castillo JM, Craig JP, McCulley JP, Den S, et al. The international workshop on meibomian gland dysfunction: report of the definition and classification subcommittee. *Invest Ophthalmol Vis Sci* 2011;52(4):1930–7.
- [3] Craig JP, Nichols KK, Akpek EK, Caffery B, Dua HS, Joo CK, et al. TFOS DEWS II Definition and Classification report. *Ocul Surf* 2017;15:276–83.
- [4] Lemp MA, Crews LA, Bron AJ, Foulks GN, Sullivan BD. *Cornea* 2012;31(5):472–8.
- [5] Williamson JF, Huynh K, Weaver MA, Davis RM. Perceptions of dry eye disease management in current clinical practice. *Eye Contact Lens* 2014;40(2):111–5.
- [6] Song JS, Hyon JY, Lee D, Chung E, Choi C, Lee J, et al. Current practice pattern for dry eye patients in South Korea: a multicenter study. *Korean J Ophthalmol* 2014;28(2):115–21.
- [7] Sy A, O'Brien KS, Liu MP, Cuddapah PA, Acharya NR, Lietman TM, et al. Expert opinion in the management of aqueous deficient dry eye disease (DED). *BMC Ophthalmol* 2015;15:133.
- [8] Downie LE, Keller PR, Vingrys AJ. An evidence-based analysis of Australian optometrists' dry eye practices. *Optom Vis Sci* 2013;90(12):1385–95.
- [9] Downie LE, Rumney N, Gad A, Keller PR, Purslow C, Vingrys AJ. Comparing self-reported optometric dry eye clinical practices in Australia and the United Kingdom: is there scope for practice improvement? *Ophthalmic Physiol Opt* 2016;36(2):140–51.
- [10] Wolffsohn JS, Arita R, Chalmers R, Djalilian A, Dogru M, Dumbleton K, et al. TFOS DEWS II Diagnostic Methodology report. *Ocul Surf* 2017;15:539–74.
- [11] Tong L, Petznick A, Lee S, Tan J. Choice of artificial tear formulation for patients with dry eye: where do we start? *Cornea* 2012;31(Suppl 1):S32–6.
- [12] Murube J, Paterson A, Murube E. Classification of artificial tears. I:

- composition and properties. *Adv Exp Med Biol* 1998;438:693–704.
- [13] Murube J, Murube A, Zhuo C. Classification of artificial tears. II: additives and commercial formulas. *Adv Exp Med Biol* 1998;438:705–15.
- [14] Dogru M, Nakamura M, Shimazaki J, Tsubota K. Changing trends in the treatment of dry-eye disease. *Expert Opin Invest Drugs* 2013;22(12):1581–601.
- [15] Dogru M, Tsubota K. Pharmacotherapy of dry eye. *Expert Opin Pharmacother* 2011;12(3):325–34.
- [16] Pucker AD, Ng SM, Nichols JJ. Over the counter (OTC) artificial tear drops for dry eye syndrome. *Cochrane Database Syst Rev* 2016;2:CD009729.
- [17] Downie LE, Keller PR. A pragmatic approach to dry eye diagnosis: evidence into practice. *Optom Vis Sci* 2015;92(12):1189–97.
- [18] Wegener AR, Meyer LM, Schönfeld CL. Effect of viscous agents on corneal density in dry eye disease. *J Ocul Pharmacol Ther* 2015;31(8):504–8.
- [19] Yu F, Liu X, Zhong Y, Guo X, Li M, Mao Z, et al. Sodium hyaluronate decreases ocular surface toxicity induced by benzalkonium chloride-preserved latanoprost: an in vivo study. *Invest Ophthalmol Vis Sci* 2013;54:3385–93.
- [20] Doughty MJ, Glavin S. Efficacy of different dry eye treatments with artificial tears or ocular lubricants: a systematic review. *Ophthalmic Physiol Opt* 2009;29(6):573–83.
- [21] Kamel S, Ali N, Jahangir K, Shah SM, El-Gendy AA. Pharmaceutical significance of cellulose: a review. *Express Polym Lett* 2008;2(11):758–78.
- [22] Garrett Q, Simmons PA, Xu S, Vehige J, Zhao Z, Ehrmann K, et al. Carboxymethylcellulose binds to human corneal epithelial cells and is a modulator of corneal epithelial wound healing. *Invest Ophthalmol Vis Sci* 2007;48(4):1559–67.
- [23] Garrett Q, Xu S, Simmons PA, Vehige J, Xie RZ, Kumar A, et al. Carboxymethyl cellulose stimulates rabbit corneal epithelial wound healing. *Curr Eye Res* 2008;33(7):567–73.
- [24] Bruix A, Adan A, Casaroli-Marano RP. Efficacy of sodium carboxymethylcellulose in the treatment of dry eye syndrome. *Arch Soc Esp Oftalmol* 2006;81:85–92.
- [25] Noecker RJ. Comparison of initial treatment response to two enhanced-viscosity artificial tears. *Eye Contact Lens* 2006;32(3):148–52.
- [26] Lee JH, Ahn HS, Kim EK, Kim TI. Efficacy of sodium hyaluronate and carboxymethylcellulose in treating mild to moderate dry eye disease. *Cornea* 2011;30(2):175–9.
- [27] Rah MJ. A review of hyaluronan and its ophthalmic applications. *Optometry* 2011;82(1):38–43.
- [28] Inoue M, Katakami C. The effect of hyaluronic acid on corneal epithelial cell proliferation. *Invest Ophthalmol Vis Sci* 1993;34(7):2313–5.
- [29] Stiebel-Kalish H, Gatton DD, Weinberger D, Loya N, Schwartz-Ventik M, Solomon A. A comparison of the effect of hyaluronic acid versus gentamicin on corneal epithelial healing. *Eye (Lond)* 1998;12(5):829–33.
- [30] Gomes JA, Amankwah R, Powell-Richards A, Dua HS. Sodium hyaluronate (hyaluronic acid) promotes migration of human corneal epithelial cells in vitro. *Br J Ophthalmol* 2004;88(6):821–5.
- [31] Camillieri G, Bucolo C, Rossi S, Drago F. Hyaluronan-induced stimulation of corneal wound healing is a pure pharmacological effect. *J Ocul Pharmacol Ther* 2004;20(6):548–53.
- [32] Yang G, Espandar L, Mamalis N, Prestwich GD. A cross-linked hyaluronan gel accelerates healing of corneal epithelial abrasion and alkali burn injuries in rabbits. *Vet Ophthalmol* 2010;13(3):144–50.
- [33] Ho WT, Chiang TH, Chang SW, Chen YH, Hu FR, Wang JJ. Enhanced corneal wound healing with hyaluronic acid and high-potassium artificial tears. *Clin Exp Optom* 2013;96(6):536–41.
- [34] Pisárcik M, Bakoš D, Ceppan M. Non-Newtonian properties of hyaluronic acid aqueous solution. *Colloids Surf A* 1995;97:197–202.
- [35] Johnson ME, Murphy PJ, Boulton M. Carbomer and sodium hyaluronate eyedrops for moderate dry eye treatment. *Optom Vis Sci* 2008;85(8):750–7.
- [36] Lekhanont K, Chuckpaiwong V, Vongthongsri A, Sangiampornpanit T. Effects of sodium hyaluronate on wavefront aberrations in dry eye patients. *Optom Vis Sci* 2014;91(1):39–46.
- [37] Kinoshita S, Oshiden K, Awamura S, Suzuki H, Nakamichi N, Yokoi N, Rebamipide Ophthalmic Suspension Phase 3 Study Group. A randomized, multicenter phase 3 study comparing 2% rebamipide (OPC-12759) with 0.1% sodium hyaluronate in the treatment of dry eye. *Ophthalmology* 2013;120(6):1158–65.
- [38] Takamura Etsuko, Tsubota Kazuo, Watanabe Hitoshi, Ohashi Yuichi. A randomised, double-masked comparison study of diquafosol versus sodium hyaluronate ophthalmic solutions in dry eye patients. *Br J Ophthalmol* 2012;96(10):1310–5.
- [39] Cheema A, Aziz T, Mirza SA, Siddiqi A, Maheshwary N, Khan MA. Sodium hyaluronate eye drops in the treatment of dry eye disease: an open label, uncontrolled, multi-centre trial. *J Ayub Med Coll Abbottabad* 2012 Jul-Dec;24(3–4):14–6.
- [40] Baudouin C, Cochenier B, Pisella PJ, Girard B, Pouliquen P, Cooper H, et al. Randomized, phase III study comparing osmoprotective carboxymethylcellulose with sodium hyaluronate in dry eye disease. *Eur J Ophthalmol* 2012 Sep-Oct;22(5):751–61.
- [41] Pinto-Fraga J, Lopez-de la Rosa A, Blazquez Arauzo F, Urbano Rodriguez R, Gonzalez-Garcia MJ. Efficacy and safety of 0.2% hyaluronic acid in the management of dry eye disease. *Eye Contact Lens* 2017;43:57–63.
- [42] Park Y, Song JS, Choi CY, Yoon KC, Lee HK, Kim HS. A randomized multicenter study comparing 0.1%, 0.15%, and 0.3% sodium hyaluronate with 0.05% cyclosporine in the treatment of dry eye. *J Ocul Pharmacol Ther* 2017;33(2):66–72.
- [43] She Y, Li J, Xiao B, Lu H, Liu H, Simmons PA, et al. Evaluation of a novel artificial tear in the prevention and treatment of dry eye in an animal model. *J Ocul Pharmacol Ther* 2015;31(9):525–30.
- [44] Simmons PA, Liu H, Carlisle-Wilcox C, Vehige JG. Efficacy and safety of two new formulations of artificial tears in subjects with dry eye disease: a 3-month, multicenter, active-controlled, randomized trial. *Clin Ophthalmol* 2015;9:665–75.
- [45] Springs C. Novel ocular lubricant containing an intelligent delivery system: details of its mechanism of action. *Dev Ophthalmol* 2010;45:139–47.
- [46] Benelli U. Systane lubricant eye drops in the management of ocular dryness. *Clin Ophthalmol* 2011;5:783–90.
- [47] Christensen MT. Corneal staining reductions observed after treatment with Systane lubricant eye drops. *Adv Ther* 2008;25(11):1191–9.
- [48] Ousler GV, Michaelson C, Christensen MT. An evaluation of tear film breakup time extension and ocular protection index scores among three marketed lubricant eye drops. *Cornea* 2007;26(8):949–52.
- [49] Cervan-Lopez I, Saenz-Frances-San-Baldomero F, Benitez-Del-Castillo JM, Garcia-Sanchez J. Reduction of corneal permeability in patients treated with HP-guar: a fluorophotometric study. *Arch Soc Esp Oftalmol* 2006;81:327–32.
- [50] Moon SW, Hwang JH, Chung SH, Nam KH. The impact of artificial tears containing hydroxypropyl guar on mucous layer. *Cornea* 2010;29(12):1430–5.
- [51] Uchiyama E, Di Pascuale MA, Butovich IA, McCulley JP. Impact on ocular surface evaporation of an artificial tear solution containing hydroxypropyl guar. *Eye Contact Lens* 2008;34(6):331–4.
- [52] Sánchez MA, Arriola-Villalobos P, Torralbo-Jiménez P, Girón N, de la Heras B, Herrero Vanrell R, et al. The effect of preservative-free HP-Guar on dry eye after phacoemulsification: a flow cytometric study. *Eye (Lond)* 2010;24(8):1331–7.
- [53] Gifford P, Evans BJ, Morris J. A clinical evaluation of Systane. *Cont Lens Anter Eye* 2006;29(1):31–40.
- [54] Rangarajan R, Kraybill B, Ogundele A, Ketelson HA. Effects of a hyaluronic acid/hydroxypropyl guar artificial tear solution on protection, recovery, and lubricity in models of corneal epithelium. *J Ocul Pharmacol Ther* 2015;31(8):491–7.
- [55] Werblin TP, Rheinstrom SD, Kaufman HE. The use of slow-release artificial tears in the long-term management of keratitis sicca. *Ophthalmology* 1981;88(1):78–81.
- [56] McDonald M, D'Aversa G, Perry HD, Wittmann JR, Donnenfeld ED, Nelinson DS. Hydroxypropyl cellulose ophthalmic inserts (lacrisert) reduce the signs and symptoms of dry eye syndrome and improve patient quality of life. *Trans Am Ophthalmol Soc* 2009;107:214–21.
- [57] The definition and classification of dry eye disease: report of the definition and classification subcommittee of the international dry eye Workshop. *Ocul Surf* 2007;2007(5):75–92.
- [58] Gilbard JP, Rossi SR, Heyda KG. Ophthalmic solutions, the ocular surface, and a unique therapeutic artificial tear formulation. *Am J Ophthalmol* 1989;107(4):348–55.
- [59] Gilbard JP, Rossi SR. An electrolyte-based solution that increases corneal glycogen and conjunctival goblet-cell density in a rabbit model for keratoconjunctivitis sicca. *Ophthalmology* 1992;99(4):600–4.
- [60] Gilbard JP. Dry eye: pharmacological approaches, effects, and progress. *CLAO J* 1996;22(2):141–5.
- [61] Troiano P, Monaco G. Effect of hypotonic 0.4% hyaluronic acid drops in dry eye patients: a cross-over study. *Cornea* 2008;27(10):1126–30.
- [62] Baeyens V, Bron A, Baudouin C, Vismad/Hylovis Study Group. Efficacy of 0.18% hypotonic sodium hyaluronate ophthalmic solution in the treatment of signs and symptoms of dry eye disease. *J Fr Ophthalmol* 2012;35(6):412–9.
- [63] Sullivan BD, Crews LA, Sönmez B, de la Paz MF, Comert E, Charoenrook V, et al. Clinical utility of objective tests for dry eye disease: variability over time and implications for clinical trials and disease management. *Cornea* 2012;31(9):1000–8.
- [64] Scuderi G, Contestabile MT, Gagliano C, Iacovello D, Scuderi L, Avitabile T. Effects of phytoestrogen supplementation in postmenopausal women with dry eye syndrome: a randomized clinical trial. *Can J Ophthalmol* 2012;47(6):489–92.
- [65] Tomlinson A, Madden LC, Simmons PA. Effectiveness of dry eye therapy under conditions of environmental stress. *Curr Eye Res* 2013;38(2):229–36.
- [66] Versura P, Profazio V, Giannaccare G, Fresina M, Campos EC. Discomfort symptoms reduction and ocular surface parameters recovery with Artelac Rebalance treatment in mild-moderate dry eye. *Eur J Ophthalmol* 2013 Jul-Aug;23(4):488–95.
- [67] Montani G. Intrasubject tear osmolarity changes with two different types of eyedrops. *Optom Vis Sci* 2013;90(4):372–7.
- [68] Lee JE, Kim NM, Yang JW, Kim SJ, Lee JS, Lee JE. A randomized controlled trial comparing a thermal massager with artificial teardrops for the treatment of dry eye. *Br J Ophthalmol* 2014;98(1):46–51.
- [69] Aslan Bayhan S, Bayhan HA, Muhafiz E, Bekdemir Ş, Gürdal C. Effects of osmoprotective eye drops on tear osmolarity in contact lens wearers. *Can J Ophthalmol* 2015;50(4):283–9.
- [70] Miseroocchi E, Iuliano L, Berchicci L, Bandello F, Modorati G. Tear film osmolarity in ocular mucous membrane pemphigoid. *Cornea* 2014;33(7):668–72.

- [71] Gilbard JP, Huang AJ, Beldegrun R, Lee JS, Rossi SR, Gray KL. Open-label crossover study of vitamin A ointment as a treatment for keratoconjunctivitis sicca. *Ophthalmology* 1989;96(2):244–6.
- [72] Finis D, Hayajneh J, König C, Borrelli M, Schrader S, Geerling G. Evaluation of an automated thermodynamic treatment (LipiFlow®) system for meibomian gland dysfunction: a prospective, randomized, observer-masked trial. *Ocul Surf* 2014;12(2):146–54.
- [73] Mathers WD, Shields WJ, Sachdev MS, Petroll WM, Jester JV. Meibomian gland morphology and tear osmolarity: changes with Accutane therapy. *Cornea* 1991;10(4):286–90.
- [74] Labbé A, Terry O, Brasnu E, Van Went C, Baudouin C. Tear film osmolarity in patients treated for glaucoma or ocular hypertension. *Cornea* 2012;31(9):994–9.
- [75] Lee JH, Min K, Kim SK, Kim EK, Kim TI. Inflammatory cytokine and osmolarity changes in the tears of dry eye patients treated with topical 1% methylprednisolone. *Yonsei Med J* 2014;55(1):203–8.
- [76] Jaddi K, Panahi Y, Ebrahimi A, Mafi M, Nejat F, Sahebkar A. Topical cyclosporine A for treatment of dry eye due to chronic mustard gas injury. *J Ophthalmic Vis Res* 2014 Oct-Dec;9(4):417–22.
- [77] Hamada S, Moore TC, Moore JE, Al-Dreihy MG, Anbari A, Shah S. Assessment of the effect of cyclosporine-A 0.05% emulsion on the ocular surface and corneal sensation following cataract surgery. *Cont Lens Anter Eye* 2016;39(1):15–9.
- [78] Nelson JD, Farris RL. Sodium hyaluronate and polyvinyl alcohol artificial tear preparations. A comparison in patients with keratoconjunctivitis sicca. *Arch Ophthalmol* 1988;106(4):484–7.
- [79] Iester M, Orsoni GJ, Gamba G, Taffara M, Mangiafico P, Giuffrida S, et al. Improvement of the ocular surface using hypotonic 0.4% hyaluronic acid drops in keratoconjunctivitis sicca. *Eye (Lond)* 2000;14(Pt 6):892–8.
- [80] Benelli U, Nardi M, Posarelli C, Albert TG. Tear osmolarity measurement using the TearLab Osmolarity System in the assessment of dry eye treatment effectiveness. *Cont Lens Anter Eye* 2010;33(2):61–7.
- [81] Cómez AT, Tufan HA, Kocabişık O, Gencer B. Effects of lubricating agents with different osmolarities on tear osmolarity and other tear function tests in patients with dry eye. *Curr Eye Res* 2013;38(11):1095–103.
- [82] Garrett Q, Xu S, Simmons PA, Vehige J, Flanagan JL, Willcox MD. Expression and localization of carnitine/organic cation transporter OCTN1 and OCTN2 in ocular epithelium. *Invest Ophthalmol Vis Sci* 2008;49(11):4844–9.
- [83] Xu S, Flanagan JL, Simmons PA, Vehige J, Willcox MD, Garrett Q. Transport of L-carnitine in human corneal and conjunctival epithelial cells. *Mol Vis* 2010;16:1823–31.
- [84] Khandekar N, Willcox MD, Shih S, Simmons P, Vehige J, Garrett Q. Decrease in hyperosmotic stress-induced corneal epithelial cell apoptosis by L-carnitine. *Mol Vis* 2013;19:1945–56.
- [85] Garrett Q, Khandekar N, Shih S, Flanagan JL, Simmons P, Vehige J, et al. Betaine stabilizes cell volume and protects against apoptosis in human corneal epithelial cells under hyperosmotic stress. *Exp Eye Res* 2013;108:33–41.
- [86] Corrales RM, Luo L, Chang EY, Pflugfelder SC. Effects of osmoprotectants on hyperosmolar stress in cultured human corneal epithelial cells. *Cornea* 2008;27(5):574–9.
- [87] Hua X, Su Z, Deng R, Lin J, Li DQ, Pflugfelder SC. Effects of L-carnitine, erythritol and betaine on pro-inflammatory markers in primary human corneal epithelial cells exposed to hyperosmotic stress. *Curr Eye Res* 2015;40(7):657–67.
- [88] Chen W, Zhang X, Li J, Wang Y, Chen Q, Hou C, et al. Efficacy of osmoprotectants on prevention and treatment of murine dry eye. *Invest Ophthalmol Vis Sci* 2013;54(9):6287–97.
- [89] Baudouin C, Aragona P, Messmer EM, Tomlinson A, Calonge M, Boboridis KG, et al. Role of hyperosmolarity in the pathogenesis and management of dry eye disease: proceedings of the OCEAN group meeting. *Ocul Surf* 2013;11(4):246–58.
- [90] Chen W, Zhang X, Liu M, Zhang J, Ye Y, Lin Y, et al. Trehalose protects against ocular surface disorders in experimental murine dry eye through suppression of apoptosis. *Exp Eye Res* 2009;89(3):311–8.
- [91] Hovakimyan M, Ramoth T, Löbner M, Schmitz KP, Witt M, Guthoff R, et al. Evaluation of protective effects of trehalose on desiccation of epithelial cells in three dimensional reconstructed human corneal epithelium. *Curr Eye Res* 2012;37(11):982–9.
- [92] Li J, Roubeix C, Wang Y, Shi S, Liu G, Baudouin C, et al. Therapeutic efficacy of trehalose eye drops for treatment of murine dry eye induced by an intelligently controlled environmental system. *Mol Vis* 2012;18:317–29.
- [93] Iturriaga G, Suárez R, Nova-Franco B. Trehalose metabolism: from osmoprotection to signaling. *Int J Mol Sci* 2009;10(9):3793–810.
- [94] Luyckx J, Baudouin C. Trehalose: an intriguing disaccharide with potential for medical application in ophthalmology. *Clin Ophthalmol* 2011;5:577–81.
- [95] Matsuo T. Trehalose protects corneal epithelial cells from death by drying. *Br J Ophthalmol* 2001;85(5):610–2.
- [96] Sarkar S, Davies JE, Huang Z, Tunnacliffe A, Rubinsztein DC. Trehalose, a novel mTOR-independent autophagy enhancer, accelerates the clearance of mutant huntingtin and alpha-synuclein. *J Biol Chem* 2007;282(8):5641–52.
- [97] Cejková J, Cejka C, Luyckx J. Trehalose treatment accelerates the healing of UVB-irradiated corneas. Comparative immunohistochemical studies on corneal cryostat sections and corneal impression cytology. *Histol Histopathol* 2012;27(8):1029–40.
- [98] Baudouin C, Labbé A, Liang H, Pauly A, Brignole-Baudouin F. Preservatives in eyedrops: the good, the bad and the ugly. *Prog Retin Eye Res* 2010;29(4):312–34.
- [99] Augustin AJ, Spitznas M, Kaviani N, Meller D, Koch FH, Grus F, et al. Oxidative reactions in the tear fluid of patients suffering from dry eyes. *Graefes Arch Clin Exp Ophthalmol* 1995;233(11):694–8.
- [100] Hongyok T, Chae JJ, Shin YJ, Na D, Li L, Chuck RS. Effect of chitosan-N-acetylcysteine conjugate in a mouse model of botulinum toxin B-induced dry eye. *Arch Ophthalmol* 2009;127(4):525–32.
- [101] Kim EC, Choi JS, Joo CK. A comparison of vitamin A and cyclosporine a 0.05% eye drops for treatment of dry eye syndrome. *Am J Ophthalmol* 2009;147(2):206–13. e3.
- [102] Gomes JAP, Azar DT, Baudouin C, Efron N, Hirayama M, Horwath-Winter J, et al. TFOS DEWS II Iatrogenic report. *Ocul Surf* 2017;15:511–38.
- [103] Stoddard AR, Koetje LR, Mitchell AK, Schotman MP, Ubels JL. Bioavailability of antioxidants applied to stratified human corneal epithelial cells. *J Ocul Pharmacol Ther* 2013;29(7):681–7.
- [104] Brzheshkiy VV, Efimova EL, Vorontsova TN, Alekseev VN, Gusarevich OG, Shaidurova KN, et al. Ryabtseva AA, Andryukhina OM, Kamenskikh TG, Sumarokova ES, Miljudin ES, Egorov EA, Lebedev OI, Surov AV, Korol AR, Nasinnyk IO, Bezditko PA, Muzhychuk OP, Vygodin VA, Yani EV, Savchenko AY, Karger EM, Fedorkin ON, Mironov AN, Ostapenko V, Popeko NA, Skulachev VP, Skulachev MV. Results of a multicenter, randomized, double-masked, placebo-controlled clinical study of the efficacy and safety of Visomitin eye drops in patients with dry eye syndrome. *Adv Ther* 2015;32(12):1263–79.
- [105] Mostert V. Selenoprotein P: properties, functions, and regulation. *Arch Biochem Biophys* 2000;376(2):433–8.
- [106] Higuchi A, Takahashi K, Hirashima M, Kawakita T, Tsubota K. Selenoprotein P controls oxidative stress in cornea. *PLoS One* 2010;5:e9911.
- [107] Baudouin C. The pathology of dry eye. *Surv Ophthalmol* 2001;45(Suppl 2):S211–20.
- [108] Noecker R. Effects of common ophthalmic preservatives on ocular health. *Adv Ther* 2001 Sep-Oct;18(5):205–15.
- [109] Stewart WC, Stewart JA, Nelson LA. Ocular surface disease in patients with ocular hypertension and glaucoma. *Curr Eye Res* 2011;36(5):391–8.
- [110] Mantelli F, Franchina L, Lambiase A, Bonini S. Ocular surface damage by ophthalmic compounds. *Curr Opin Allergy Clin Immunol* 2011;11(5):464–70.
- [111] Stalmans I, Sunaric Mégevand G, Cordeiro MF, Hommer A, Rossetti L, Goñi F, et al. Preservative-free treatment in glaucoma: who, when, and why. *Eur J Ophthalmol* 2013 Jul-Aug;23(4):518–25.
- [112] Anwar Z, Wellik SR, Galor A. Glaucoma therapy and ocular surface disease: current literature and recommendations. *Curr Opin Ophthalmol* 2013;24(2):136–43.
- [113] Pinheiro R, Panfil C, Schrage N, Dutescu RM. The impact of glaucoma medications on corneal wound healing. *J Glaucoma* 2016;25(1):122–7.
- [114] Chen W, Zhang Z, Hu J, Xie H, Pan J, Dong N, et al. Changes in rabbit corneal innervation induced by the topical application of benzalkonium chloride. *Cornea* 2013;32(12):1599–606.
- [115] Lin Z, He H, Zhou T, Liu X, Wang Y, He H, et al. A mouse model of limbal stem cell deficiency induced by topical medication with the preservative benzalkonium chloride. *Invest Ophthalmol Vis Sci* 2013;54(9):6314–25.
- [116] Kaercher T, Hönig D, Barth W. How the most common preservative affects the Meibomian lipid layer. *Orbit* 1999;18(2):89–97.
- [117] Schrage N, Frentz M, Spoeler F. The Ex Vivo Eye Irritation Test (EVEIT) in evaluation of artificial tears: Purite-preserved versus unpreserved eye drops. *Graefes Arch Clin Exp Ophthalmol* 2012;250(9):1333–40.
- [118] Jee D, Park SH, Kim MS, Kim EC. Antioxidant and inflammatory cytokine in tears of patients with dry eye syndrome treated with preservative-free versus preserved eye drops. *Invest Ophthalmol Vis Sci* 2014;55(8):5081–9.
- [119] Bernauer W, Thiel MA, Kurrer M, Heiligenhaus A, Rentsch KM, Schmitt A, et al. Corneal calcification following intensified treatment with sodium hyaluronate artificial tears. *Br J Ophthalmol* 2006;90(3):285–8.
- [120] Imayasu M, Hori Y, Cavanagh HD. Effects of multipurpose contact lens care solutions and their ingredients on membrane-associated mucins of human corneal epithelial cells. *Eye Contact Lens* 2010;36(6):361–6.
- [121] Lehmann DM, Cavet ME, Richardson ME. Nonclinical safety evaluation of boric acid and a novel borate-buffered contact lens multi-purpose solution, Biotrue multi-purpose solution. *Cont Lens Anter Eye* 2010;33(Suppl 1):S24–32.
- [122] Pelton R, Hu Z, Ketelson H, Meadows D. Reversible flocculation with hydroxypropyl guar-borate, a labile anionic polyelectrolyte. *Langmuir* 2009;25(1):192–5.
- [123] Khanal A, Cui Y, Zhang L, Pelton R, Ren Y, Ketelson H, et al. Cationic liposome colloidal stability in the presence of guar derivatives suggests depletion interactions may be operative in artificial tears. *Biomacromolecules* 2010;11(9):2460–4.
- [124] Saarinen-Savolainen P, Järvinen T, Araki-Sasaki K, Watanabe H, Urtti A. Evaluation of cytotoxicity of various ophthalmic drugs, eye drop excipients and cyclodextrins in an immortalized human corneal epithelial cell line. *Pharm Res* 1998;15(8):1275–80.
- [125] Viaud-Quentric K, Lefranc-Jullien S, Feraille L, Elena PP. Long-term tolerance of preservative-free eye drops containing macrogol hydroxystearate as an excipient. *J Fr Ophtalmol* 2016;39(2):156–63.

- [126] Smedowski A, Paterno JJ, Toropainen E, Sinha D, Wylegala E, Kaarniranta K. Excipients of preservative-free latanoprost induced inflammatory response and cytotoxicity in immortalized human HCE-2 corneal epithelial cells. *J Biochem Pharmacol Res* 2014;2:175–84.
- [127] Gensheimer WG, Kleinman DM, Gonzalez MO, Sobti D, Cooper ER, Smits G, et al. Novel formulation of glycerin 1% artificial tears extends tear film break-up time compared with Systane lubricant eye drops. *J Ocul Pharmacol Ther* 2012;28(5):473–8.
- [128] Willcox MDP, Argüeso P, Georgiev GA, Holopainen JM, Laurie GW, Millar TJ, et al. TFOS DEWS II Tear Film report. *Ocul Surf* 2017;15:366–403.
- [129] Tiffany JM. Tears in health and disease. *Eye (Lond)* 2003;17(8):923–6.
- [130] Stahl U, Willcox M, Stapleton F. Osmolality and tear film dynamics. *Clin Exp Optom* 2012;95(1):3–11.
- [131] Schotanus MP, Koetje LR, Van Dyken RE, Ubels JL. Stratified corneal limbal epithelial cells are protected from UVB-induced apoptosis by elevated extracellular K⁺. *Exp Eye Res* 2011;93(5):735–40.
- [132] Ubels JL, Schotanus MP, Bardolph SL, Haarsma LD, Koetje LR, Louters JR. Inhibition of UV-B induced apoptosis in corneal epithelial cells by potassium channel modulators. *Exp Eye Res* 2010;90(2):216–22.
- [133] Green K, MacKeen DL, Slagle T, Cheeks L. Tear potassium contributes to maintenance of corneal thickness. *Ophthalmic Res* 1992;24(2):99–102.
- [134] Bachman WG, Wilson G. Essential ions for maintenance of the corneal epithelial surface. *Invest Ophthalmol Vis Sci* 1985;26(11):1484–8.
- [135] Smolin G, Foster CS, Azar DT, Dohlman CH. Smolin and Thoft's The Cornea: Scientific Foundations and Clinical Practice. 4th Lippincott Williams & Wilkins ed. Lippincott Williams & Wilkins; 2005.
- [136] Lopez Bernal D, Ubels JL. Artificial tear composition and promotion of recovery of the damaged corneal epithelium. *Cornea* 1993;12(2):115–20.
- [137] Ubels JL, McCartney MD, Lantz WK, Beaird J, Dayalan A, Edelhauser HF. Effects of preservative-free artificial tear solutions on corneal epithelial structure and function. *Arch Ophthalmol* 1995;113(3):371–8.
- [138] Craig JP, Tomlinson A. Importance of the lipid layer in human tear film stability and evaporation. *Optom Vis Sci* 1997;74(1):8–13.
- [139] Lee SY, Tong L. Lipid-containing lubricants for dry eye: a systematic review. *Optom Vis Sci* 2012;89(11):1654–61.
- [140] Moshirfar M, Pierson K, Hanamakai K, Santiago-Caban L, Muthappan V, Passi SF. Artificial tears potpourri: a literature review. *Clin Ophthalmol* 2014;8:1419–33.
- [141] Korb DR, Scaffidi RC, Greiner JV, Kenyon KR, Herman JP, Blackie CA, et al. The effect of two novel lubricant eye drops on tear film lipid layer thickness in subjects with dry eye symptoms. *Optom Vis Sci* 2005;82(7):594–601.
- [142] Scaffidi RC, Korb DR. Comparison of the efficacy of two lipid emulsion eyedrops in increasing tear film lipid layer thickness. *Eye Contact Lens* 2007;33(1):38–44.
- [143] Mason TG, Wilking JN, Meleson K, Chang CB, Graves SM. Nanoemulsions: formation, structure, and physical properties. *J Phys Condens Matter* 2006;18:R635.
- [144] Royle L, Matthews E, Corfield A, Berry M, Rudd PM, Dwek RA, et al. Glycan structures of ocular surface mucins in man, rabbit and dog display species differences. *Glycoconj J* 2008;25(8):763–73.
- [145] Daull P, Lallemand F, Garrigue JS. Benefits of cationic oil-in-water nanoemulsions for topical ophthalmic drug delivery. *J Pharm Pharmacol* 2014;66(4):531–41.
- [146] Amrane M, Creuzot-Garcher C, Robert PY, Ismail D, Garrigue JS, Pisella PJ, et al. Ocular tolerability and efficacy of a cationic emulsion in patients with mild to moderate dry eye disease - a randomised comparative study. *J Fr Ophthalmol* 2014;37(8):589–98.
- [147] Zhang W, Wang Y, Lee BT, Liu C, Wei G, Lu W. A novel nanoscale-dispersed eye ointment for the treatment of dry eye disease. *Nanotechnology* 2014;25(12):125101.
- [148] Lallemand F, Daull P, Benita S, Buggage R, Garrigue JS. Successfully improving ocular drug delivery using the cationic nanoemulsion, novasorb. *J Drug Deliv* 2012;2012:604204.
- [149] Kinnunen K, Kauppinen A, Piippo N, Koistinen A, Toropainen E, Kaarniranta K. Cationorm shows good tolerability on human HCE-2 corneal epithelial cell cultures. *Exp Eye Res* 2014;120:82–9.
- [150] Pinheiro R, Panfil C, Schrage N, Dutescu RM. Comparison of the lubricant eyedrops Optive®, Vismed Multi®, and Cationorm® on the corneal healing process in an ex vivo model. *Eur J Ophthalmol* 2015 Sep-Oct;25(5):379–84.
- [151] Yoncheva K, Vandervoort J, Ludwig A. Development of mucoadhesive poly(lactide-co-glycolide) nanoparticles for ocular application. *Pharm Dev Technol* 2011;16(1):29–35.
- [152] Paolicelli P, de la Fuente M, Sánchez A, Seijo B, Alonso MJ. Chitosan nanoparticles for drug delivery to the eye. *Expert Opin Drug Deliv* 2009;6(3):239–53.
- [153] De Campos AM, Sánchez A, Alonso MJ. Chitosan nanoparticles: a new vehicle for the improvement of the delivery of drugs to the ocular surface. Application to cyclosporin A. *Int J Pharm* 2001;224(1–2):159–68.
- [154] Rieger G. Lipid-containing eye drops: a step closer to natural tears. *Ophthalmologica* 1990;201(4):206–12.
- [155] Choi JH, Kim JH, Li Z, Oh HJ, Ahn KY, Yoon KC. Efficacy of the mineral oil and hyaluronic acid mixture eye drops in murine dry eye. *Korean J Ophthalmol* 2015;29(2):131–7.
- [156] Katzer T, Chaves P, Bernardi A, Pohlmann AR, Guterres SS, Beck RC. Castor oil and mineral oil nanoemulsion: development and compatibility with a soft contact lens. *Pharm Dev Technol* 2014;19(2):232–7.
- [157] Maïssa C, Guillon M, Simmons P, Vehige J. Effect of castor oil emulsion eyedrops on tear film composition and stability. *Cont Lens Anter Eye* 2010;33(2):76–82.
- [158] Moscovici BK, Holzchuh R, Chiacchio BB, Santo RM, Shimazaki J, Hida RY. Clinical treatment of dry eye using 0.03% tacrolimus eye drops. *Cornea* 2012;31(8):945–9.
- [159] Rantamäki AH, Javanainen M, Vattulainen I, Holopainen JM. Do lipids retard the evaporation of the tear fluid? *Invest Ophthalmol Vis Sci* 2012;53(10):6442–7.
- [160] Parrilha LR, Nai GA, Giuffrida R, Barbero RC, Padovani LD, Pereira RH, et al. Comparison of 1% cyclosporine eye drops in olive oil and in linseed oil to treat experimentally-induced keratoconjunctivitis sicca in rabbits. *Arq Bras Oftalmol* 2015 Sep-Oct;78(5):295–9.
- [161] Radomska-Soukharev A, Wojciechowska J. Microemulsions as potential ocular drug delivery systems: phase diagrams and physical properties depending on ingredients. *Acta Pol Pharm* 2005 Nov-Dec;62(6):465–71.
- [162] Greiner JV, Glonek T, Korb DR, Booth R, Leahy CD. Phospholipids in meibomian gland secretion. *Ophthalmic Res* 1996;28(1):44–9.
- [163] Dean AW, Glasgow BJ. Mass spectrometric identification of phospholipids in human tears and tear lipocalin. *Invest Ophthalmol Vis Sci* 2012;53(4):1773–82.
- [164] Ham BM, Cole RB, Jacob JT. Identification and comparison of the polar phospholipids in normal and dry eye rabbit tears by MALDI-TOF mass spectrometry. *Invest Ophthalmol Vis Sci* 2006;47(8):3330–8.
- [165] Shine WE, McCulley JP. Keratoconjunctivitis sicca associated with meibomian secretion polar lipid abnormality. *Arch Ophthalmol* 1998;116(7):849–52.
- [166] Chen J, Green-Church KB, Nichols KK. Shotgun lipidomic analysis of human meibomian gland secretions with electrospray ionization tandem mass spectrometry. *Invest Ophthalmol Vis Sci* 2010;51(12):6220–31.
- [167] Butovich IA, Uchiyama E, Di Pascuale MA, McCulley JP. Liquid chromatography-mass spectrometric analysis of lipids present in human meibomian gland secretions. *Lipids* 2007;42(8):765–76.
- [168] Butovich IA, Wojtowicz JC, Molai M. Human tear film and meibum. Very long chain wax esters and (O-acyl)-omega-hydroxy fatty acids of meibum. *J Lipid Res* 2009;50(12):2471–85.
- [169] Ham BM, Jacob JT, Cole RB. MALDI-TOF MS of phosphorylated lipids in biological fluids using immobilized metal affinity chromatography and a solid ionic crystal matrix. *Anal Chem* 2005;77(14):4439–47.
- [170] Saville JT, Zhao Z, Willcox MD, Ariyavidana MA, Blanksby SJ, Mitchell TW. Identification of phospholipids in human meibum by nano-electrospray ionisation tandem mass spectrometry. *Exp Eye Res* 2011;92(3):238–40.
- [171] Ham BM, Jacob JT, Keese MM, Cole RB. Identification, quantification and comparison of major non-polar lipids in normal and dry eye tear lipidomes by electrospray tandem mass spectrometry. *J Mass Spectrom* 2004;39(11):1321–36.
- [172] Pucker AD, Haworth KM. The presence and significance of polar meibum and tear lipids. *Ocul Surf* 2015;13(1):26–42.
- [173] Korb DR, Greiner JV, Glonek T. The effects of anionic and zwitterionic phospholipids on the tear film lipid layer. *Adv Exp Med Biol* 2002;506(Pt A):495–9.
- [174] Korb D, Stone R. Are phospholipids the critical ingredient? *Rev Cornea Contact Lens* 2012;149:38–41.
- [175] Nicolaidis N. Recent findings on the chemical composition of steer and human meibomian glands. In: Holly F, editor. *The Preocular Tear Film in Health, Disease, and Contact Lens Wear*. Lubbock, TX: Dry Eye Institute; 1986. p. 570–6.
- [176] McCulley JP, Shine W. A compositional based model for the tear film lipid layer. *Trans Am Ophthalmol Soc* 1997;95:79–88. discussion 88–93 discussion 93.
- [177] Wang IJ, Lin IC, Hou YC, Hu FR. A comparison of the effect of carbomer-, cellulose- and mineral oil-based artificial tear formulations. *Eur J Ophthalmol* 2007 Mar-Apr;17(2):151–9.
- [178] Craig JP, Purslow C, Murphy PJ, Wolffsohn JS. Effect of a liposomal spray on the pre-ocular tear film. *Cont Lens Anter Eye* 2010;33(2):83–7.
- [179] Wang TJ, Wang IJ, Ho JD, Chou HC, Lin SY, Huang MC. Comparison of the clinical effects of carbomer-based lipid-containing gel and hydroxypropyl-gel artificial tear formulations in patients with dry eye syndrome: a 4-week, prospective, open-label, randomized, parallel-group, noninferiority study. *Clin Ther* 2010;32(1):44–52.
- [180] Pult H, Gill F, Riede-Pult BH. Effect of three different liposomal eye sprays on ocular comfort and tear film. *Cont Lens Anter Eye* 2012;35: 203–7; quiz 43–4.
- [181] Mutalib HA, Kaur S, Ghazali AR, Chinn Hooi N, Safie NH. A pilot study: the efficacy of virgin coconut oil as ocular rewetting agent on rabbit eyes. *Evid Based Complement Altern Med* 2015;2015:135987.
- [182] Simmons PA, Carlisle-Wilcox C, Chen R, Liu H, Vehige JG. Efficacy, safety, and acceptability of a lipid-based artificial tear formulation: a randomized, controlled, multicenter clinical trial. *Clin Ther* 2015;37(4):858–68.
- [183] Ralph RA, Doane MG, Dohlman CH. Clinical experience with a mobile ocular perfusion pump. *Arch Ophthalmol* 1975;93(10):1039–43.
- [184] Semeraro F, Forbice E, Braga O, Bova A, Di Salvatore A, Azzolini C. Evaluation of the efficacy of 50% autologous serum eye drops in different ocular surface pathologies. *Biomed Res Int* 2014;2014:826970.

- [185] Tsubota K, Goto E, Fujita H, Ono M, Inoue H, Saito I, et al. Treatment of dry eye by autologous serum application in Sjögren's syndrome. *Br J Ophthalmol* 1999;83(4):390–5.
- [186] Hwang J, Chung SH, Jeon S, Kwok SK, Park SH, Kim MS. Comparison of clinical efficacies of autologous serum eye drops in patients with primary and secondary Sjögren syndrome. *Cornea* 2014;33(7):663–7.
- [187] Hondur AM, Akcam HT, Karaca EE, Yazici Eroglu H, Aydin B. Autologous serum eye drops accelerate epithelial healing after LASEK. *Curr Eye Res* 2016;41(1):15–9.
- [188] Sagara H, Iida T, Saito K, Noji H, Ogasawara M, Oyama H. Conservative treatment for late-onset bleb leaks after trabeculectomy with mitomycin C in patients with ocular surface disease. *Clin Ophthalmol* 2012;6:1273–9.
- [189] Ziakas NG, Boboridis KG, Terzidou C, Naoumidis TL, Mikropoulos D, Georgiadou EN, et al. Long-term follow up of autologous serum treatment for recurrent corneal erosions. *Clin Exp Ophthalmol* 2010;38(7):683–7.
- [190] Geerling G, Daniels JT, Dart JK, Cree IA, Khaw PT. Toxicity of natural tear substitutes in a fully defined culture model of human corneal epithelial cells. *Invest Ophthalmol Vis Sci* 2001;42:948–56.
- [191] Freire V, Andollo N, Etxebarria J, Hernáez-Moya R, Durán JA, Morales MC. Corneal wound healing promoted by 3 blood derivatives: an in vitro and in vivo comparative study. *Cornea* 2014;33(6):614–20.
- [192] Akyol-Salman I. Effects of autologous serum eye drops on corneal wound healing after superficial keratectomy in rabbits. *Cornea* 2006;25(10):1178–81.
- [193] Hartwig D, Harloff S, Liu L, Schlenke P, Wedel T, Geerling G. Epitheliotropic capacity of a growth factor preparation produced from platelet concentrates on corneal epithelial cells: a potential agent for the treatment of ocular surface defects? *Transfus Med* 2004;44(12):1724–31.
- [194] Hartwig D, Herminghaus P, Wedel T, Liu L, Schlenke P, Dibbelt L, et al. Topical treatment of ocular surface defects: comparison of the epitheliotropic capacity of fresh frozen plasma and serum on corneal epithelial cells in an in vitro cell culture model. *Transfus Med* 2005;15(2):107–13.
- [195] Esquenazi S, He J, Bazan HE, Bazan NG. Use of autologous serum in corneal epithelial defects post-lamellar surgery. *Cornea* 2005;24(8):992–7.
- [196] López-García JS, García-Lozano I, Rivas L, Giménez C, Acera A, Suárez-Cortés T. Effects of autologous serum eye drops on conjunctival expression of MUC5AC in patients with ocular surface disorders. *Cornea* 2016;35(3):336–41.
- [197] Watson SL, Secker GA, Daniels JT. The effect of therapeutic human serum drops on corneal stromal wound-healing activity. *Curr Eye Res* 2008;33(8):641–52.
- [198] Harloff S, Hartwig D, Kasper K, Wedel T, Muller M, Geerling G. Epitheliotropic capacity of serum eye drops from healthy donors versus serum from immunosuppressed patients with rheumatoid arthritis. *Klin Monbl Augenheilkd* 2008;225:200–6.
- [199] MacLennan S, Hartwig D, Geerling G. Experiences with a centralised national service for autologous serum eyedrops in England. *Ophthalmology* 2008;115:639–43.
- [200] Geerling G, MacLennan S, Hartwig D. Autologous serum eye drops for ocular surface disorders. *Br J Ophthalmol* 2004;88(11):1467–74.
- [201] Geerling G, Grus F, Seitz B, Hartwig D, Schirra F. Legal regulations to produce serum eye drops : when is it necessary, and how can it be obtained? *Ophthalmology* 2008;115:632–8.
- [202] Dietrich T, Weisbach V, Seitz B, Jacobi C, Kruse FE, Eckstein R, et al. Manufacture of autologous serum eye drops for out-patient therapy : cooperation between ophthalmic clinic and transfusion medicine department. *Ophthalmology* 2008;115:1036–8, 40–2.
- [203] Herminghaus P, Geerling G, Hartwig D, Wedel T, Dibbelt L. Epitheliotropic capacity of serum and plasma eyedrops. Influence of centrifugation. *Ophthalmology* 2004;111:998–1005.
- [204] Liu L, Hartwig D, Harloff S, Herminghaus P, Wedel T, Geerling G. An optimised protocol for the production of autologous serum eyedrops. *Graefes Arch Clin Exp Ophthalmol* 2005;243(7):706–14.
- [205] Partal A, Scott E. Low-cost protocol for the production of autologous serum eye drops by blood collection and processing centres for the treatment of ocular surface diseases. *Transfus Med* 2011;21(4):271–7.
- [206] Bradley JC, Simoni J, Bradley RH, McCartney DL, Brown SM. Time- and temperature-dependent stability of growth factor peptides in human autologous serum eye drops. *Cornea* 2009;28(2):200–5.
- [207] Fischer KR, Opitz A, Böeck M, Geerling G. Stability of serum eye drops after storage of 6 months. *Cornea* 2012;31(11):1313–8.
- [208] López-García JS, García-Lozano I, Rivas L, Ramírez N, Méndez MT, Raposo R. Stability of growth factors in autologous serum eyedrops after long-term storage. *Curr Eye Res* 2016;41(3):292–8.
- [209] Spaniol K, Koerschgen L, Sander O, Koegler G, Geerling G. Comparison of application systems for autologous serum eye drops. *Curr Eye Res* 2014;39(6):571–9.
- [210] Kasper K, Godenschweger L, Hartwig D, Unterlauff JD, Seitz B, Geerling G. On the use of autologous serum eyedrops in Germany : results of a survey among members of the Cornea Section of the German Ophthalmological Society (DOG). *Ophthalmology* 2008;115:644–9.
- [211] Dalmon CA, Chandra NS, Jeng BH. Use of autologous serum eyedrops for the treatment of ocular surface disease: first US experience in a large population as an insurance-covered benefit. *Arch Ophthalmol* 2012;130:1612–3.
- [212] Mondy P, Brama T, Fisher J, Gemelli CN, Chee K, Keegan A, et al. Sustained benefits of autologous serum eye drops on self-reported ocular symptoms and vision-related quality of life in Australian patients with dry eye and corneal epithelial defects. *Transfus Apher Sci* 2015;53(3):404–11.
- [213] Noble BA, Loh RS, MacLennan S, Pesudovs K, Reynolds A, Bridges LR, et al. Comparison of autologous serum eye drops with conventional therapy in a randomised controlled crossover trial for ocular surface disease. *Br J Ophthalmol* 2004;88:647–52.
- [214] Kojima T, Ishida R, Dogru M, Goto E, Matsumoto Y, Kaido M, et al. The effect of autologous serum eyedrops in the treatment of severe dry eye disease: a prospective randomized case-control study. *Am J Ophthalmol* 2005;139(2):242–6.
- [215] Noda-Tsuruya T, Asano-Kato N, Toda I, Tsubota K. Autologous serum eye drops for dry eye after LASIK. *J Refract Surg* 2006 Jan-Feb;22(1):61–6.
- [216] Yoon KC, Heo H, Im SK, You IC, Kim YH, Park YG. Comparison of autologous serum and umbilical cord serum eye drops for dry eye syndrome. *Am J Ophthalmol* 2007;144(1):86–92.
- [217] Urzua CA, Vasquez DH, Huidobro A, Hernandez H, Alfaro J. Randomized double-blind clinical trial of autologous serum versus artificial tears in dry eye syndrome. *Curr Eye Res* 2012;37(8):684–8.
- [218] Celebi AR, Ulusoy C, Mirza GE. The efficacy of autologous serum eye drops for severe dry eye syndrome: a randomized double-blind crossover study. *Graefes Arch Clin Exp Ophthalmol* 2014;252(4):619–26.
- [219] Hussain M, Shtein RM, Sugar A, Soong HK, Woodward MA, DeLoss K, et al. Long-term use of autologous serum 50% eye drops for the treatment of dry eye disease. *Cornea* 2014;33(12):1245–51.
- [220] Jirsova K, Brejchova K, Krabcova I, Filipec M, Al Fakh A, Palos M, et al. The application of autologous serum eye drops in severe dry eye patients: subjective and objective parameters before and after treatment. *Curr Eye Res* 2014;39(1):21–30.
- [221] López-García JS, García-Lozano I, Rivas L, Ramírez N, Raposo R, Méndez MT. Autologous serum eye drops diluted with sodium hyaluronate: clinical and experimental comparative study. *Acta Ophthalmol* 2014;92(1):e22–9.
- [222] Aggarwal S, Kheirkhah A, Cavalcanti BM, Cruzat A, Colon C, Brown E, et al. Autologous serum tears for treatment of photoallopecia in patients with corneal neuropathy: efficacy and evaluation with in vivo confocal microscopy. *Ocul Surf* 2015;13(3):250–62.
- [223] Li J, Zhang X, Zheng Q, Zhu Y, Wang H, Ma H, et al. Comparative evaluation of silicone hydrogel contact lenses and autologous serum for management of sjögren syndrome-associated dry eye. *Cornea* 2015;34(9):1072–8.
- [224] Mukhopadhyay S, Sen S, Datta H. Comparative role of 20% cord blood serum and 20% autologous serum in dry eye associated with Hansen's disease: a tear proteomic study. *Br J Ophthalmol* 2015;99(1):108–12.
- [225] Turkoglu Elif, Celik Erkan, Alagoz Gursoy. A comparison of the efficacy of autologous serum eye drops with amniotic membrane transplantation in neurotrophic keratitis. *Semin Ophthalmol* 2014;29(3):119–26.
- [226] Leite SC, de Castro RS, Alves M, Cunha DA, Correia ME, da Silveira LA, et al. Risk factors and characteristics of ocular complications, and efficacy of autologous serum tears after haematopoietic progenitor cell transplantation. *Bone Marrow Transpl* 2006;38(3):223–7.
- [227] Thanathane O, Phanphruk W, Anutarapongpan O, Romphruk A, Suwan-Apichon O. Contamination risk of 100% autologous serum eye drops in management of ocular surface diseases. *Cornea* 2013;32(8):1116–9.
- [228] Sanz-Marco E, Lopez-Prats MJ, Garcia-Delpech S, Udaondo P, Diaz-Llopis M. Fulminant bilateral Haemophilus influenzae keratitis in a patient with hypovitaminosis A treated with contaminated autologous serum. *Clin Ophthalmol* 2011;5:71–3.
- [229] Petznick A, Tong L, Chung R, Wang JC, Koh M, Salleh R, et al. Autologous plasma eyedrops prepared in a closed system: a treatment for dry eye. *Eye (Lond)* 2013;27(9):1102.
- [230] Chiang CC, Lin JM, Chen WL, Tsai YY. Allogeneic serum eye drops for the treatment of severe dry eye in patients with chronic graft-versus-host disease. *Cornea* 2007;26(7):861–3.
- [231] Na KS, Kim MS. Allogeneic serum eye drops for the treatment of dry eye patients with chronic graft-versus-host disease. *J Ocul Pharmacol Ther* 2012;28(5):479–83.
- [232] Hørring L, Nielsen C, Ullum H, Hansen MB, Julian HO. Ready-made allogeneic ABO-specific serum eye drops: production from regular male blood donors, clinical routine, safety and efficacy. *Acta Ophthalmol* 2014;92(8):783–6.
- [233] Badami KG, McKellar M. Allogeneic serum eye drops: time these became the norm? *Br J Ophthalmol* 2012;96(8):1151–2.
- [234] Yoon KC. Use of umbilical cord serum in ophthalmology. *Chonnam Med J* 2014;50(3):82–5.
- [235] Yoon KC, Im SK, Park YG, Jung YD, Yang SY, Choi J. Application of umbilical cord serum eyedrops for the treatment of dry eye syndrome. *Cornea* 2006;25(3):268–72.
- [236] Yoon KC, Jeong IY, Im SK, Park YG, Kim HJ, Choi J. Therapeutic effect of umbilical cord serum eyedrops for the treatment of dry eye associated with graft-versus-host disease. *Bone Marrow Transpl* 2007;39(4):231–5.
- [237] Liu L, Hartwig D, Harloff S, Herminghaus P, Wedel T, Kasper K, et al. Corneal epitheliotropic capacity of three different blood-derived preparations. *Invest Ophthalmol Vis Sci* 2006;47(6):2438–44.
- [238] Zallio F, Mazzucco L, Monaco F, Astori MR, Passera R, Drago G, et al. A single-center pilot prospective study of topical application of platelet-derived eye drops for patients with ocular chronic graft-versus-host disease. *Biol Blood*

- Marrow Transpl 2016;22(9):1664–70.
- [239] Fea AM, Aragno V, Testa V, Machetta F, Parisi S, D'Antico S, et al. The effect of autologous platelet lysate eye drops: an in vivo confocal microscopy study. *Biomed Res Int* 2016;2016:8406832.
- [240] Riestra AC, Alonso-Herreros JM, Merayo-Llodes J. *Arch Soc Esp Ophthalmol* 2016;91(10):475–90.
- [241] Anitua E, Muruzabal F, de la Fuente M, Riestra A, Merayo-Llodes J, Orive G. PRGF exerts more potent proliferative and anti-inflammatory effects than autologous serum on a cell culture inflammatory model. *Exp Eye Res* 2016;151:115–21.
- [242] Alio JL, Colecha JR, Pastor S, Rodriguez A, Artola A. Symptomatic dry eye treatment with autologous platelet-rich plasma. *Ophthalmic Res* 2007;39(3):124–9.
- [243] López-Plandolit S, Morales MC, Freire V, Grau AE, Durán JA. Efficacy of plasma rich in growth factors for the treatment of dry eye. *Cornea* 2011;30(12):1312–7.
- [244] Pezzotta S, Del Fante C, Scudeller L, Cervio M, Antoniazzi ER, Perotti C. Autologous platelet lysate for treatment of refractory ocular GVHD. *Bone Marrow Transpl* 2012;47(12):1558–63.
- [245] Ichikawa Y, Tokunaga M, Shimizu H, Moriuchi J, Takaya M, Arimori S. Clinical trial of ambroxol (Mucosolvan) in Sjögren's syndrome. *Tokai J Exp Clin Med* 1988;13(3):165–9.
- [246] Kerkscick C, Willoughby D. The antioxidant role of glutathione and N-acetylcysteine supplements and exercise-induced oxidative stress. *J Int Soc Sports Nutr* 2005;2:38–44.
- [247] Pokupec R, Petricek I, Sikic J, Bradic M, Popovic-Suic S, Petricek G. Comparison of local acetylcysteine and artificial tears in the management of dry eye syndrome. *Acta Med Croat* 2005;59:337–40.
- [248] Albietz J, Sanfilippo P, Troutbeck R, Lenton LM. Management of filamentary keratitis associated with aqueous-deficient dry eye. *Optom Vis Sci* 2003;80(6):420–30.
- [249] Pan Z, Wang Z, Yang H, Zhang F, Reinach PS. TRPV1 activation is required for hypertonicity-stimulated inflammatory cytokine release in human corneal epithelial cells. *Invest Ophthalmol Vis Sci* 2011;52(1):485–93.
- [250] Mergler S, Garreis F, Sahlmüller M, Lyras EM, Reinach PS, Dwarakanath A, et al. Calcium regulation by thermo- and osmosensing transient receptor potential vanilloid channels (TRPVs) in human conjunctival epithelial cells. *Histochem Cell Biol* 2012;137(6):743–61.
- [251] Benitez-Del-Castillo JM, Moreno-Montanes J, Jimenez-Alfaro I, Munoz-Negrete FJ, Turman K, Palumaa K, et al. Safety and efficacy clinical trials for SYL1001, a novel short interfering RNA for the treatment of dry eye disease. *Invest Ophthalmol Vis Sci* 2016;57:6447–54.
- [252] Kaido M, Ishida R, Dogru M, Tsubota K. Visual function changes after punctal occlusion with the treatment of short BUT type of dry eye. *Cornea* 2012;31(9):1009–13.
- [253] Chen F, Wang J, Chen W, Shen M, Xu S, Lu F. Upper punctal occlusion versus lower punctal occlusion in dry eye. *Invest Ophthalmol Vis Sci* 2010;51(11):5571–7.
- [254] Li M, Wang J, Shen M, Cui L, Tao A, Chen Z, et al. Effect of punctal occlusion on tear menisci in symptomatic contact lens wearers. *Cornea* 2012;31(9):1014–22.
- [255] Geldis JR, Nichols JJ. The impact of punctal occlusion on soft contact lens wearing comfort and the tear film. *Eye Contact Lens* 2008;34(5):261–5.
- [256] Alfawaz AM, Algehedan S, Jastaneiah SS, Al-Mansouri S, Mousa A, Al-Assiri A. Efficacy of punctal occlusion in management of dry eyes after laser in situ keratomileusis for myopia. *Curr Eye Res* 2014;39(3):257–62.
- [257] Yung YH, Toda I, Sakai C, Yoshida A, Tsubota K. Punctal plugs for treatment of post-LASIK dry eye. *Jpn J Ophthalmol* 2012;56(3):208–13.
- [258] Ambrósio Jr R, Tervo T, Wilson SE. LASIK-associated dry eye and neurotrophic epitheliopathy: pathophysiology and strategies for prevention and treatment. *J Refract Surg* 2008;24(4):396–407.
- [259] Yaguchi S, Ogawa Y, Kamoi M, Uchino M, Tatematsu Y, Ban Y, et al. Surgical management of lacrimal punctal cauterization in chronic GVHD-related dry eye with recurrent punctal plug extrusion. *Bone Marrow Transpl* 2012;47(11):1465–9.
- [260] Sabti S, Halter JP, Braun Fränkl BC, Goldblum D. Punctal occlusion is safe and efficient for the treatment of keratoconjunctivitis sicca in patients with ocular GVHD. *Bone Marrow Transpl* 2012;47(7):981–4.
- [261] Yang HY, Fujishima H, Toda I, Shimazaki J, Tsubota K. Lacrimal punctal occlusion for the treatment of superior limbic keratoconjunctivitis. *Am J Ophthalmol* 1997;124(1):80–7.
- [262] Tai MC, Cosar CB, Cohen EJ, Rapuano CJ, Laibson PR. The clinical efficacy of silicone punctal plug therapy. *Cornea* 2002;21(2):135–9.
- [263] Tong L, Beuerman R, Simonyi S, Hollander DA, Stern ME. Effects of punctal occlusion on clinical signs and symptoms and on tear cytokine levels in patients with dry eye. *Ocul Surf* 2016;14(2):233–41.
- [264] Goto E, Yagi Y, Kaido M, Matsumoto Y, Konomi K, Tsubota K. Improved functional visual acuity after punctal occlusion in dry eye patients. *Am J Ophthalmol* 2003;135(5):704–5.
- [265] Kimura K, Yokoi N, Inagaki K, Komuro A, Sonomura Y, Kato H, et al. Treatment progress of large-size puncta and clinical investigation of the extrusion rate and other complications associated with large-size punctal plugs. *Nippon Ganka Gakkai Zasshi* 2014;118:490–4.
- [266] Schaumberg DA, Uchino M, Christen WG, Semba RD, Buring JE, Li JZ. Patient reported differences in dry eye disease between men and women: impact, management, and patient satisfaction. *PLoS One* 2013;8:e76121.
- [267] Yokoi N, Komuro A. Non-invasive methods of assessing the tear film. *Exp Eye Res* 2004;78(3):399–407.
- [268] Chen F, Shen M, Chen W, Wang J, Li M, Yuan Y, et al. Tear meniscus volume in dry eye after punctal occlusion. *Invest Ophthalmol Vis Sci* 2010;51(4):1965–9.
- [269] Foulks GN, Forstot SL, Donshik PC, Forstot JZ, Goldstein MH, Lemp MA, et al. Clinical guidelines for management of dry eye associated with Sjögren disease. *Ocul Surf* 2015;13(2):118–32.
- [270] Hirai K, Takano Y, Uchio E, Kadosono K. Clinical evaluation of the therapeutic effects of atelocollagen absorbable punctal plugs. *Clin Ophthalmol* 2012;6:133–8.
- [271] Hamano T. Atelocollagen punctal occlusion for the treatment of the dry eye. *Adv Exp Med Biol* 2002;506(Pt B):1283–4.
- [272] Miyata K, Otani S, Miyai T, Nejima R, Amano S. Atelocollagen punctal occlusion in dry eye patients. *Cornea* 2006;25(1):47–50.
- [273] Hadassah J, Bhuvaneshwari N, Singh D, Sehgal PK. Preparation and clinical evaluation of succinylated collagen punctal plugs in dry eye syndrome: a pilot study. *Ophthalmic Res* 2010;43(4):185–92.
- [274] Capita L, Chalita MR, dos Santos-Neto LL. Prospective evaluation of hypromellose 2% for punctal occlusion in patients with dry eye. *Cornea* 2015;34(2):188–92.
- [275] Mazow ML, McCall T, Prager TC. Lodged intracanalicular plugs as a cause of lacrimal obstruction. *Ophthalm Plast Reconstr Surg* 2007 Mar-Apr;23(2):138–42.
- [276] ClinicalTrialsWebsite. Tolerability, Safety and Efficacy of Lubricin (150 µg/ml) Eye Drops Versus Sodium Hyaluronate (HA) 0.18% Eye Drops in Patients With Moderate Dry Eye (DE). <https://clinicaltrials.gov/ct2/show/NCT02507934?term=lubricin&rank=22015>.
- [277] Egrilmez S, Aslan F, Karabulut G, Kabasakal Y, Yagci A. Clinical efficacy of the SmartPlug™ in the treatment of primary Sjögren's syndrome with keratoconjunctivitis sicca: one-year follow-up study. *Rheumatol Int* 2011;31(12):1567–70.
- [278] SmartPlug Study G. Management of complications after insertion of the SmartPlug punctal plug: a study of 28 patients. *Ophthalmology* 2006;113(1859):e1–6.
- [279] Rabensteiner DF, Boldin I, Klein A, Horwath-Winter J. Collared silicone punctal plugs compared to intracanalicular plugs for the treatment of dry eye. *Curr Eye Res* 2013;38(5):521–5.
- [280] Joganathan V, Mehta P, Murray A, Durrani OM. Complications of intracanalicular plugs: a case series. *Orbit* 2010;29(5):271–3.
- [281] Murube J, Murube E. Treatment of dry eye by blocking the lacrimal canaliculi. *Surv Ophthalmol* 1996 May-Jun;40(6):463–80.
- [282] Patten JT. Punctal occlusion with n-butyl cyanoacrylate tissue adhesive. *Ophthalmic Surg* 1976;7(2):24–6.
- [283] Balaram M, Schaumberg DA, Dana MR. Efficacy and tolerability outcomes after punctal occlusion with silicone plugs in dry eye syndrome. *Am J Ophthalmol* 2001;131(1):30–6.
- [284] Nishii M, Yokoi N, Komuro A, Kinoshita S. Clinical investigation of extrusion of a new punctal plug (Flex Plug). *Nippon Ganka Gakkai Zasshi* 2004;108:139–43.
- [285] Nishii M, Yokoi N, Komuro A, Sugita J, Nakamura Y, Kojima K, et al. Comparison of extrusion rate for two different design of punctal plugs. *Nippon Ganka Gakkai Zasshi* 2003;107:322–5.
- [286] Sonomura Y, Yokoi N, Komuro A, Inagaki K, Kinoshita S. Clinical investigation of the extrusion rate and other complications of the SuperEagle plug. *Nippon Ganka Gakkai Zasshi* 2013;117:126–31.
- [287] Horwath-Winter J, Thaci A, Gruber A, Boldin I. Long-term retention rates and complications of silicone punctal plugs in dry eye. *Am J Ophthalmol* 2007;144(3):441–4.
- [288] Kaido M, Ishida R, Dogru M, Tsubota K. Comparison of retention rates and complications of 2 different types of silicon lacrimal punctal plugs in the treatment of dry eye disease. *Am J Ophthalmol* 2013;155:648–53. 53 e1.
- [289] Sakamoto A, Kitagawa K, Tatami A. Efficacy and retention rate of two types of silicone punctal plugs in patients with and without Sjögren syndrome. *Cornea* 2004;23(3):249–54.
- [290] Rumelt S, Remulla H, Rubin PA. Silicone punctal plug migration resulting in dacryocystitis and canaliculitis. *Cornea* 1997;16(3):377–9.
- [291] Scheepers M, Pearson A, Michaelides M. Bilateral canaliculitis following SmartPLUG insertion for dry eye syndrome post LASIK surgery. *Graefes Arch Clin Exp Ophthalmol* 2007;245(6):895–7.
- [292] Yokoi N, Okada K, Sugita J, Kinoshita S. Acute conjunctivitis associated with biofilm formation on a punctal plug. *Jpn J Ophthalmol* 2000 Sep-Oct;44(5):559–60.
- [293] Ahn HB, Seo JW, Roh MS, Jeong WJ, Park WC, Rho SH. Canaliculitis with a papilloma-like mass caused by a temporary punctal plug. *Ophthalm Plast Reconstr Surg* 2009 Sep-Oct;25(5):413–4.
- [294] Bourkiza R, Lee V. A review of the complications of lacrimal occlusion with punctal and canalicular plugs. *Orbit* 2012;31(2):86–93.
- [295] Dohman CH. Punctal occlusion in keratoconjunctivitis sicca. *Ophthalmology* 1978;85(12):1277–81.
- [296] Geerling G, Tost FH. Surgical occlusion of the lacrimal drainage system. *Dev Ophthalmol* 2008;41:213–29.
- [297] Ohba E, Dogru M, Hosaka E, Yamazaki A, Asaga R, Tatematsu Y, et al. Surgical punctal occlusion with a high heat-energy releasing cautery device for

- severe dry eye with recurrent punctal plug extrusion. *Am J Ophthalmol* 2011;151(3):483–7. e1.
- [298] Holzchuh R, Villa Albers MB, Osaki TH, Igami TZ, Santo RM, Kara-Jose N, et al. Two-year outcome of partial lacrimal punctal occlusion in the management of dry eye related to Sjögren syndrome. *Curr Eye Res* 2011;36(6):507–12.
- [299] Yazici B, Bilge AD, Naqadan F. Lacrimal Punctal Occlusion With Conjunctival Flap. *Ophthal Plast Reconstr Surg* 2015 Jul-Aug;31(4):300–2.
- [300] Panagopoulos A, Chalioulias K, Ramsay AS. 'Punctal switch' grafting for the treatment of dry eyes: our experience. *Ophthalmic Res* 2011;46(4):218–20.
- [301] Obata H, Ibaraki N, Tsuru T. A technique for preventing spontaneous loss of lacrimal punctal plugs. *Am J Ophthalmol* 2006;141(3):567–9.
- [302] Putterman AM. Canalicularotomy in the treatment of keratitis sicca. *Ophthalmic Surg* 1991;22(8):478–80.
- [303] DeMartelaere SL, Blyndon SM, Tovilla-Canales JL, Shore JW. A permanent and reversible procedure to block tear drainage for the treatment of dry eye. *Ophthal Plast Reconstr Surg* 2006 Sep-Oct;22(5):352–5.
- [304] Kaido M, Goto E, Dogru M, Tsubota K. Punctal occlusion in the management of chronic Stevens-Johnson syndrome. *Ophthalmology* 2004;111(5):895–900.
- [305] Knapp ME, Frueh BR, Nelson CC, Musch DC. A comparison of two methods of punctal occlusion. *Am J Ophthalmol* 1989;108(3):315–8.
- [306] Roberts CW, Carniglia PE, Brazzo BG. Comparison of topical cyclosporine, punctal occlusion, and a combination for the treatment of dry eye. *Cornea* 2007;26(7):805–9.
- [307] Ervin AM, Wojciechowski R, Schein O. Punctal occlusion for dry eye syndrome. *Cochrane Database Syst Rev* 2010;(9):CD006775.
- [308] Kojima K, Yokoi N, Nakamura Y, Takada Y, Sato H, Komuro A, et al. Outcome of punctal plug occlusion therapy for severe dry eye syndrome. *Nippon Ganka Gakkai Zasshi* 2002;106:360–4.
- [309] Nava-Castaneda A, Tovilla-Canales JL, Rodriguez L, Tovilla Y Pomar JL, Jones CE. Effects of lacrimal occlusion with collagen and silicone plugs on patients with conjunctivitis associated with dry eye. *Cornea* 2003;22(1):10–4.
- [310] Farrell J, Patel S, Grierson DG, Sturrock RD. A clinical procedure to predict the value of temporary occlusion therapy in keratoconjunctivitis sicca. *Ophthalmic Physiol Opt* 2003;23(1):1–8.
- [311] Altan-Yaycioglu R, Gencoglu EA, Akova YA, Dursun D, Cengiz F, Akman A. Silicone versus collagen plugs for treating dry eye: results of a prospective randomized trial including lacrimal scintigraphy. *Am J Ophthalmol* 2005;140(1):88–93.
- [312] Chen SX, Lee GA. SmartPlug in the management of severe dry eye syndrome. *Cornea* 2007;26(5):534–8.
- [313] Shi S, Chen W, Zhang X, Ma HX, Sun L. Effects of silicone punctal plugs for tear deficiency dry eye patients. *Zhonghua Yan Ke Za Zhi* 2013;49:151–4.
- [314] Savar DE. A new approach to ocular moisture chambers. *J Pediatr Ophthalmol Strabismus* 1978 Jan-Feb;15(1):51–3.
- [315] Gresset J, Simonet P, Gordon D. Combination of a side shield with an ocular moisture chamber. *Am J Optom Physiol Opt* 1984;61(9):610–2.
- [316] Shen G, Qi Q, Ma X. Effect of Moisture Chamber Spectacles on Tear Functions in Dry Eye Disease. *Optom Vis Sci* 2016;93(2):158–64.
- [317] Craig J, Chan E, Ea L, Kam C, Lu Y, Misra S. Dry eye relief for VDU users from a USB-desktop humidifier. *Contact Lens Anter Eye* 2012;35:28. e-abstract.
- [318] Shigeyasu C, Hirano S, Akune Y, Yamada M. Diquafosol Tetrasodium Increases the Concentration of Mucin-like Substances in Tears of Healthy Human Subjects. *Curr Eye Res* 2015;40(9):878–83.
- [319] Fujihara T, Murakami T, Nagano T, Nakamura M, Nakata K. INS365 suppresses loss of corneal epithelial integrity by secretion of mucin-like glycoprotein in a rabbit short-term dry eye model. *J Ocul Pharmacol Ther* 2002;18(4):363–70.
- [320] Lau OC, Samarawickrama C, Skalicky SE. P2Y2 receptor agonists for the treatment of dry eye disease: a review. *Clin Ophthalmol* 2014;8:327–34.
- [321] Gong L, Sun X, Ma Z, Wang Q, Xu X, Chen X, et al. A randomised, parallel-group comparison study of diquafosol ophthalmic solution in patients with dry eye in China and Singapore. *Br J Ophthalmol* 2015;99(7):903–8.
- [322] Bremond-Gignac D, Gicquel JJ, Chiambaretta F. Pharmacokinetic evaluation of diquafosol tetrasodium for the treatment of Sjögren's syndrome. *Expert Opin Drug Metab Toxicol* 2014;10(6):905–13.
- [323] Koh S, Ikeda C, Takai Y, Watanabe H, Maeda N, Nishida K. Long-term results of treatment with diquafosol ophthalmic solution for aqueous-deficient dry eye. *Jpn J Ophthalmol* 2013;57(5):440–6.
- [324] Shimazaki-Den S, Iseda H, Dogru M, Shimazaki J. Effects of diquafosol sodium eye drops on tear film stability in short BUT type of dry eye. *Cornea* 2013;32(8):1120–5.
- [325] Yamaguchi M, Nishijima T, Shimazaki J, Takamura E, Yokoi N, Watanabe H, et al. Real-world assessment of diquafosol in dry eye patients with risk factors such as contact lens, meibomian gland dysfunction, and conjunctivochalasis: subgroup analysis from a prospective observational study. *Clin Ophthalmol* 2015;9:2251–6.
- [326] Mori Y, Nejima R, Masuda A, Maruyama Y, Minami K, Miyata K, et al. Effect of diquafosol tetrasodium eye drop for persistent dry eye after laser in situ keratomileusis. *Cornea* 2014;33(7):659–62.
- [327] Park DH, Chung JK, Seo du R, Lee SJ. Clinical Effects and Safety of 3% Diquafosol Ophthalmic Solution for Patients With Dry Eye After Cataract Surgery: A Randomized Controlled Trial. *Am J Ophthalmol* 2016;163:122–31. e2.
- [328] Byun YS, Yoo YS, Kwon JY, Joo JS, Lim SA, Whang WJ, et al. Diquafosol promotes corneal epithelial healing via intracellular calcium-mediated ERK activation. *Exp Eye Res* 2016;143:89–97.
- [329] Chao W, Belmonte C, Benitez Del Castillo JM, Bron AJ, Dua HS, Nichols KK, et al. Report of the Inaugural Meeting of the TFOS i(2) = initiating innovation Series: Targeting the Unmet Need for Dry Eye Treatment. *Ocul Surf* 2016;14(2):264–316.
- [330] Samudre S, Lattanzio Jr FA, Lossen V, Hosseini A, Sheppard Jr JD, McKown RL, et al. Lacritin, a novel human tear glycoprotein, promotes sustained basal tearing and is well tolerated. *Invest Ophthalmol Vis Sci* 2011;52(9):6265–70.
- [331] Vijmasi T, Chen FY, Balasubbu S, Gallup M, McKown RL, Laurie GW, et al. Topical administration of lacritin is a novel therapy for aqueous-deficient dry eye disease. *Invest Ophthalmol Vis Sci* 2014;55(8):5401–9.
- [332] Itoh S, Itoh K, Shinohara H. Regulation of human corneal epithelial mucins by rebamipide. *Curr Eye Res* 2014;39(2):133–41.
- [333] Kinoshita S, Awamura S, Nakamichi N, Suzuki H, Oshiden K, Yokoi N, et al. A multicenter, open-label, 52-week study of 2% rebamipide (OPC-12759) ophthalmic suspension in patients with dry eye. *Am J Ophthalmol* 2014;157(3):576–83. e1.
- [334] Koh S, Inoue Y, Sugimoto T, Maeda N, Nishida K. Effect of rebamipide ophthalmic suspension on optical quality in the short break-up time type of dry eye. *Cornea* 2013;32(9):1219–23.
- [335] Itakura H, Kashima T, Itakura M, Akiyama H, Kishi S. Topical rebamipide improves lid wiper epitheliopathy. *Clin Ophthalmol* 2013;7:2137–41.
- [336] Sasaki H, Kokubun T. Alkali burn treated with 2% rebamipide ophthalmic suspension: a case report. *Case Rep Ophthalmol* 2014 Sep-Dec;5(3):380–5.
- [337] Kashima T, Itakura H, Akiyama H, Kishi S. Rebamipide ophthalmic suspension for the treatment of dry eye syndrome: a critical appraisal. *Clin Ophthalmol* 2014;8:1003–10.
- [338] Igarashi A, Kamiya K, Kobashi H, Shimizu K. Effect of Rebamipide Ophthalmic Suspension on Intraocular Light Scattering for Dry Eye After Corneal Refractive Surgery. *Cornea* 2015;34(8):895–900.
- [339] Uchino Y, Mauris J, Woodward AM, Dieckow J, Amparo F, Dana R, et al. Alteration of galectin-3 in tears of patients with dry eye disease. *Am J Ophthalmol* 2015;159(6):1027–35. e3.
- [340] Nakamura T, Hata Y, Nagata M, Yokoi N, Yamaguchi S, Kaku T, et al. JBP485 promotes tear and mucin secretion in ocular surface epithelia. *Sci Rep* 2015;5:10248.
- [341] He H, Ding H, Liao A, Liu Q, Yang J, Zhong X. Effects of mycophenolate mofetil on proliferation and mucin-5AC expression in human conjunctival goblet cells in vitro. *Mol Vis* 2010;16:1913–9.
- [342] Yang YM, Park S, Ji H, Kim TI, Kim EK, Kang KK, et al. DA-6034 Induces [Ca²⁺]_i Increase in Epithelial Cells. *Korean J Physiol Pharmacol* 2014;18:89–94.
- [343] Choi SM, Seo MJ, Lee YG, Lee MJ, Jeon HJ, Kang KK, et al. Effects of DA-6034, a flavonoid derivative, on mucin-like glycoprotein and ocular surface integrity in a rabbit model. *Arzneimittelforschung* 2009;59(10):498–503.
- [344] Schulze U, Sel S, Paulsen FP. Trefoil factor family peptide 3 at the ocular surface. A promising therapeutic candidate for patients with dry eye syndrome? *Dev Ophthalmol* 2010;45:1–11.
- [345] Schulze U, Hampel U, Sel S, Contreras-Ruiz L, Schicht M, Dieckow J, et al. Trefoil factor family peptide 3 (TFF3) is upregulated under experimental conditions similar to dry eye disease and supports corneal wound healing effects in vitro. *Invest Ophthalmol Vis Sci* 2014;55(5):3037–42.
- [346] Lambiasi A, Micera A, Pellegrini G, Merlo D, Rama P, De Luca M, et al. In vitro evidence of nerve growth factor effects on human conjunctival epithelial cell differentiation and mucin gene expression. *Invest Ophthalmol Vis Sci* 2009;50(10):4622–30.
- [347] Ding J, Sullivan DA. The effects of insulin-like growth factor 1 and growth hormone on human meibomian gland epithelial cells. *JAMA Ophthalmol* 2014;132(5):593–9.
- [348] Schirra F, Suzuki T, Richards SM, Jensen RV, Liu M, Lombardi MJ, et al. Androgen control of gene expression in the mouse meibomian gland. *Invest Ophthalmol Vis Sci* 2005;46(10):3666–75.
- [349] Schirra F, Richards SM, Liu M, Suzuki T, Yamagami H, Sullivan DA. Androgen regulation of lipogenic pathways in the mouse meibomian gland. *Exp Eye Res* 2006;83(2):291–6.
- [350] Sullivan DA, Jensen RV, Suzuki T, Richards SM. Do sex steroids exert sex-specific and/or opposite effects on gene expression in lacrimal and meibomian glands? *Mol Vis* 2009;15:1553–72.
- [351] Khandelwal P, Liu S, Sullivan DA. Androgen regulation of gene expression in human meibomian gland and conjunctival epithelial cells. *Mol Vis* 2012;18:1055–67.
- [352] Schiffman R, Bradford R, Bunnell B, Lai F, Bernstein P, Whitcup S. A multi-center, double-masked, randomized, vehicle-controlled, parallel group study to evaluate the safety and efficacy of testosterone ophthalmic solution in patients with meibomian gland dysfunction. *Invest Ophthalmol Vis Sci* 2006;47. ARVO e-abstract #5608.
- [353] Sullivan DA, Rocha EM, Aragona P, Clayton JA, Ding J, Golebiowski B, et al. TFOS DEWS II Sex, Gender, and Hormones report. *Ocul Surf* 2017;15:284–333.
- [354] Tsifetaki N, Kitsos G, Paschides CA, Alamanos Y, Eftaxias V, Voulgari PV, et al. Oral pilocarpine for the treatment of ocular symptoms in patients with Sjögren's syndrome: a randomized 12 week controlled study. *Ann Rheum Dis* 2003;62(12):1204–7.

- [355] Kawakita T, Shimmura S, Tsubota K. Effect of Oral Pilocarpine in Treating Severe Dry Eye in Patients With Sjögren Syndrome. *Asia Pac J Ophthalmol Phila* 2015 Mar-Apr;4(2):101–5.
- [356] Aragona P, Di Pietro R, Spinella R, Mabruci M. Conjunctival epithelium improvement after systemic pilocarpine in patients with Sjögren's syndrome. *Br J Ophthalmol* 2006;90(2):166–70.
- [357] Ibrahim OM, Dogru M, Kawashima S, Wakamatsu TH, Tsubota K, Fujishima H. Visante optical coherence tomography and tear function test evaluation of cholinergic treatment response in patients with sjögren syndrome. *Cornea* 2013;32(5):653–7.
- [358] Noaiseh G, Baker JF, Vivino FB. Comparison of the discontinuation rates and side-effect profiles of pilocarpine and cevimeline for xerostomia in primary Sjögren's syndrome. *Clin Exp Rheumatol* 2014 Jul-Aug;32(4):575–7.
- [359] Petrone D, Condemi JJ, Fife R, Gluck O, Cohen S, Dalgin P. A double-blind, randomized, placebo-controlled study of cevimeline in Sjögren's syndrome patients with xerostomia and keratoconjunctivitis sicca. *Arthritis Rheum* 2002;46(3):748–54.
- [360] Ono M, Takamura E, Shinozaki K, Tsumura T, Hamano T, Yagi Y, et al. Therapeutic effect of cevimeline on dry eye in patients with Sjögren's syndrome: a randomized, double-blind clinical study. *Am J Ophthalmol* 2004;138(1):6–17.
- [361] Ramos-Casals M, Tzioufas AG, Stone JH, Siso A, Bosch X. Treatment of primary Sjögren syndrome: a systematic review. *JAMA* 2010;304:452–60.
- [362] Akpek EK, Lindsley KB, Adyanthaya RS, Swamy R, Baer AN, McDonnell PJ. Treatment of Sjögren's syndrome-associated dry eye: an evidence-based review. *Ophthalmology* 2011;118(7):1242–52.
- [363] Kossler AL, Wang J, Feuer W, Ts DT. Neurostimulation of the lacrimal nerve for enhanced tear production. *Ophthalm Plast Reconstr Surg* 2015 Mar-Apr;31(2):145–51.
- [364] Famm K, Litt B, Tracey KJ, Boyden ES, Slaoui M. Drug discovery: a jump-start for electroceuticals. *Nature* 2013;496(7444):159–61.
- [365] Hydn D, Arlinger S. On the sneeze-reflex and its control. *Rhinology* 2007;45(3):218–9.
- [366] Gumus K, Pflugfelder SC. Intranasal Tear Neurostimulation: An Emerging Concept in the Treatment of Dry Eye. *Int Ophthalmol Clin* 2017;57(2):101–8.
- [367] Baroody FM. How nasal function influences the eyes, ears, sinuses, and lungs. *Proc Am Thorac Soc* 2011;8(1):53–61.
- [368] Gupta A, Heigle T, Pflugfelder SC. Nasolacrimal stimulation of aqueous tear production. *Cornea* 1997;16(6):645–8.
- [369] Friedman NJ, Butron K, Robledo N, Loudin J, Baba SN, Chayet A. A non-randomized, open-label study to evaluate the effect of nasal stimulation on tear production in subjects with dry eye disease. *Clin Ophthalmol* 2016;10:795–804.
- [370] Gumus K, Schuetzle KL, Pflugfelder SC. Randomized Controlled Crossover Trial Comparing the Impact of Sham or Intranasal Tear Neurostimulation on Conjunctival Goblet Cell Degranulation. *Am J Ophthalmol* 2017;177:159–68.
- [371] Craig JP, Cohn G, Corbett D, Tenen A, Coroneo M, McAlister J, et al. Evaluating the Safety and Efficacy of Intranasal Neurostimulation for Dry Eye Disease: A Double-masked, Randomized, Controlled, Multicenter Study. *Optom Vis Sci* 2016;94:160041. E-abstract.
- [372] Craig JP, Friedman N, Torkildsen G, Ackermann M. Symptom Reduction with Oculvee Intranasal Stimulator on Exposure to Environmental Challenge in Dry Eye: A Randomized, Controlled, Crossover Trial. *Optom Vis Sci* 2016;94:160057. E-abstract.
- [373] Sano K, Kawashima M, Ikeura K, Arita R, Tsubota K. Abdominal breathing increases tear secretion in healthy women. *Ocul Surf* 2015;13(1):82–7.
- [374] Hirata H, Meng ID. Cold-sensitive corneal afferents respond to a variety of ocular stimuli central to tear production: implications for dry eye disease. *Invest Ophthalmol Vis Sci* 2010;51(8):3969–76.
- [375] Belmonte C, Gallar J. Cold thermoreceptors, unexpected players in tear production and ocular dryness sensations. *Invest Ophthalmol Vis Sci* 2011;52(6):3888–92.
- [376] Nilius B, Voets T. Neurophysiology: channelling cold reception. *Nature* 2007;448(7150):147–8.
- [377] Kovács I, Luna C, Quirce S, Mizerska K, Callejo G, Riestra A, et al. Abnormal activity of corneal cold thermoreceptors underlies the unpleasant sensations in dry eye disease. *Pain* 2016;157(2):399–417.
- [378] Osei KA, Ovenseri-Ogbomo G, Kyei S, Ntodie M. The effect of caffeine on tear secretion. *Optom Vis Sci* 2014;91(2):171–7.
- [379] Bron AJ, Benjamin L, Bilaniuk LT. Meibomian gland disease. Classification and grading of lid changes. *Eye* 1991;5(4):395–411.
- [380] Green-Church KB, Butovich I, Willcox M, Borchman D, Paulsen F, Barabino S, et al. The international workshop on meibomian gland dysfunction: report of the subcommittee on tear film lipids and lipid-protein interactions in health and disease. *Invest Ophthalmol Vis Sci* 2011;52(4):1979–93.
- [381] McCulley JP, Dougherty JM, Deneau DG. Classification of chronic blepharitis. *Ophthalmology* 1982;89(10):1173–80.
- [382] McCulley JP, Shine WE. Changing concepts in the diagnosis and management of blepharitis. *Cornea* 2000;19(5):650–8.
- [383] Nichols KK. The international workshop on meibomian gland dysfunction: introduction. *Invest Ophthalmol Vis Sci* 2011;52(4):1917–21.
- [384] Nichols KK, Foulks GN, Bron AJ, Glasgow BJ, Dogru M, Tsubota K, et al. The international workshop on meibomian gland dysfunction: executive summary. *Invest Ophthalmol Vis Sci* 2011;52(4):1922–9.
- [385] Smith RE, Flowers Jr CW. Chronic blepharitis: a review. *CLAO J* 1995;21(3):200–7.
- [386] Key JE. A comparative study of eyelid cleaning regimens in chronic blepharitis. *CLAO J* 1996;22(3):209–12.
- [387] Romero JM, Biser SA, Perry HD, Levinson DH, Doshi SJ, Terraciano A, et al. Conservative treatment of meibomian gland dysfunction. *Eye Contact Lens* 2004;30(1):14–9.
- [388] Craig JP, Sung J, Wang MT, Cheung I, Sherwin T, Ismail S. Commercial lid cleanser outperforms baby shampoo for management of blepharitis in randomized, double-masked clinical trial. *Invest Ophthalmol Vis Sci* 2017;58. E-abstract 2247–B0014.
- [389] Geerling G, Tauber J, Baudouin C, Goto E, Matsumoto Y, O'Brien T, et al. The international workshop on meibomian gland dysfunction: report of the subcommittee on management and treatment of meibomian gland dysfunction. *Invest Ophthalmol Vis Sci* 2011;52(4):2050–64.
- [390] Alghamdi YA, Camp A, Feuer W, Karp CL, Wellik S, Galor A. Compliance and Subjective Patient Responses to Eyelid Hygiene. *Eye Contact Lens* 2017. In press.
- [391] Coroneo MT, Rosenberg ML, Cheung LM. Ocular effects of cosmetic products and procedures. *Ocul Surf* 2006;4(2):94–102.
- [392] Goto T, Zheng X, Gibbon L, Ohashi Y. Cosmetic product migration onto the ocular surface: exacerbation of migration after eyedrop instillation. *Cornea* 2010;29(4):400–3.
- [393] Ng A, Evans K, North RV, Purslow C. Migration of Cosmetic Products into the Tear Film. *Eye Contact Lens* 2015;41(5):304–9.
- [394] Paugh JR, Knapp LL, Martinson JR, Hom MM. Meibomian therapy in problematic contact lens wear. *Optom Vis Sci* 1990;67(11):803–6.
- [395] Guillon M, Maissa C, Wong S. Eyelid margin modification associated with eyelid hygiene in anterior blepharitis and meibomian gland dysfunction. *Eye Contact Lens* 2012;38(5):319–25.
- [396] Guillon M, Maissa C, Wong S. Symptomatic relief associated with eyelid hygiene in anterior blepharitis and MGD. *Eye Contact Lens* 2012;38(5):306–12.
- [397] Doan S. Tolerability and acceptability of Blephagel: a novel eyelid hygiene aqueous gel. *Clin Ophthalmol* 2012;6:71–7.
- [398] Khairuddin R, Hueber A. Eyelid hygiene for contact lens wearers with blepharitis. Comparative investigation of treatment with baby shampoo versus phospholipid solution. *Ophthalmologie* 2013;110:146–53.
- [399] Arrúa M, Samudio M, Fariña N, Cibils D, Laspina F, Sanabria R, et al. Comparative study of the efficacy of different treatment options in patients with chronic blepharitis. *Arch Soc Esp Oftalmol* 2015;90(3):112–8.
- [400] Ngo W, Srinivasan S, Houtman D, Jones L. The relief of dry eye signs and symptoms using a combination of lubricants, lid hygiene and ocular nutraceuticals. *J Optom* 2017;10(1):26–33.
- [401] Benitez-Del-Castillo JM. How to promote and preserve eyelid health. *Clin Ophthalmol* 2012;6:1689–98.
- [402] Needle JJ, Petchey R, Lawrenson JG. A survey of the scope of therapeutic practice by UK optometrists and their attitudes to an extended prescribing role. *Ophthalmic Physiol Opt* 2008;28(3):193–203.
- [403] Jackson WB. Management of dysfunctional tear syndrome: a Canadian consensus. *Can J Ophthalmol* 2009;44(4):385–94.
- [404] Zhao YE, Wu LP, Hu L, Xu JR. Association of blepharitis with Demodex: a meta-analysis. *Ophthalmic Epidemiol* 2012;19(2):95–102.
- [405] Junk AK, Lukacs A, Kampik A. Topical administration of metronidazole gel as an effective therapy alternative in chronic Demodex blepharitis—a case report. *Klin Monbl Augenheilkd* 1998;213:48–50.
- [406] Czepita D, Kuzna-Grygiel W, Czepita M, Grobelny A. Demodex folliculorum and Demodex brevis as a cause of chronic marginal blepharitis. *Ann Acad Med Stetin* 2007;53:63–7. discussion 7.
- [407] Fulk GW, Clifford C. A case report of demodicosis. *J Am Optom Assoc* 1990;61(8):637–9.
- [408] Fulk GW, Murphy B, Robins MD. Pilocarpine gel for the treatment of demodicosis—a case series. *Optom Vis Sci* 1996;73(12):742–5.
- [409] Kheirkhah A, Casas V, Li W, Raju VK, Tseng SC. Corneal manifestations of ocular demodex infestation. *Am J Ophthalmol* 2007;143(5):743–9.
- [410] Gao YY, Di Pascuale MA, Elizondo A, Tseng SC. Clinical treatment of ocular demodocosis by lid scrub with tea tree oil. *Cornea* 2007;26(2):136–43.
- [411] Holzchuh FG, Hida RY, Moscovici BK, Villa Albers MB, Santo RM, Kara-José N, et al. Clinical treatment of ocular Demodex folliculorum by systemic ivermectin. *Am J Ophthalmol* 2011;151(6):1030–4. e1.
- [412] Filho PA, Hazarbasanov RM, Grisolia AB, Pazos HB, Kaiserman I, Gomes JÁ. The efficacy of oral ivermectin for the treatment of chronic blepharitis in patients tested positive for Demodex spp. *Br J Ophthalmol* 2011;95(6):893–5.
- [413] Koo H, Kim TH, Kim KW, Wee SW, Chun YS, Kim JC. Ocular surface discomfort and Demodex: effect of tea tree oil eyelid scrub in Demodex blepharitis. *J Korean Med Sci* 2012;27(12):1574–9.
- [414] Gao YY, Xu DL, Huang IJ, Wang R, Tseng SC. Treatment of ocular itching associated with ocular demodicosis by 5% tea tree oil ointment. *Cornea* 2012;31(1):14–7.
- [415] Salem DA, El-Shazly A, Nabih N, El-Bayoumy Y, Saleh S. Evaluation of the efficacy of oral ivermectin in comparison with ivermectin-metronidazole combined therapy in the treatment of ocular and skin lesions of Demodex folliculorum. *Int J Infect Dis* 2013;17(5):e343–7.
- [416] Carson CF, Hammer KA, Riley TV. Melaleuca alternifolia (Tea Tree) oil: a review of antimicrobial and other medicinal properties. *Clin Microbiol Rev*

- 2006;19(1):50–62.
- [417] Gao YY, Di Pascuale MA, Li W, Baradaran-Rafii A, Elizondo A, Kuo CL, et al. In vitro and in vivo killing of ocular Demodex by tea tree oil. *Br J Ophthalmol* 2005;89(11):1468–73.
- [418] Tighe S, Gao YY, Tseng SC. Terpinen-4-ol is the Most Active Ingredient of Tea Tree Oil to Kill Demodex Mites. *Transl Vis Sci Technol* 2013;2(7):2.
- [419] Cheng AM, Sheha H, Tseng SC. Recent advances on ocular Demodex infestation. *Curr Opin Ophthalmol* 2015;26(4):295–300.
- [420] Nicholls SG, Oakley CL, Tan A, Vote BJ. Demodex treatment in external ocular disease: the outcomes of a Tasmanian case series. *Int Ophthalmol* 2016;36(5):691–6.
- [421] Forstinger C, Kittler H, Binder M. Treatment of rosacea-like demodicidosis with oral ivermectin and topical permethrin cream. *J Am Acad Dermatol* 1999;41(5 Pt 1):775–7.
- [422] McCann LC, Tomlinson A, Pearce EI, Papa V. Effectiveness of artificial tears in the management of evaporative dry eye. *Cornea* 2012;31(1):1–5.
- [423] Sindt CW, Foulks GN. Efficacy of an artificial tear emulsion in patients with dry eye associated with meibomian gland dysfunction. *Clin Ophthalmol* 2013;7:1713–22.
- [424] Aguilar AJ, Marquez MI, Albera PA, Tredice JL, Berra A. Effects of Systane® Balance on noninvasive tear film break-up time in patients with lipid-deficient dry eye. *Clin Ophthalmol* 2014;8:2365–72.
- [425] Kaercher T, Thelen U, Brief G, Morgan-Warren RJ, Leback R. A prospective, multicenter, noninterventional study of Optive Plus® in the treatment of patients with dry eye: the prolipid study. *Clin Ophthalmol* 2014;8:1147–55.
- [426] Guthrie SE, Jones L, Blackie CA, Korb DR. A Comparative Study Between an Oil-in-Water Emulsion and Nonlipid Eye Drops Used for Rewetting Contact Lenses. *Eye Contact Lens* 2015;41(6):373–7.
- [427] Ousler 3rd G, Devries DK, Karpecki PM, Ciolino JB. An evaluation of Retaine™ ophthalmic emulsion in the management of tear film stability and ocular surface staining in patients diagnosed with dry eye. *Clin Ophthalmol* 2015;9:235–43.
- [428] Gan L, Wang J, Jiang M, Bartlett H, Ouyang D, Eperjesi F, et al. Recent advances in topical ophthalmic drug delivery with lipid-based nanocarriers. *Drug Discov Today* 2013;18(5–6):290–7.
- [429] Sim HS, Petznick A, Barbier S, Tan JH, Acharya UR, Yeo S, et al. A Randomized, Controlled Treatment Trial of Eyelid-Warming Therapies in Meibomian Gland Dysfunction. *Ophthalmol Ther* 2014;3(1–2):37–48.
- [430] Villani Edoardo, Garoli Elena, Canton Veronica, Pichi Francesco, Nucci Paolo, Ratiglia Roberto. Evaluation of a novel eyelid-warming device in meibomian gland dysfunction unresponsive to traditional warm compress treatment: an in vivo confocal study. *Int Ophthalmol* 2015;35(3):319–23.
- [431] Lacroix Z, Léger S, Bitton E. Ex vivo heat retention of different eyelid warming masks. *Cont Lens Anter Eye* 2015;38(3):152–6.
- [432] Bitton E, Lacroix Z, Léger S. In-vivo heat retention comparison of eyelid warming masks. *Cont Lens Anter Eye* 2016;39(4):311–5.
- [433] Murakami DK, Blackie CA, Korb DR. All Warm Compresses Are Not Equally Efficacious. *Optom Vis Sci* 2015;92(9):e327–33.
- [434] Bron AJ, Tiffany JM. The contribution of meibomian disease to dry eye. *Ocul Surf* 2004;2(2):149–65.
- [435] Nichols KK, Ham BM, Nichols JJ, Ziegler C, Green-Church KB. Identification of fatty acids and fatty acid amides in human meibomian gland secretions. *Invest Ophthalmol Vis Sci* 2007;48(1):34–9.
- [436] Olson MC, Korb DR, Greiner JV. Increase in tear film lipid layer thickness following treatment with warm compresses in patients with meibomian gland dysfunction. *Eye Contact Lens* 2003;29(2):96–9.
- [437] Blackie CA, Korb DR, Knop E, Bedi R, Knop N, Holland EJ. Nonobvious obstructive meibomian gland dysfunction. *Cornea* 2010;29(12):1333–45.
- [438] Goto E, Endo K, Suzuki A, Fujikura Y, Tsubota K. Improvement of tear stability following warm compression in patients with meibomian gland dysfunction. *Adv Exp Med Biol* 2002;506(Pt B):1149–52.
- [439] Tiffany JM. The lipid secretion of the meibomian glands. *Adv Lipid Res* 1987;22:1–62.
- [440] Ong BL, Larke JR. Meibomian gland dysfunction: some clinical, biochemical and physical observations. *Ophthalmic Physiol Opt* 1990;10(2):144–8.
- [441] Korb DR, Blackie CA. Meibomian gland diagnostic expressibility: correlation with dry eye symptoms and gland location. *Cornea* 2008;27(10):1142–7.
- [442] Arita R, Morishige N, Shirakawa R, Sato Y, Amano S. Effects of Eyelid Warming Devices on Tear Film Parameters in Normal Subjects and Patients with Meibomian Gland Dysfunction. *Ocul Surf* 2015;13(4):321–30.
- [443] Blackie CA, Solomon JD, Greiner JV, Holmes M, Korb DR. Inner eyelid surface temperature as a function of warm compress methodology. *Optom Vis Sci* 2008;85(8):675–83.
- [444] Chang CM, Chu HT, Wei YH, Chen FP, Wang S, Wu PC, et al. The Core Pattern Analysis on Chinese Herbal Medicine for Sjögren's syndrome: A Nationwide Population-Based Study. *Sci Rep* 2015;5:9541.
- [445] Despa F, Orgill DP, Neuwalder J, Lee RC. The relative thermal stability of tissue macromolecules and cellular structure in burn injury. *Burns* 2005;31(5):568–77.
- [446] Moritz AR, Henriques FC. Studies of Thermal Injury: II. The Relative Importance of Time and Surface Temperature in the Causation of Cutaneous Burns. *Am J Pathol* 1947;23(5):695–720.
- [447] Plaghki L, Decruynaere C, Van Dooren P, Le Bars D. The fine tuning of pain thresholds: a sophisticated double alarm system. *PLoS One* 2010;5:e10269.
- [448] Blackie CA, McMonnies CW, Korb DR. Warm compresses and the risks of elevated corneal temperature with massage. *Cornea* 2013;32(7):e146–9.
- [449] Solomon JD, Case CL, Greiner JV, Blackie CA, Herman JP, Korb DR. Warm compress induced visual degradation and Fischer-Schweitzer polygonal reflex. *Optom Vis Sci* 2007;84(7):580–7.
- [450] McMonnies CW, Korb DR, Blackie CA. The role of heat in rubbing and massage-related corneal deformation. *Cont Lens Anter Eye* 2012;35(4):148–54.
- [451] Man Lam S, Tong L, Duan X, Acharya UR, Tan JH, Petznick A, et al. Wenk MR, Shui G. *J Lipid Res* 2014;55(9):1959–69.
- [452] Pearce EI, Archer CV, McWilliams MA, Tomlinson A, Fuller JR. Effects of novel eye warming goggles on the tear film. *Invest Ophthalmol Vis Sci* 2006;47:5601.
- [453] Pult H, Riede-Pult BH, Purslow C. A comparison of an eyelid-warming device to traditional compress therapy. *Optom Vis Sci* 2012;89(7):E1035–41.
- [454] Doan S, Chiambaretta F, Baudouin C, ESPOIR study group. Evaluation of an eyelid warming device (Blephasteam) for the management of ocular surface diseases in France: the ESPOIR study. *J Fr Ophtalmol* 2014;37(10):763–72.
- [455] Wang MT, Gokul A, Craig JP. Temperature profiles of patient-applied eyelid warming therapies. *Cont Lens Anter Eye* 2015;38(6):430–4.
- [456] Bilkhu PS, Naroo SA, Wolffsohn JS. Randomised masked clinical trial of the MGD Rx EyeBag for the treatment of meibomian gland dysfunction-related evaporative dry eye. *Br J Ophthalmol* 2014;98(12):1707–11.
- [457] Wang MT, Jaitley Z, Lord SM, Craig JP. Comparison of Self-applied Heat Therapy for Meibomian Gland Dysfunction. *Optom Vis Sci* 2015;92(9):e321–6.
- [458] Goto E, Monden Y, Takano Y, Mori A, Shimmura S, Shimazaki J, et al. Treatment of non-inflamed obstructive meibomian gland dysfunction by an infrared warm compression device. *Br J Ophthalmol* 2002;86(12):1403–7.
- [459] Lane SS, DuBiner HB, Epstein RJ, Ernest PH, Greiner JV, Hardten DR, et al. A new system, the LipiFlow, for the treatment of meibomian gland dysfunction. *Cornea* 2012;31(4):396–404.
- [460] Hom MM, Silverman MW. Displacement technique and meibomian gland expression. *J Am Optom Assoc* 1987;58(3):223–6.
- [461] Korb DR, Greiner JV. Increase in tear film lipid layer thickness following treatment of meibomian gland dysfunction. *Adv Exp Med Biol* 1994;350:293–8.
- [462] McCullery JP, Sciallis GF. Meibomian keratoconjunctivitis. *Am J Ophthalmol* 1977;84(6):788–93.
- [463] Korb DR, Henriquez AS. Meibomian gland dysfunction and contact lens intolerance. *J Am Optom Assoc* 1980;51(3):243–51.
- [464] Korb DR, Blackie CA. Meibomian gland therapeutic expression: quantifying the applied pressure and the limitation of resulting pain. *Eye Contact Lens* 2011;37(5):298–301.
- [465] Blackie CA, Carlson AN, Korb DR. Treatment for meibomian gland dysfunction and dry eye symptoms with a single-dose vectored thermal pulsation: a review. *Curr Opin Ophthalmol* 2015;26(4):306–13.
- [466] Finis D, König C, Hayajneh J, Borrelli M, Schrader S, Geerling G. Six-month effects of a thermodynamic treatment for MGD and implications of meibomian gland atrophy. *Cornea* 2014;33(12):1265–70.
- [467] Blackie CA, Coleman CA, Holland EJ. The sustained effect (12 months) of a single-dose vectored thermal pulsation procedure for meibomian gland dysfunction and evaporative dry eye. *Clin Ophthalmol* 2016;10:1385–96.
- [468] Greiner JV. Long-Term (3 Year) Effects of a Single Thermal Pulsation System Treatment on Meibomian Gland Function and Dry Eye Symptoms. *Eye Contact Lens* 2016;42(2):99–107.
- [469] Goldberg DJ. Current trends in intense pulsed light. *J Clin Aesthet Dermatol* 2012;5(6):45–53.
- [470] Craig JP, Chen YH, Turnbull PR. Prospective trial of intense pulsed light for the treatment of meibomian gland dysfunction. *Invest Ophthalmol Vis Sci* 2015;56(3):1965–70.
- [471] Vegunta S, Patel D, Shen JF. Combination Therapy of Intense Pulsed Light Therapy and Meibomian Gland Expression (IPL/MGX) Can Improve Dry Eye Symptoms and Meibomian Gland Function in Patients With Refractory Dry Eye: A Retrospective Analysis. *Cornea* 2016;35(3):318–22.
- [472] Gupta PK, Vora GK, Matossian C, Kim M, Stinnett S. Outcomes of intense pulsed light therapy for treatment of evaporative dry eye disease. *Can J Ophthalmol* 2016;51(4):249–53.
- [473] Maskin SL. Intraductal meibomian gland probing relieves symptoms of obstructive meibomian gland dysfunction. *Cornea* 2010;29(10):1145–52.
- [474] Feron S, Hindi Zaga I, Alvarez Melloni D. Intraductal meibomian gland probing for the treatment of blepharitis. *Arch Soc Esp Oftalmol* 2015;90(2):76–80.
- [475] Nakayama N, Kawashima M, Kaido M, Arita R, Tsubota K. Analysis of Meibum Before and After Intraductal Meibomian Gland Probing in Eyes With Obstructive Meibomian Gland Dysfunction. *Cornea* 2015;34(10):1206–8.
- [476] Wladis EJ. Intraductal meibomian gland probing in the management of ocular rosacea. *Ophthalm Plast Reconstr Surg* 2012 Nov-Dec;28(6):416–8.
- [477] Knop E, Knop N, Millar T, Obata H, Sullivan DA. The international workshop on meibomian gland dysfunction: report of the subcommittee on anatomy, physiology, and pathophysiology of the meibomian gland. *Invest Ophthalmol Vis Sci* 2011;52(4):1938–78.
- [478] Korb DR, Blackie CA. Debridement-scaling: a new procedure that increases Meibomian gland function and reduces dry eye symptoms. *Cornea* 2013;32(12):1554–7.
- [479] Ngo W, Caffery B, Srinivasan S, Jones LW. Effect of Lid Debridement-Scaling in Sjögren Syndrome Dry Eye. *Optom Vis Sci* 2015;92(9):e316–20.

- [480] McMonnies CW. Incomplete blinking: exposure keratopathy, lid wiper epitheliopathy, dry eye, refractive surgery, and dry contact lenses. *Cont Lens Anter Eye* 2007;30(1):37–51.
- [481] Pereira MV, Glória AL. *Semin Ophthalmol* 2010;25(3):72–8.
- [482] Zeev MS, Miller DD, Latkany R. Diagnosis of dry eye disease and emerging technologies. *Clin Ophthalmol* 2014;8:581–90.
- [483] Bron AJ, de Paiva CS, Chauhan SK, Bonini S, Gabison EE, Jain S, et al. TFOS DEWS II Pathophysiology report. *Ocul Surf* 2017;15:438–510.
- [484] Katz J, Kaufman HE. Corneal exposure during sleep (nocturnal lagophthalmos). *Arch Ophthalmol* 1977;95(3):449–53.
- [485] Sohrab M, Abugo U, Grant M, Merbs S. Management of the eye in facial paralysis. *Facial Plast Surg* 2015;31(2):140–4.
- [486] Vásquez LM, Medel R. Lagophthalmos after facial palsy: current therapeutic options. *Ophthalmic Res* 2014;52(4):165–9.
- [487] Latkany RL, Lock B, Speaker M. Nocturnal lagophthalmos: an overview and classification. *Ocul Surf* 2006;4(1):44–53.
- [488] So HM, Lee CC, Leung AK, Lim JM, Chan CS, Yan WW. Comparing the effectiveness of polyethylene covers (Gladwrap) with lanolin (Duratears) eye ointment to prevent corneal abrasions in critically ill patients: a randomized controlled study. *Int J Nurs Stud* 2008;45(11):1565–71.
- [489] Koroloff N, Boots R, Lipman J, Thomas P, Rickard C, Coyer F. A randomised controlled study of the efficacy of hypromellose and Lacri-Lube combination versus polyethylene/Cling wrap to prevent corneal epithelial breakdown in the semiconscious intensive care patient. *Intensive Care Med* 2004;30(6):1122–6.
- [490] Kartush JM, Linstrom CJ, McCann PM, Graham MD. Early gold weight eyelid implantation for facial paralysis. *Otolaryngol Head Neck Surg* 1990;103(6):1016–23.
- [491] Linder T, Linstrom C, Robert Y. Rehabilitation of the eye in patients with facial paralyses: indications and results of gold weight implantation. *Klin Monbl Augenheilkd* 1997;210:293–5.
- [492] Lucena A, Akaishi PM, Rodrigues Mde L, Cruz AA. Upper eyelid entropion and dry eye in cicatricial trachoma without trichiasis. *Arq Bras Oftalmol* 2012 Nov-Dec;75(6):420–2.
- [493] Geerling G, Borrelli M. Adnexal surgery for severe ocular surface disease. *Semin Ophthalmol* 2005 Apr-Jun;20(2):101–12.
- [494] Hintschich C. Correction of entropion and ectropion. *Dev Ophthalmol* 2008;41:85–102.
- [495] Ross AH, Cannon PS, Selva D, Malhotra R. Management of upper eyelid cicatricial entropion. *Clin Exp Ophthalmol* 2011;39(6):526–36.
- [496] Al-Amry MA. Ocular manifestation of Ichthyosis. *Saudi J Ophthalmol* 2016 Jan-Mar;30(1):39–43.
- [497] Damasceno RW, Avgitidou G, Belfort Jr R, Dantas PE, Holbach LM, Heindl LM. Eyelid aging: pathophysiology and clinical management. *Arq Bras Oftalmol* 2015 Sep-Oct;78(5):328–31.
- [498] Monga P, Gupta VP, Dhaliwal U. Clinical evaluation of changes in cornea and tear film after surgery for trachomatous upper lid entropion. *Eye (Lond)* 2008;22(7):912–7.
- [499] Cosar CB, Cohen EJ, Rapuano CJ, Maus M, Penne RP, Flanagan JC, et al. Tarsorrhaphy: clinical experience from a cornea practice. *Cornea* 2001;20(8):787–91.
- [500] Papas EB, Ciolino JB, Jacobs D, Miller WL, Miller WS, Pult H, et al. The TFOS International Workshop on Contact Lens Discomfort: report of the management and therapy subcommittee. *Invest Ophthalmol Vis Sci* 2013;54(11):TFOS183–203.
- [501] Koh S, Maeda N, Soma T, Hori Y, Tsujikawa M, Watanabe H, et al. Development of Methicillin-Resistant *Staphylococcus aureus* Keratitis in a Dry Eye Patient With a Therapeutic Contact Lens. *Eye Contact Lens Sci Clin Pract* 2012;38(3):200–2.
- [502] Henry CR, Flynn Jr HW, Miller D, Forster RK, Alfonso EC. Infectious keratitis progressing to endophthalmitis: a 15-year study of microbiology, associated factors, and clinical outcomes. *Ophthalmology* 2012;119(12):2443–9.
- [503] Stapleton F, Keay L, Edwards K, Naduvilath T, Dart JK, Brian G, et al. The incidence of contact lens-related microbial keratitis in Australia. *Ophthalmology* 2008;115(10):1655–62.
- [504] Dart JK, Radford CF, Minassian D, Verma S, Stapleton F. *Ophthalmology* 2008;115(10):1647–54. 1654e1-3.
- [505] Schein OD, Glynn RJ, Poggio EC, Seddon JM, Kenyon KR. The relative risk of ulcerative keratitis among users of daily-wear and extended-wear soft contact lenses. A case-control study. Microbial Keratitis Study Group. *N Engl J Med* 1989;321(12):773–8.
- [506] Stapleton F, Dart JK, Minassian D. Risk factors with contact lens related suppurative keratitis. *CLAO J* 1993;19(4):204–10.
- [507] Foulks GN, Harvey T, Raj CV. Therapeutic contact lenses: the role of high-Dk lenses. *Ophthalmol Clin North Am* 2003;16(3):455–61.
- [508] Ahad MA, Anandan M, Tah V, Dhingra S, Leyland M. Randomized Controlled Study of Ocular Lubrication Versus Bandage Contact Lens in the Primary Treatment of Recurrent Corneal Erosion Syndrome. *Cornea* 2013;32(10):1311–4.
- [509] Wipperman JL, Dorsch JN. Evaluation and management of corneal abrasions. *Am Fam Physician* 2013;87(2):114–20.
- [510] Siu GD, Young AL, Jhanji V. Alternatives to corneal transplantation for the management of bullous keratopathy. *Curr Opin Ophthalmol* 2014;25(4):347–52.
- [511] Grentzelos MA, Plainis S, Astyrakakis NI, Diakonis VF, Kymionis GD, Kallinikos P, et al. Efficacy of 2 types of silicone hydrogel bandage contact lenses after photorefractive keratectomy. *J Cataract Refract Surg* 2009;35(12):2103–8.
- [512] Chen D, Lian Y, Li J, Ma Y, Shen M, Lu F. Monitor corneal epithelial healing under bandage contact lens using ultrahigh-resolution optical coherence tomography after pterygium surgery. *Eye Contact Lens* 2014;40(3):175–80.
- [513] Daglioglu MC, Coskun M, Ilhan N, Tuzcu EA, Ilhan O, Keskin U, et al. The effects of soft contact lens use on cornea and patient's recovery after autograft pterygium surgery. *Cont Lens Anter Eye* 2014;37(3):175–7.
- [514] Mohammadpour M, Amouzegar A, Hashemi H, Jabbarvand M, Kordbacheh H, Rahimi F, et al. Comparison of Lotraficon B and Balaficon A silicone hydrogel bandage contact lenses in reducing pain and discomfort after photorefractive keratectomy: A contralateral eye study. *Cont Lens Anter Eye* 2015;38(3):211–4.
- [515] Russo PA, Bouchard CS, Galasso JM. Extended-wear silicone hydrogel soft contact lenses in the management of moderate to severe dry eye signs and symptoms secondary to graft-versus-host disease. *Eye Contact Lens* 2007;33(3):144–7.
- [516] Goyal S, Hamrah P. Understanding Neuropathic Corneal Pain—Gaps and Current Therapeutic Approaches. *Semin Ophthalmol* 2016;31:59–70.
- [517] Galor A, Levitt RC, Felix ER, Martin ER, Sarantopoulos CD. Neuropathic ocular pain: an important yet underevaluated feature of dry eye. *Eye (Lond)* 2015;29(3):301–12.
- [518] Smiddy WE, Hamburg TR, Kracher GP, Gottsch JD, Stark WJ. Therapeutic contact lenses. *Ophthalmology* 1990;97(3):291–5.
- [519] Lim L, Tan DT, Chan WK. Therapeutic use of Bausch & Lomb PureVision contact lenses. *CLAO J* 2001;27(4):179–85.
- [520] Jacobs DS, Rosenthal P. Boston scleral lens prosthetic device for treatment of severe dry eye in chronic graft-versus-host disease. *Cornea* 2007;26(10):1195–9.
- [521] Schornack MM, Baratz KH, Patel SV, Maguire LJ. Jupiter scleral lenses in the management of chronic graft versus host disease. *Eye Contact Lens* 2008;34(6):302–5.
- [522] Takahide K, Parker PM, Wu M, Hwang WY, Carpenter PA, Moravec C, et al. Use of fluid-ventilated, gas-permeable scleral lens for management of severe keratoconjunctivitis sicca secondary to chronic graft-versus-host disease. *Biol Blood Marrow Transpl* 2007;13(9):1016–21.
- [523] Tougeron-Brousseau B, Delcampe A, Guedry J, Vera L, Doan S, Hoang-Xuan T, et al. Vision-Related Function After Scleral Lens Fitting in Ocular Complications of Stevens-Johnson Syndrome and Toxic Epidermal Necrolysis. *Am J Ophthalmol* 2009;148(6):852–9.
- [524] Schein OD, Rosenthal P, Ducharme C. A gas-permeable scleral contact lens for visual rehabilitation. *Am J Ophthalmol* 1990;109(3):318–22.
- [525] Kok JH, Visser R. Treatment of ocular surface disorders and dry eyes with high gas-permeable scleral lenses. *Cornea* 1992;11(6):518–22.
- [526] Tan DT, Pullum KW, Buckley RJ. Medical applications of scleral contact lenses: 1. A retrospective analysis of 343 cases. *Cornea* 1995;14(2):121–9.
- [527] Weyns M, Koppen C, Tassignon MJ. Scleral contact lenses as an alternative to tarsorrhaphy for the long-term management of combined exposure and neurotrophic keratopathy. *Cornea* 2013;32(3):359–61.
- [528] Jacobs DS. Update on scleral lenses. *Curr Opin Ophthalmol* 2008;19(4):298–301.
- [529] Schornack MM. Scleral lenses: a literature review. *Eye Contact Lens* 2015;41(1):3–11.
- [530] van der Worp E, Bornman D, Ferreira DL, Faria-Ribeiro M, Garcia-Porta N, González-Mejome JM. Modern scleral contact lenses: A review. *Cont Lens Anter Eye* 2014;37(4):240–50.
- [531] Heur M, Bach D, Theophanous C, Chiu GB. Prosthetic Replacement of the Ocular Surface Ecosystem Scleral Lens Therapy for Patients With Ocular Symptoms of Chronic Stevens-Johnson Syndrome. *Am J Ophthalmol* 2014;158(1):49–54.
- [532] Papakostas TD, Le HG, Chodosh J, Jacobs DS. Prosthetic Replacement of the Ocular Surface Ecosystem as Treatment for Ocular Surface Disease in Patients with a History of Stevens-Johnson Syndrome/Toxic Epidermal Necrolysis. *Ophthalmology* 2015;122(2):248–53.
- [533] Bavinger JC, DeLoss K, Mian SI. Scleral lens use in dry eye syndrome. *Curr Opin Ophthalmol* 2015;26(4):319–24.
- [534] Sonsino J, Mathe DS. Central vault in dry eye patients successfully wearing scleral lens. *Optom Vis Sci* 2013;90. e248–51; discussion 1030.
- [535] Fernandes M, Sharma S. Polymicrobial and microsporidial keratitis in a patient using Boston scleral contact lens for Sjogren's syndrome and ocular cicatricial pemphigoid. *Contact Lens Anter Eye* 2013;36(2):95–7.
- [536] Alipour F, Kheirkhah A, Jabarvand Behrouz M. Use of mini scleral contact lenses in moderate to severe dry eye. *Cont Lens Anter Eye* 2012;35(6):272–6.
- [537] Grey F, Carley F, Biswas S, Tromans C. Scleral contact lens management of bilateral exposure and neurotrophic keratopathy. *Cont Lens Anter Eye* 2012;35(6):288–91.
- [538] Wang Y, Kornberg DL, St Clair RM, Lee M, Muhic I, Ciralsky JB, et al. Corneal nerve structure and function after long-term wear of fluid-filled scleral lens. *Cornea* 2015;34(4):427–32.
- [539] Belmonte C, Nichols JJ, Cox SM, Brock JA, Begley CG, Bereiter DA, et al. TFOS DEWS II Pain and Sensation report. *Ocul Surf* 2017;15:404–37.
- [540] Coronel MF, Labombarda F, González SL. Neuroactive steroids, nociception and neuropathic pain: A flashback to go forward. *Steroids* 2016;110:77–87.

- [541] De Paiva CS, Corrales RM, Villarreal AL, Farley W, Li DQ, Stern ME, et al. Apical corneal barrier disruption in experimental murine dry eye is abrogated by methylprednisolone and doxycycline. *Invest Ophthalmol Vis Sci* 2006;47(7):2847–56.
- [542] De Paiva CS, Corrales RM, Villarreal AL, Farley WJ, Li DQ, Stern ME, et al. Corticosteroid and doxycycline suppress MMP-9 and inflammatory cytokine expression, MAPK activation in the corneal epithelium in experimental dry eye. *Exp Eye Res* 2006;83(3):526–35.
- [543] Lekhanont K, Leyngold IM, Suwan-Apichon O, Rangsin R, Chuck RS. Comparison of topical dry eye medications for the treatment of keratoconjunctivitis sicca in a botulinum toxin B-induced mouse model. *Cornea* 2007;26(1):84–9.
- [544] Okanobo A, Chauhan SK, Dastjerdi MH, Kodati S, Dana R. Efficacy of topical blockade of interleukin-1 in experimental dry eye disease. *Am J Ophthalmol* 2012;154(1):63–71.
- [545] Shafiee A, Bucolo C, Budzynski E, Ward KW, López FJ. In vivo ocular efficacy profile of mapracorat, a novel selective glucocorticoid receptor agonist, in rabbit models of ocular disease. *Invest Ophthalmol Vis Sci* 2011;52(3):1422–30.
- [546] Ji YW, Seo Y, Choi W, Yeo A, Noh H, Kim EK, et al. Dry eye-induced CCR7+CD11b+ cell lymph node homing is induced by COX-2 activities. *Invest Ophthalmol Vis Sci* 2014;55(10):6829–38.
- [547] Marsh P, Pflugfelder SC. Topical nonpreserved methylprednisolone therapy for keratoconjunctivitis sicca in Sjögren syndrome. *Ophthalmology* 1999;106(4):811–6.
- [548] Sainz De La Maza Serra M, Simon Castellvi C, Kabbani O. Nonpreserved topical steroids and lacrimal punctal occlusion for severe keratoconjunctivitis sicca. *Arch Soc Esp Ophthalmol* 2000;75:751–6.
- [549] Avunduk AM, Avunduk MC, Varnell ED, Kaufman HE. The comparison of efficacies of topical corticosteroids and nonsteroidal anti-inflammatory drops on dry eye patients: a clinical and immunocytochemical study. *Am J Ophthalmol* 2003;136(4):593–602.
- [550] Pflugfelder SC, Maskin SL, Anderson B, Chodosh J, Holland EJ, De Paiva CS, et al. A randomized, double-masked, placebo-controlled, multicenter comparison of loteprednol etabonate ophthalmic suspension, 0.5%, and placebo for treatment of keratoconjunctivitis sicca in patients with delayed tear clearance. *Am J Ophthalmol* 2004;138:444–57.
- [551] Lee HK, Ryu IH, Seo KY, Hong S, Kim HC, Kim EK. Topical 0.1% prednisolone lowers nerve growth factor expression in keratoconjunctivitis sicca patients. *Ophthalmology* 2006;113:198–205.
- [552] Yang CQ, Sun W, Gu YS. A clinical study of the efficacy of topical corticosteroids on dry eye. *J Zhejiang Univ Sci B* 2006;7(8):675–8.
- [553] Jonisch J, Steiner A, Udell IJ. Preservative-free low-dose dexamethasone for the treatment of chronic ocular surface disease refractory to standard therapy. *Cornea* 2010;29(7):723–6.
- [554] Sheppard JD, Donnenfeld ED, Holland EJ, Slonim CB, Solomon R, Solomon KD, et al. Effect of loteprednol etabonate 0.5% on initiation of dry eye treatment with topical cyclosporine 0.05%. *Eye Contact Lens* 2014;40(5):289–96.
- [555] Kheirkhah A, Dohlman TH, Amparo F, Arnoldner MA, Jamali A, Hamrah P, et al. Effects of corneal nerve density on the response to treatment in dry eye disease. *Ophthalmology* 2015;122(4):662–8.
- [556] Lin T, Gong L. Topical fluorometholone treatment for ocular dryness in patients with Sjögren syndrome: a randomized clinical trial in China. *Med Baltim* 2015;94:e551.
- [557] Pinto-Fraga José, López-Miguel Alberto, González-García María J, Fernández Itziar, López-de-la-Rosa Alberto, Enríquez-de-Salamanca Amalia, et al. Topical Fluorometholone Protects the Ocular Surface of Dry Eye Patients from Desiccating Stress. *Ophthalmology* 2016;123(1):141–53.
- [558] Villani E, Garoli E, Termine V, Pichi F, Ratiglia R, Nucci P. Corneal Confocal Microscopy in Dry Eye Treated with Corticosteroids. *Optom Vis Sci* 2015;92(9):e290–5.
- [559] Hong S, Kim T, Chung SH, Kim EK, Seo KY. Recurrence after topical nonpreserved methylprednisolone therapy for keratoconjunctivitis sicca in Sjögren's syndrome. *J Ocul Pharmacol Ther* 2007;23(1):78–82.
- [560] McGhee CN, Dean S, Danesh-Meyer H. Locally administered ocular corticosteroids: benefits and risks. *Drug Saf* 2002;25(1):33–55.
- [561] LeHoang P. The gold standard of noninfectious uveitis: corticosteroids. *Dev Ophthalmol* 2012;51:7–28.
- [562] Mataftsi A, Narang A, Moore W, Nischal KK. Do reducing regimens of fluorometholone for paediatric ocular surface disease cause glaucoma? *Br J Ophthalmol* 2011;95(11):1531–3.
- [563] Bilgihan K, Gürel G, Akata F, Hasanreisoglu B. Fluorometholone-induced cataract after photorefractive keratectomy. *Ophthalmologica* 1997;211(6):394–6.
- [564] Sheppard JD, Comstock TL, Cavet ME. Impact of the Topical Ophthalmic Corticosteroid Loteprednol Etabonate on Intraocular Pressure. *Adv Ther* 2016;33(4):532–52.
- [565] Byun YJ, Kim TI, Kwon SM, Seo KY, Kim SW, Kim EK, et al. Efficacy of combined 0.05% cyclosporine and 1% methylprednisolone treatment for chronic dry eye. *Cornea* 2012;31(5):509–13.
- [566] Chen W, Li Z, Hu J, Zhang Z, Chen L, Chen Y, et al. Corneal alternations induced by topical application of benzalkonium chloride in rabbit. *PLoS One* 2011;6:e26103.
- [567] Kim YH, Jung JC, Jung SY, Yu S, Lee KW, Park YJ. Comparison of the Efficacy of Fluorometholone With and Without Benzalkonium Chloride in Ocular Surface Disease. *Cornea* 2016;35(2):234–42.
- [568] Barbarino JM, Staats CE, Venkataraman R, Klein TE, Altman RB. PharmGKB summary: cyclosporine and tacrolimus pathways. *Pharmacogenet Genomics* 2013;23(10):563–85.
- [569] Donnenfeld E, Pflugfelder SC. Topical ophthalmic cyclosporine: pharmacology and clinical uses. *Surv Ophthalmol* 2009 May-Jun;54(3):321–38.
- [570] Matsuda S, Koyasu S. Mechanisms of action of cyclosporine. *Immunopharmacology* 2000;47(2–3):119–25.
- [571] Haddad EM, McAlister VC, Renouf E, Malthaner R, Kjaer MS, Gluud LL. Cyclosporin versus tacrolimus for liver transplanted patients. *Cochrane Database Syst Rev* 2006;(4):CD005161.
- [572] Gorantla VS, Barker JH, Jones Jr JW, Prabhune K, Maldonado C, Granger DK. Immunosuppressive agents in transplantation: mechanisms of action and current anti-rejection strategies. *Microsurgery* 2000;20(8):420–9.
- [573] Kumar NS, Khosla R, Makharia GK. Cyclosporine in steroid refractory acute severe colitis. *Trop Gastroenterol* 2014;35(Suppl 1):S21–8.
- [574] Gremese E, Ferracoli GF. Benefit/risk of cyclosporine in rheumatoid arthritis. *Clin Exp Rheumatol* 2004 Sep-Oct;22(5 Suppl 35):S101–7.
- [575] Utine CA, Stern M, Akpek EK. Clinical review: topical ophthalmic use of cyclosporin A. *Ocul Immunol Inflamm* 2010;18(5):352–61.
- [576] Keklikci U, Dursun B, Cingu AK. Topical cyclosporine 0.05% eyedrops in the treatment of vernal keratoconjunctivitis - randomized placebo-controlled trial. *Adv Clin Exp Med* 2014;23:455–61.
- [577] Gonzalez-Lopez JJ, Lopez-Alcalde J, Morcillo Laiz R, Fernandez Buenaga R, Rebolledo Fernandez G. Topical cyclosporine for atopic keratoconjunctivitis. *Cochrane Database Syst Rev* 2012;9:CD009078.
- [578] Kim BY, Riaz KM, Bakhtiari P, Chan CC, Welder JD, Holland EJ, et al. Medically reversible limbal stem cell disease: clinical features and management strategies. *Ophthalmology* 2014;121(10):2053–8.
- [579] Kunert KS, Tisdale AS, Stern ME, Smith JA, Gipson IK. Analysis of topical cyclosporine treatment of patients with dry eye syndrome: effect on conjunctival lymphocytes. *Arch Ophthalmol* 2000;118(11):1489–96.
- [580] Brignole F, Pisella PJ, De Saint Jean M, Goldschild M, Goguel A, Baudouin C. Flow cytometric analysis of inflammatory markers in KCS: 6-month treatment with topical cyclosporin A. *Invest Ophthalmol Vis Sci* 2001;42(1):90–5.
- [581] Gao J, Sana R, Calder V, Calonge M, Lee W, Wheeler LA, et al. Mitochondrial permeability transition pore in inflammatory apoptosis of human conjunctival epithelial cells and T cells: effect of cyclosporin A. *Invest Ophthalmol Vis Sci* 2013;54:4717–33.
- [582] Tsubota K, Fujita H, Tadano K, Takeuchi T, Murakami T, Saito I, et al. Improvement of lacrimal function by topical application of CyA in murine models of Sjögren's syndrome. *Invest Ophthalmol Vis Sci* 2001;42(1):101–10.
- [583] Brignole F, Pisella PJ, Goldschild M, De Saint Jean M, Goguel A, Baudouin C. Flow cytometric analysis of inflammatory markers in conjunctival epithelial cells of patients with dry eyes. *Invest Ophthalmol Vis Sci* 2000;41(6):1356–63.
- [584] Strong B, Farley W, Stern ME, Pflugfelder SC. Topical cyclosporine inhibits conjunctival epithelial apoptosis in experimental murine keratoconjunctivitis sicca. *Cornea* 2005;24(1):80–5.
- [585] Gao J, Gelber-Schwab TA, Addeo JV, Stern ME. Apoptosis in the lacrimal gland and conjunctiva of dry eye dogs. *Adv Exp Med Biol* 1998;438:453–60.
- [586] Sall K, Stevenson OD, Mundorf TK, Reis BL. Two multicenter, randomized studies of the efficacy and safety of cyclosporine ophthalmic emulsion in moderate to severe dry eye disease. *CsA Phase 3 Study Group. Ophthalmology* 2000;107(4):631–9.
- [587] Pflugfelder SC, De Paiva CS, Villarreal AL, Stern ME. Effects of sequential artificial tear and cyclosporine emulsion therapy on conjunctival goblet cell density and transforming growth factor-beta2 production. *Cornea* 2008;27(1):64–9.
- [588] Baiza-Durán L, Medrano-Palafox J, Hernández-Quintela E, Lozano-Alcazar J, Alaniz-de la O JF. A comparative clinical trial of the efficacy of two different aqueous solutions of cyclosporine for the treatment of moderate-to-severe dry eye syndrome. *Br J Ophthalmol* 2010;94(10):1312–5.
- [589] Chen M, Gong L, Sun X, Xie H, Zhang Y, Zou L, et al. A comparison of cyclosporine 0.05% ophthalmic emulsion versus vehicle in Chinese patients with moderate to severe dry eye disease: an eight-week, multicenter, randomized, double-blind, parallel-group trial. *J Ocul Pharmacol Ther* 2010;26:361–6.
- [590] Su MY, Perry HD, Barsam A, Perry AR, Donnenfeld ED, Wittmann JR, et al. The effect of decreasing the dosage of cyclosporine A 0.05% on dry eye disease after 1 year of twice-daily therapy. *Cornea* 2011;30(10):1098–104.
- [591] Deveci H, Kobak S. The efficacy of topical 0.05 % cyclosporine A in patients with dry eye disease associated with Sjögren's syndrome. *Int Ophthalmol* 2014;34:1043–8.
- [592] Salib GM, McDonald MB, Smolek M. Safety and efficacy of cyclosporine 0.05% drops versus unpreserved artificial tears in dry-eye patients having laser in situ keratomileusis. *J Cataract Refract Surg* 2006;32:772–8.
- [593] Perry HD, Solomon R, Donnenfeld ED, Perry AR, Wittmann JR, Greenman HE, et al. Evaluation of topical cyclosporine for the treatment of dry eye disease. *Arch Ophthalmol* 2008;126(8):1046–50.
- [594] Alves M, Fonseca EC, Alves MF, Malki LT, Arruda GV, Reinach PS, et al. Dry eye disease treatment: a systematic review of published trials and a critical appraisal of therapeutic strategies. *Ocul Surf* 2013;11(3):181–92.
- [595] Sacchetti M, Mantelli F, Lambiase A, Mastropasqua A, Merlo D, Bonini S.

- Systematic review of randomised clinical trials on topical ciclosporin A for the treatment of dry eye disease. *Br J Ophthalmol* 2014;98(8):1016–22.
- [596] Zhou XQ, Wei RL. Topical cyclosporine A in the treatment of dry eye: a systematic review and meta-analysis. *Cornea* 2014;33(7):760–7.
- [597] Wan KH, Chen LJ, Young AL. Efficacy and Safety of Topical 0.05% Cyclosporine Eye Drops in the Treatment of Dry Eye Syndrome: A Systematic Review and Meta-analysis. *Ocul Surf* 2015;13(3):213–25.
- [598] Brown MM, Brown GC, Brown HC, Peet J, Roth Z. Value-based medicine, comparative effectiveness, and cost-effectiveness analysis of topical cyclosporine for the treatment of dry eye syndrome. *Arch Ophthalmol* 2009;127(2):146–52.
- [599] Perry HD, Doshi-Carnevale S, Donnenfeld ED, Solomon R, Biser SA, Bloom AH. Efficacy of commercially available topical cyclosporine A 0.05% in the treatment of meibomian gland dysfunction. *Cornea* 2006;25(2):171–5.
- [600] Rubin M, Rao SN. Efficacy of topical cyclosporin 0.05% in the treatment of posterior blepharitis. *J Ocul Pharmacol Ther* 2006;22(1):47–53.
- [601] Schechter BA, Katz RS, Friedman LS. Efficacy of topical cyclosporine for the treatment of ocular rosacea. *Adv Ther* 2009;26(6):651–9.
- [602] Prabhawat P, Tesavibul N, Karnchanachanee C, Kasemson S. Efficacy of cyclosporine 0.05% eye drops in Stevens Johnson syndrome with chronic dry eye. *J Ocul Pharmacol Ther* 2013;29(3):372–7.
- [603] Wilson SE, Perry HD. Long-term resolution of chronic dry eye symptoms and signs after topical cyclosporine treatment. *Ophthalmology* 2007;114(1):76–9.
- [604] Leonardi A, Van Setten G, Amrane M, Ismail D, Garrigue JS, Figueiredo FC, et al. Efficacy and safety of 0.1% cyclosporine A cationic emulsion in the treatment of severe dry eye disease: a multicenter randomized trial. *Eur J Ophthalmol* 2016;26(4):287–96.
- [605] Takeuchi H, Okuyama K, Konno O, Jojima Y, Akashi I, Nakamura Y, et al. Optimal dose and target trough level in cyclosporine and tacrolimus conversion in renal transplantation as evaluated by lymphocyte drug sensitivity and pharmacokinetic parameters. *Transplant Proc* 2005;37(4):1745–7.
- [606] Sanz-Marco E, Udaondo P, García-Delpech S, Vazquez A, Diaz-Llopis M. Treatment of refractory dry eye associated with graft versus host disease with 0.03% tacrolimus eyedrops. *J Ocul Pharmacol Ther* 2013;29(8):776–83.
- [607] Moscovici BK, Holzchuh R, Sakasagawa-Naves FE, Hoshino-Ruiz DR, Albers MB, Santo RM, et al. Treatment of Sjögren's syndrome dry eye using 0.03% tacrolimus eye drop: Prospective double-blind randomized study. *Cont Lens Anter Eye* 2015;38(5):373–8.
- [608] Liu X, Wang S, Kao AA, Long Q. The effect of topical pranopfen 0.1% on the clinical evaluation and conjunctival HLA-DR expression in dry eyes. *Cornea* 2012;31(11):1235–9.
- [609] Rolando M, Barabino S, Alongi S, Calabria G. Topical non-preserved diclofenac therapy for keratoconjunctivitis sicca. *Adv Exp Med Biol* 2002;506(Pt B):1237–40.
- [610] Aragona P, Stilo A, Ferreri F, Mobicri M. Effects of the topical treatment with NSAIDs on corneal sensitivity and ocular surface of Sjögren's syndrome patients. *Eye (Lond)* 2005;19(5):535–9.
- [611] Schechter BA. Ketorolac during the induction phase of cyclosporin-A therapy. *J Ocul Pharmacol Ther* 2006;22(2):150–4.
- [612] Sawazaki R, Ishihara T, Usui S, Hayashi E, Tahara K, Hoshino T, et al. Diclofenac protects cultured human corneal epithelial cells against hyperosmolarity and ameliorates corneal surface damage in a rat model of dry eye. *Invest Ophthalmol Vis Sci* 2014;55:2547–56.
- [613] Avisar R, Robinson A, Appel I, Yassar Y, Weinberger D. Diclofenac sodium, 0.1% (Voltaren Ophtha), versus sodium chloride, 5%, in the treatment of filamentary keratitis. *Cornea* 2000;19(2):145–7.
- [614] Isawi H, Dhaliwal DK. Corneal melting and perforation in Stevens Johnson syndrome following topical bromfenac use. *J Cataract Refract Surg* 2007;33(9):1644–6.
- [615] Singer DD, Kennedy J, Wittpenn JR. Topical NSAIDs effect on corneal sensitivity. *Cornea* 2015;34(5):541–3.
- [616] Aragona P, Di Pietro R. Is it safe to use topical NSAIDs for corneal sensitivity in Sjögren's syndrome patients? *Expert Opin Drug Saf* 2007;6(1):33–43.
- [617] Swann DA, Sotman S, Dixon M, Brooks C. The isolation and partial characterization of the major glycoprotein (LGP-I) from the articular lubricating fraction from bovine synovial fluid. *Biochem J* 1977;161(3):473–85.
- [618] Schmidt TA, Sullivan DA, Knop E, Richards SM, Knop N, Liu S, et al. Transcription, translation, and function of lubricin, a boundary lubricant, at the ocular surface. *JAMA Ophthalmol* 2013;131(6):766–76.
- [619] Schmidt TA, Gastelum NS, Nguyen QT, Schumacher BL, Sah RL. Boundary lubrication of articular cartilage: role of synovial fluid constituents. *Arthritis Rheum* 2007;56(3):882–91.
- [620] Das S, Banquy X, Zappone B, Greene GW, Jay GD, Israelachvili JN. Synergistic interactions between grafted hyaluronic acid and lubricin provide enhanced wear protection and lubrication. *Biomacromolecules* 2013;14(5):1669–77.
- [621] Bonnevie ED, Galesso D, Secchieri C, Cohen I, Bonassar LJ. Elastoviscous Transitions of Articular Cartilage Reveal a Mechanism of Synergy between Lubricin and Hyaluronic Acid. *PLoS One* 2015;10:e0143415.
- [622] Iqbal SM, Leonard C, Regmi SC, De Rantere D, Tailor P, Ren G, et al. Lubricin/Proteoglycan 4 binds to and regulates the activity of Toll-Like Receptors In Vitro. *Sci Rep* 2016;6:18910.
- [623] Alquerain A, Garguilo S, D'Souza G, Zhang LX, Schmidt TA, Jay GD, et al. The interaction of lubricin/proteoglycan 4 (PRG4) with toll-like receptors 2 and 4: an anti-inflammatory role of PRG4 in synovial fluid. *Arthritis Res Ther* 2015;17:353.
- [624] Al-Sharif A, Jamal M, Zhang LX, Larson K, Schmidt TA, Jay GD, et al. Lubricin/Proteoglycan 4 Binding to CD44 Receptor: A Mechanism of the Suppression of Proinflammatory Cytokine-Induced Synoviocyte Proliferation by Lubricin 2015;67(6):1503–13.
- [625] Samsom ML, Morrison S, Masala N, Sullivan BD, Sullivan DA, Sheardown H, et al. Characterization of full-length recombinant human Proteoglycan 4 as an ocular surface boundary lubricant. *Exp Eye Res* 2014;127:14–9.
- [626] Lambiase A, Sullivan BD, Schmidt TA, Sullivan DA, Jay GD, Truitt ER, et al. A Two-Week, Randomized, Double-masked Study to Evaluate Safety and Efficacy of Lubricin (150 mg/mL) Eye Drops Versus Sodium Hyaluronate (HA) 0.18% Eye Drops (Vismed(R)) in Patients with Moderate Dry Eye Disease. *Ocul Surf* 2017;15:77–87.
- [627] Lee HK, Lee KS, Kim HC, Lee SH, Kim EK. Nerve growth factor concentration and implications in photorefractive keratectomy vs laser in situ keratomileusis. *Am J Ophthalmol* 2005;139(6):965–71.
- [628] Yoon JS, Choi SH, Lee JH, Lee SJ, Lee SY. Ocular surface inflammation, and nerve growth factor level in tears in active thyroid-associated ophthalmopathy. *Graefes Arch Clin Exp Ophthalmol* 2010;248(2):271–6.
- [629] Lambiase A, Micera A, Sacchetti M, Cortes M, Mantelli F, Bonini S. Alterations of tear neuromediators in dry eye disease. *Arch Ophthalmol* 2011;129(8):981–6.
- [630] Patapoutian A, Reichardt LF. Trk receptors: mediators of neurotrophin action. *Curr Opin Neurobiol* 2001;11(3):272–80.
- [631] de Castro F, Silos-Santiago I, López de Armentia M, Barbacid M, Belmonte C. Corneal innervation and sensitivity to noxious stimuli in trkA knockout mice. *Eur J Neurosci* 1998;10(1):146–52.
- [632] Qi H, Li DQ, Shine HD, Chen Z, Yoon KC, Jones DB, et al. Nerve growth factor and its receptor TrkA serve as potential markers for human corneal epithelial progenitor cells. *Exp Eye Res* 2008;86(1):34–40.
- [633] Coassin M, Lambiase A, Costa N, De Gregorio A, Sgrulletta R, Sacchetti M, et al. Efficacy of topical nerve growth factor treatment in dogs affected by dry eye. *Graefes Arch Clin Exp Ophthalmol* 2005;243(2):151–5.
- [634] Bonini S, Rama P, Olzi D, Lambiase A. Neurotrophic keratitis. *Eye (Lond)* 2003;17(8):989–95.
- [635] Ma K, Yan N, Huang Y, Cao G, Deng J, Deng Y. Effects of nerve growth factor on nerve regeneration after corneal nerve damage. *Int J Clin Exp Med* 2014;7(11):4584–9.
- [636] Jain P, Li R, Lama T, Saragovi HU, Cumberlidge G, Meerovitch K. An NGF mimetic, MIM-D3, stimulates conjunctival cell glycoconjugate secretion and demonstrates therapeutic efficacy in a rat model of dry eye. *Exp Eye Res* 2011;93(4):503–12.
- [637] Meerovitch K, Torkildsen G, Lonsdale J, Goldfarb H, Lama T, Cumberlidge G, et al. Safety and efficacy of MIM-D3 ophthalmic solutions in a randomized, placebo-controlled Phase 2 clinical trial in patients with dry eye. *Clin Ophthalmol* 2013;7:1275–85.
- [638] Lee RH, Pulvin AA, Seo MJ, Kota DJ, Ylostalo J, Larson BL, et al. Intravenous hMSCs improve myocardial infarction in mice because cells embolized in lung are activated to secrete the anti-inflammatory protein TSG-6. *Cell Stem Cell* 2009;5(1):54–63.
- [639] Roddy GW, Oh JY, Lee RH, Bartosh TJ, Ylostalo J, Coble K, et al. Action at a distance: systemically administered adult stem/progenitor cells (MSCs) reduce inflammatory damage to the cornea without engraftment and primarily by secretion of TNF-alpha stimulated gene/protein 6. *Stem Cells* 2011;29:1572–9.
- [640] Choi H, Lee RH, Bazhanov N, Oh JY, Prockop DJ. Anti-inflammatory protein TSG-6 secreted by activated MSCs attenuates zymosan-induced mouse peritonitis by decreasing TLR2/NF-κB signaling in resident macrophages. *Blood* 2011;118(2):330–8.
- [641] Kim JA, Ko JH, Ko AY, Lee HJ, Kim MK, Wee WR, et al. TSG-6 protects corneal endothelium from transcorneal cryoinjury in rabbits. *Invest Ophthalmol Vis Sci* 2014;55(8):4905–12.
- [642] Kim YJ, Ryu JS, Park SY, Lee HJ, Ko JH, Kim MK, et al. Comparison of Topical Application of TSG-6, Cyclosporine, and Prednisolone for Treating Dry Eye. *Cornea* 2016;35(4):536–42.
- [643] Oh JY, Roddy GW, Choi H, Lee RH, Ylostalo JH, Rosa Jr RH, et al. Anti-inflammatory protein TSG-6 reduces inflammatory damage to the cornea following chemical and mechanical injury. *Proc Natl Acad Sci U S A* 2010;107(39):16875–80.
- [644] Lee MJ, Kim DH, Ryu JS, Ko AY, Ko JH, Kim MK, et al. Topical TSG-6 Administration Protects the Ocular Surface in Two Mouse Models of Inflammation-Related Dry Eye. *Invest Ophthalmol Vis Sci* 2015;56:5175–81.
- [645] Furst DE. Anakinra: review of recombinant human interleukin-1 receptor antagonist in the treatment of rheumatoid arthritis. *Clin Ther* 2004;26(12):1960–75.
- [646] Arend WP. Interleukin-1 receptor antagonist. *Adv Immunol* 1993;54:167–227.
- [647] Yamada J, Dana MR, Sotozono C, Kinoshita S. Local suppression of IL-1 by receptor antagonist in the rat model of corneal alkali injury. *Exp Eye Res* 2003;76(2):161–7.
- [648] Keane-Myers AM, Miyazaki D, Liu G, Dekaris I, Ono S, Dana MR. Prevention of allergic eye disease by treatment with IL-1 receptor antagonist. *Invest Ophthalmol Vis Sci* 1999;40(12):3041–6.
- [649] Biswas PS, Banerjee K, Zheng M, Rouse BT. Counteracting corneal immunoinflammatory lesion with interleukin-1 receptor antagonist protein. *J*

- Leukoc Biol 2004;76(4):868–75.
- [650] Stapleton WM, Chaurasia SS, Medeiros FW, Mohan RR, Sinha S, Wilson SE. Topical interleukin-1 receptor antagonist inhibits inflammatory cell infiltration into the cornea. *Exp Eye Res* 2008;86(5):753–7.
- [651] Vijmasi T, Chen FY, Chen YT, Gallup M, McNamara N. Topical administration of interleukin-1 receptor antagonist as a therapy for aqueous-deficient dry eye in autoimmune disease. *Mol Vis* 2013;19:1957–65.
- [652] Amparo F, Dastjerdi MH, Okanobo A, Ferrari G, Smaga L, Hamrah P, et al. Topical interleukin 1 receptor antagonist for treatment of dry eye disease: a randomized clinical trial. *JAMA Ophthalmol* 2013;131(6):715–23.
- [653] Aggarwal BB. Signalling pathways of the TNF superfamily: a double-edged sword. *Nat Rev Immunol* 2003;3(9):745–56.
- [654] Cope AP, Londei M, Chu NR, Cohen SB, Elliott MJ, Brennan FM, et al. Chronic exposure to tumor necrosis factor (TNF) in vitro impairs the activation of T cells through the T cell receptor/CD3 complex; reversal in vivo by anti-TNF antibodies in patients with rheumatoid arthritis. *J Clin Invest* 1994;94(2):749–60.
- [655] Pflugfelder SC, Jones D, Ji Z, Afonso A, Monroy D. Altered cytokine balance in the tear fluid and conjunctiva of patients with Sjögren's syndrome keratoconjunctivitis sicca. *Curr Eye Res* 1999;19(3):201–11.
- [656] Yoon KC, Jeong IY, Park YG, Yang SY. Interleukin-6 and tumor necrosis factor-alpha levels in tears of patients with dry eye syndrome. *Cornea* 2007;26(4):431–7.
- [657] Lam H, Bleiden L, de Paiva CS, Farley W, Stern ME, Pflugfelder SC. Tear cytokine profiles in dysfunctional tear syndrome. *Am J Ophthalmol* 2009;147(2):198–205. e1.
- [658] Mariette X, Ravaud P, Steinfeld S, Baron G, Goetz J, Hachulla E, et al. Inefficacy of infliximab in primary Sjögren's syndrome: results of the randomized, controlled Trial of Remicade in Primary Sjögren's Syndrome (TRIPSS). *Arthritis Rheum* 2004;50(4):1270–6.
- [659] Sankar V, Brennan MT, Kok MR, Leakan RA, Smith JA, Manny J, et al. Etanercept in Sjögren's syndrome: a twelve-week randomized, double-blind, placebo-controlled pilot clinical trial. *Arthritis Rheum* 2004;50(7):2240–5.
- [660] Zandbelt MM, de Wilde P, van Damme P, Hoyng CB, van de Putte L, van den Hoogen F. Etanercept in the treatment of patients with primary Sjögren's syndrome: a pilot study. *J Rheumatol* 2004;31(1):96–101.
- [661] Moutsopoulos NM, Katsifis GE, Angelov N, Leakan RA, Sankar V, Pillemer S, et al. Lack of efficacy of etanercept in Sjögren syndrome correlates with failed suppression of tumour necrosis factor alpha and systemic immune activation. *Ann Rheum Dis* 2008;67(10):1437–43.
- [662] Li Z, Choi W, Oh HJ, Yoon KC. Effectiveness of topical infliximab in a mouse model of experimental dry eye. *Cornea* 2012;31(Suppl 1):S25–31.
- [663] Ji YW, Byun YJ, Choi W, Jeong E, Kim JS, Noh H, et al. Neutralization of ocular surface TNF- α reduces ocular surface and lacrimal gland inflammation induced by in vivo dry eye. *Invest Ophthalmol Vis Sci* 2013;54(12):7557–66.
- [664] Zheng X, de Paiva CS, Li DQ, Farley WJ, Pflugfelder SC. Desiccating stress promotion of Th17 differentiation by ocular surface tissues through a dendritic cell-mediated pathway. *Invest Ophthalmol Vis Sci* 2010;51(6):3083–91.
- [665] Chauhan SK, Dana R. Role of Th17 cells in the immunopathogenesis of dry eye disease. *Mucosal Immunol* 2009;2(4):375–6.
- [666] De Paiva CS, Chotikavanich S, Pangelinan SB, Pitcher 3rd JD, Fang B, Zheng X, et al. IL-17 disrupts corneal barrier following desiccating stress. *Mucosal Immunol* 2009;2(3):243–53.
- [667] Chauhan SK, Jin Y, Goyal S, Lee HS, Fuchsluger TA, Lee HK, et al. A novel pro-lymphangiogenic function for Th17/IL-17. *Blood* 2011;118(17):4630–4.
- [668] Peral A, Domínguez-Godínez CO, Carracedo G, Pintor J. Therapeutic targets in dry eye syndrome. *Drug News Perspect* 2008;21(3):166–76.
- [669] Kam WR, Sullivan DA. Neurotransmitter influence on human meibomian gland epithelial cells. *Invest Ophthalmol Vis Sci* 2011;52(12):8543–8.
- [670] Lambiase A, Sacchetti M, Bonini S. Nerve growth factor therapy for corneal disease. *Curr Opin Ophthalmol* 2012;23(4):296–302.
- [671] Millard M, Odde S, Neamati N. Integrin targeted therapeutics. *Theranostics* 2011;1:154–88.
- [672] Marlin SD, Springer TA. Purified intercellular adhesion molecule-1 (ICAM-1) is a ligand for lymphocyte function-associated antigen 1 (LFA-1). *Cell* 1987;51(5):813–9.
- [673] Grakoui A, Bromley SK, Sumen C, Davis MM, Shaw AS, Allen PM, et al. The immunological synapse: a molecular machine controlling T cell activation. *Science* 1999;285(5425):221–7.
- [674] Zhong M, Gadek TR, Bui M, Shen W, Burnier J, Barr KJ, et al. Discovery and Development of Potent LFA-1/ICAM-1 Antagonist SAR 1118 as an Ophthalmic Solution for Treating Dry Eye. *ACS Med Chem Lett* 2012;3(3):203–6.
- [675] Sun Y, Zhang R, Gadek TR, O'Neill CA, Pearlman E. Corneal inflammation is inhibited by the LFA-1 antagonist, lifitegrast (SAR 1118). *J Ocul Pharmacol Ther* 2013;29(4):395–402.
- [676] Perez VL, Pflugfelder SC, Zhang S, Shojaei A, Haque R. Lifitegrast, a Novel Integrin Antagonist for Treatment of Dry Eye Disease. *Ocul Surf* 2016;14(2):207–15.
- [677] Semba CP, Torkildsen GL, Lonsdale JD, McLaurin EB, Geffin JA, Mundorf TK, et al. A phase 2 randomized, double-masked, placebo-controlled study of a novel integrin antagonist (SAR 1118) for the treatment of dry eye. *Am J Ophthalmol* 2012;153(6):1050–60. e1.
- [678] Sheppard JD, Torkildsen GL, Lonsdale JD, D'Ambrosio Jr FA, McLaurin EB, Eiferman RA, et al. Lifitegrast ophthalmic solution 5.0% for treatment of dry eye disease: results of the OPUS-1 phase 3 study. *Ophthalmology* 2014;121(2):475–83.
- [679] Tauber J, Karpecki P, Laskany R, Luchs J, Martel J, Sall K, et al. Lifitegrast Ophthalmic Solution 5.0% versus Placebo for Treatment of Dry Eye Disease: Results of the Randomized Phase III OPUS-2 Study. *Ophthalmology* 2015;122(12):2423–31.
- [680] Donnenfeld ED, Karpecki PM, Majumdar PA, Nichols KK, Raychaudhuri A, Roy M, et al. Safety of Lifitegrast Ophthalmic Solution 5.0% in Patients With Dry Eye Disease: A 1-Year, Multicenter, Randomized, Placebo-Controlled Study. *Cornea* 2016;35:741–8.
- [681] Shine WE, McCulley JP, Pandya AG. Minocycline effect on meibomian gland lipids in meibomianitis patients. *Exp Eye Res* 2003;76(4):417–20.
- [682] Ta CN, Shine WE, McCulley JP, Pandya A, Trattler W, Norbury JW. Effects of minocycline on the ocular flora of patients with acne rosacea or seborrheic blepharitis. *Cornea* 2003;22(6):545–8.
- [683] Dougherty JM, McCulley JP, Silvany RE, Meyer DR. The role of tetracycline in chronic blepharitis. Inhibition of lipase production in staphylococci. *Invest Ophthalmol Vis Sci* 1991;32(11):2970–5.
- [684] Solomon A, Rosenblatt M, Li DQ, Liu Z, Monroy D, Ji Z, et al. Doxycycline inhibition of interleukin-1 in the corneal epithelium. *Invest Ophthalmol Vis Sci* 2000;41(9):2544–57.
- [685] Li Y, Kuang K, Yerxa B, Wen Q, Rosskothorn H, Fischberg J. Rabbit conjunctival epithelium transports fluid, and P2Y2(2) receptor agonists stimulate Cl(-) and fluid secretion. *Am J Physiol Cell Physiol* 2001;281(2):C595–602.
- [686] Li DQ, Luo L, Chen Z, Kim HS, Song XJ, Pflugfelder SC. JNK and ERK MAP kinases mediate induction of IL-1beta, TNF-alpha and IL-8 following hyperosmolar stress in human limbal epithelial cells. *Exp Eye Res* 2006;82(4):588–96.
- [687] Zhang Z, Yang WZ, Zhu ZZ, Hu QQ, Chen YF, He H, et al. Therapeutic effects of topical doxycycline in a benzalkonium chloride-induced mouse dry eye model. *Invest Ophthalmol Vis Sci* 2014;55:2963–74.
- [688] Liu Y, Kam WR, Ding J, Sullivan DA. Can tetracycline antibiotics duplicate the ability of azithromycin to stimulate human meibomian gland epithelial cell differentiation? *Cornea* 2015;34(3):342–6.
- [689] Hoeprich PD, Warshauer DM. Entry of four tetracyclines into saliva and tears. *Antimicrob Agents Chemother* 1974;5(3):330–6.
- [690] Driver PJ, Lem MA. Meibomian gland dysfunction. *Surv Ophthalmol* 1996 Mar-Apr;40(5):343–67.
- [691] Forton F, Germaux MA, Brasseur T, De Liever A, Laporte M, Mathys C, et al. Demodicosis and rosacea: epidemiology and significance in daily dermatologic practice. *J Am Acad Dermatol* 2005;52(1):74–87.
- [692] Mc Aleer MA, Lacey N, Powell FC. The pathophysiology of rosacea. *G Ital Dermatol Venereol* 2009;144(6):663–71.
- [693] Lazaridou E, Giannopoulou C, Fotiadou C, Vakirlis E, Trigoni A, Ioannides D. The potential role of microorganisms in the development of rosacea. *J Dtsch Dermatol Ges* 2011;9(1):21–5.
- [694] Jarmuda S, O'Reilly N, Zaba R, Jakubowicz O, Szkaradkiewicz A, Kavanagh K. Potential role of Demodex mites and bacteria in the induction of rosacea. *J Med Microbiol* 2012;61(Pt 11):1504–10.
- [695] van Zuuren EJ, Fedorowicz Z. Interventions for Rosacea. *JAMA* 2015;314:2403–4.
- [696] van Zuuren EJ, Fedorowicz Z, Carter B, van der Linden MM, Charland L. Interventions for rosacea. *Cochrane Database Syst Rev* 2015;4:CD003262.
- [697] Ding J, Kam WR, Dieckow J, Sullivan DA. The influence of 13-cis retinoic acid on human meibomian gland epithelial cells. *Invest Ophthalmol Vis Sci* 2013;54(6):4341–50.
- [698] Macdonald A, Feiwel M. Perioral dermatitis: aetiology and treatment with tetracycline. *Br J Dermatol* 1972;87(4):315–9.
- [699] Jansen T, Plewig G. Rosacea: classification and treatment. *J R Soc Med* 1997;90(3):144–50.
- [700] Frucht-Pery J, Chayet AS, Feldman ST, Lin S, Brown SI. The effect of doxycycline on ocular rosacea. *Am J Ophthalmol* 1989;107(4):434–5.
- [701] Pfeffer I, Borelli C, Zierhut M, Schaller M. Treatment of ocular rosacea with 40 mg doxycycline in a slow release form. *J Dtsch Dermatol Ges* 2011;9(11):904–7.
- [702] Seal DV, Wright P, Ficker L, Hagan K, Troski M, Menday P. Placebo controlled trial of fusidic acid gel and oxytetracycline for recurrent blepharitis and rosacea. *Br J Ophthalmol* 1995;79(1):42–5.
- [703] Määttä M, Kari O, Tervahartiala T, Peltonen S, Kari M, Saari M, et al. Tear fluid levels of MMP-8 are elevated in ocular rosacea-treatment effect of oral doxycycline. *Graefes Arch Clin Exp Ophthalmol* 2006;244(8):957–62.
- [704] Gulbenkian A, Myers J, Fries D. Hamster flank organ hydrolase and lipase activity. *J Invest Dermatol* 1980;75(4):289–92.
- [705] Lindsley K, Matsumura S, Hatf E, Akpek EK. Interventions for chronic blepharitis. *Cochrane Database Syst Rev* 2012;5:CD005556.
- [706] Voils SA, Evans ME, Lane MT, Schosser RH, Rapp RP. Use of macrolides and tetracyclines for chronic inflammatory diseases. *Ann Pharmacother* 2005;39(1):86–94.
- [707] Aronowicz JD, Shine WE, Oral D, Vargas JM, McCulley JP. Short term oral minocycline treatment of meibomianitis. *Br J Ophthalmol* 2006;90(7):856–60.
- [708] Yoo SE, Lee DC, Chang MH. The effect of low-dose doxycycline therapy in chronic meibomian gland dysfunction. *Korean J Ophthalmol* 2005;19(4):258–63.

- [709] Seitsalo H, Niemelä RK, Marinescu-Gava M, Vuotila T, Tjäderhane L, Salo T. Effectiveness of low-dose doxycycline (LDD) on clinical symptoms of Sjögren's syndrome: a randomized, double-blind, placebo controlled cross-over study. *J Negat Results Biomed* 2007;6:11.
- [710] Lee H, Min K, Kim EK, Kim TI. Minocycline Controls Clinical Outcomes and Inflammatory Cytokines in Moderate and Severe Meibomian Gland Dysfunction. *Am J Ophthalmol* 2012;154(6):949–57.
- [711] Gilbard JP. The scientific context and basis of the pharmacologic management of dry eyes. *Ophthalmol Clin N Am* 2005;18:475–84.
- [712] Del Rosso JQ. A status report on the use of subantimicrobial-dose doxycycline: a review of the biologic and antimicrobial effects of the tetracyclines. *Cutis* 2004;74(2):118–22.
- [713] Skidmore R, Kovach R, Walker C, Thomas J, Bradshaw M, Leyden J, et al. Effects of subantimicrobial-dose doxycycline in the treatment of moderate acne. *Arch Dermatol* 2003;139(4):459–64.
- [714] Velicer CM, Heckbert SR, Lampe JW, Potter JD, Robertson CA, Taplin SH. Antibiotic use in relation to the risk of breast cancer. *JAMA* 2004;291:827–35.
- [715] Velicer CM, Heckbert SR, Rutter C, Lampe JW, Malone K. Association between antibiotic use prior to breast cancer diagnosis and breast tumour characteristics (United States). *Cancer Causes Control* 2006;17(3):307–13.
- [716] García Rodríguez LA, González-Pérez A. Use of antibiotics and risk of breast cancer. *Am J Epidemiol* 2005;161(7):616–9.
- [717] Kashkoul MB, Fazel AJ, Kiavash V, Nojomi M, Ghiasian L. Oral azithromycin versus doxycycline in meibomian gland dysfunction: a randomised double-masked open-label clinical trial. *Br J Ophthalmol* 2015;99(2):199–204.
- [718] Greene JB, Jeng BH, Fintelman RE, Margolis TP. Oral azithromycin for the treatment of meibomitis. *JAMA Ophthalmol* 2014;132(1):121–2.
- [719] Qiao J, Yan X. Emerging treatment options for meibomian gland dysfunction. *Clin Ophthalmol* 2013;7:1797–803.
- [720] Igami TZ, Holzchuh R, Osaki TH, Santo RM, Kara-Jose N, Hida RY. Oral azithromycin for treatment of posterior blepharitis. *Cornea* 2011;30(10):1145–9.
- [721] Bakar O, Demircay Z, Tokar E, Cakir S. Ocular signs, symptoms and tear function tests of papulopustular rosacea patients receiving azithromycin. *J Eur Acad Dermatol Venereol* 2009;23(5):544–9.
- [722] Fernandez-Obregon A. Oral use of azithromycin for the treatment of acne rosacea. *Arch Dermatol* 2004;140(4):489–90.
- [723] Bakar O, Demircay Z, Gürbüz O. Therapeutic potential of azithromycin in rosacea. *Int J Dermatol* 2004;43(2):151–4.
- [724] Giamarellos-Bourboulis EJ. Macrolides beyond the conventional antimicrobials: a class of potent immunomodulators. *Int J Antimicrob Agents* 2008;31(1):12–20.
- [725] Labro MT. *J Antimicrob Chemother* 1998;41(Suppl B):37–46.
- [726] Rubin BK. Immunomodulatory properties of macrolides: overview and historical perspective. *Am J Med* 2004;117(Suppl 9A):2S–4S.
- [727] Modi S, Harting M, Rosen T. Azithromycin as an alternative rosacea therapy when tetracyclines prove problematic. *J Drugs Dermatol* 2008;7(9):898–9.
- [728] Singhi MK, Ghiya BC, Dhabhai RK. Comparison of oral azithromycin pulse with daily doxycycline in the treatment of acne vulgaris. *Indian J Dermatol Venereol Leprol* 2003 Jul-Aug;69(4):274–6.
- [729] Antonio JR, Pegas JR, Cestari TF, Do Nascimento LV. Azithromycin pulses in the treatment of inflammatory and pustular acne: efficacy, tolerability and safety. *J Dermatol Treat* 2008;19(4):210–5.
- [730] Luchs J. Efficacy of topical azithromycin ophthalmic solution 1% in the treatment of posterior blepharitis. *Adv Ther* 2008;25(9):858–70.
- [731] Haque RM, Torkildsen GL, Brubaker K, Zink RC, Kowalski RP, Mah FS, et al. Multicenter open-label study evaluating the efficacy of azithromycin ophthalmic solution 1% on the signs and symptoms of subjects with blepharitis. *Cornea* 2010;29(8):871–7.
- [732] Opitz DL, Tyler KF. Efficacy of azithromycin 1% ophthalmic solution for treatment of ocular surface disease from posterior blepharitis. *Clin Exp Optom* 2011;94(2):200–6.
- [733] Nichols JJ, Bickle KM, Zink RC, Schiewe MD, Haque RM, Nichols KK. Safety and efficacy of topical azithromycin ophthalmic solution 1.0% in the treatment of contact lens-related dry eye. *Eye Contact Lens* 2012;38(2):73–9.
- [734] Fadlallah A, Rami HE, Fahd D, Dunia I, Bejjani R, Chlela E, et al. Azithromycin 1.5% ophthalmic solution: efficacy and treatment modalities in chronic blepharitis. *Arq Bras Oftalmol* 2012 May-Jun;75(3):178–82.
- [735] Hosseini K, Lindstrom RL, Foulks G, Nichols KK. A randomized, double-masked, parallel-group, comparative study to evaluate the clinical efficacy and safety of 1% azithromycin-0.1% dexamethasone combination compared to 1% azithromycin alone, 0.1% dexamethasone alone, and vehicle in the treatment of subjects with blepharitis. *Clin Ophthalmol* 2016;10:1495–503.
- [736] Foulks GN, Borchman D, Yappert M, Kakar S. Topical azithromycin and oral doxycycline therapy of meibomian gland dysfunction: a comparative clinical and spectroscopic pilot study. *Cornea* 2013;32(1):44–53.
- [737] Wladis EJ, Bradley EA, Bilyk JR, Yen MT, Mawn LA. Oral Antibiotics for Meibomian Gland-Related Ocular Surface Disease: A Report by the American Academy of Ophthalmology. *Ophthalmology* 2016;123(3):492–6.
- [738] Kirkness CM, Adams GG, Dilly PN, Lee JP. Botulinum toxin A-induced protective ptosis in corneal disease. *Ophthalmology* 1988;95(4):473–80.
- [739] Gossman MD, Bowe BE, Tanenbaum M. Reversible suture tarsorrhaphy for eyelid malposition and keratopathy. *Ophthalmic Surg* 1991;22(4):237–9.
- [740] Chhadva P, Alexander A, McClellan AL, McManus KT, Seiden B, Galor A. The impact of conjunctivochalasis on dry eye symptoms and signs. *Invest Ophthalmol Vis Sci* 2015;56(5):2867–71.
- [741] Uchino M, Dogru M, Yagi Y, Goto E, Tomita M, Kon T, et al. The features of dry eye disease in a Japanese elderly population. *Optom Vis Sci* 2006;83(11):797–802.
- [742] Hoh H, Schirra F, Kienecker C, Ruprecht KW. Lid-parallel conjunctival folds are a sure diagnostic sign of dry eye. *Ophthalmologie* 1995;92:802–8.
- [743] Németh J, Fodor E, Lang Z, Kosina-Hagyó K, Berta A, Komár T, et al. Lid-parallel conjunctival folds (LIPCOF) and dry eye: a multicentre study. *Br J Ophthalmol* 2012;96(11):1380–5.
- [744] Huang Y, Sheha H, Tseng SC. Conjunctivochalasis interferes with tear flow from fornix to tear meniscus. *Ophthalmology* 2013;120(8):1681–7.
- [745] Pult H, Riede-Pult BH. Impact of conjunctival folds on central tear meniscus height. *Invest Ophthalmol Vis Sci* 2015;56(3):1459–66.
- [746] Liu D. Conjunctivochalasis. A cause of tearing and its management. *Ophthalmol Plast Reconstr Surg* 1986;2:25–8.
- [747] Petris CK, Holds JB. Medial conjunctival resection for tearing associated with conjunctivochalasis. *Ophthalmol Plast Reconstr Surg* 2013 Jul-Aug;29(4):304–7.
- [748] Yokoi N, Inatomi T, Kinoshita S. Surgery of the conjunctiva. *Dev Ophthalmol* 2008;41:138–58.
- [749] Nakasato S, Uemoto R, Mizuki N. Thermocautery for inferior conjunctivochalasis. *Cornea* 2012;31(5):514–9.
- [750] Zhang XR, Zhang ZY, Hoffman MR. Electrocoagulative surgical procedure for treatment of conjunctivochalasis. *Int Surg* 2012 Jan-Mar;97(1):90–3.
- [751] Otaka I, Kyu N. A new surgical technique for management of conjunctivochalasis. *Am J Ophthalmol* 2000;129(3):385–7.
- [752] Yang HS, Choi S. New approach for conjunctivochalasis using an argon green laser. *Cornea* 2013;32(5):574–8.
- [753] Price J, O'Day J. A comparative study of tear secretion in blepharospasm and hemifacial spasm patients treated with botulinum toxin. *J Clin Neuro-ophthalmol* 1993;13(1):67–71.
- [754] Elston JS, Marsden CD, Grandas F, Quinn NP. The significance of ophthalmological symptoms in idiopathic blepharospasm. *Eye (Lond)* 1988;2(Pt 4):435–9.
- [755] Grandas F, Elston J, Quinn N, Marsden CD. Blepharospasm: a review of 264 patients. *J Neurol Neurosurg Psychiatr* 1988;51(6):767–72.
- [756] Jankovic J, Ford J. Blepharospasm and orofacial-cervical dystonia: clinical and pharmacological findings in 100 patients. *Ann Neurol* 1983;13(4):402–11.
- [757] Lu R, Huang R, Li K, Zhang X, Yang H, Quan Y, et al. The influence of benign essential blepharospasm on dry eye disease and ocular inflammation. *Am J Ophthalmol* 2014;157(3):591–7. e1–2.
- [758] Park DI, Shin HM, Lee SY, Lew H. Tear production and drainage after botulinum toxin A injection in patients with essential blepharospasm. *Acta Ophthalmol* 2013;91(2):e108–12.
- [759] Sahlin S, Chen E, Kaugesaar T, Almqvist H, Kjellberg K, Lennerstrand G. Effect of eyelid botulinum toxin injection on lacrimal drainage. *Am J Ophthalmol* 2000;129(4):481–6.
- [760] Kocabeyoglu S, Sekeroglu HT, Mocan MC, Muz E, Irkek M, Sanac AS. Ocular surface alterations in blepharospasm patients treated with botulinum toxin A injection. *Eur J Ophthalmol* 2014 Nov-Dec;24(6):830–4.
- [761] Horwath-Winter J, Bergloeff J, Floegel I, Haller-Schober EM, Schmut O. Botulinum toxin A treatment in patients suffering from blepharospasm and dry eye. *Br J Ophthalmol* 2003;87(1):54–6.
- [762] Sahlin S, Linderth R. Eyelid botulinum toxin injections for the dry eye. *Dev Ophthalmol* 2008;41:187–92.
- [763] Vold SD, Carroll RP, Nelson JD. Dermatochalasis and dry eye. *Am J Ophthalmol* 1993;115(2):216–20.
- [764] Floegel I, Horwath-Winter J, Muellner K, Haller-Schober EM. A conservative blepharoplasty may be a means of alleviating dry eye symptoms. *Acta Ophthalmol Scand* 2003;81(3):230–2.
- [765] Moesen I, van den Bosch W, Wubbels R, Paridaens D. Is dry eye associated with acquired aponeurogenic blepharoptosis? *Orbit* 2014;33(3):173–7.
- [766] Bagheri A, Najimi H, Salim RE, Yazdani S. Tear condition following unilateral ptosis surgery. *Orbit* 2015;34(2):66–71.
- [767] Watanabe A, Kakizaki H, Selva D, Ohmae M, Yokoi N, Wakimasu K, et al. Short-term changes in tear volume after blepharoptosis repair. *Cornea* 2014;33(1):14–7.
- [768] Watanabe A, Selva D, Kakizaki H, Oka Y, Yokoi N, Wakimasu K, et al. Long-term Tear Volume Changes After Blepharoptosis Surgery and Blepharoplasty. *Invest Ophthalmol Vis Sci* 2015;56(1):54–8.
- [769] Prischmann J, Sufyan A, Ting JY, Ruffin C, Perkins SW. Dry eye symptoms and chemosis following blepharoplasty: a 10-year retrospective review of 892 cases in a single-surgeon series. *JAMA Facial Plast Surg* 2013;15:39–46.
- [770] Leatherbarrow B, Saha K. Complications of blepharoplasty. *Facial Plast Surg* 2013;29(4):281–8.
- [771] Shao Chunyi, Fu Yao, Lu Linna, Chen Junzhao, Shen Qin, Zhu Huimin, et al. Dynamic Changes of Tear Fluid After Cosmetic Transcutaneous Lower Blepharoplasty Measured by Optical Coherence Tomography. *Am J Ophthalmol* 2014;158(1):55–63.
- [772] Pacella SJ, Codner MA. Minor complications after blepharoplasty: dry eyes, chemosis, granulomas, ptosis, and scleral show. *Plast Reconstr Surg* 2010;125(2):709–18.
- [773] Honavar SG, Bansal AK, Sangwan VS, Rao GN. Amniotic membrane transplantation for ocular surface reconstruction in Stevens-Johnson syndrome. *Ophthalmology* 2000;107(5):975–9.

- [774] Donnenfeld ED, Perry HD, Wallerstein A, Caronia RM, Kanellopoulos AJ, Sforza PD, et al. Subconjunctival mitomycin C for the treatment of ocular cicatricial pemphigoid. *Ophthalmology* 1999;106:72–8. discussion 9.
- [775] Barabino S, Rolando M, Bentivoglio G, Mingari C, Zanardi S, Bellomo R, et al. Role of amniotic membrane transplantation for conjunctival reconstruction in ocular-cicatricial pemphigoid. *Ophthalmology* 2003;110(3):474–80.
- [776] Clearfield E, Muthappan V, Wang X, Kuo IC. Conjunctival autograft for pterygium. *Cochrane Database Syst Rev* 2016;2:CD011349.
- [777] Kaufman SC, Jacobs DS, Lee WB, Deng SX, Rosenblatt MI, Shtein RM. Options and adjuvants in surgery for pterygium: a report by the American Academy of Ophthalmology. *Ophthalmology* 2013;120(1):201–8.
- [778] Foster CS, Sainz De La Maza M. Ocular cicatricial pemphigoid review. *Curr Opin Allergy Clin Immunol* 2004;4(5):435–9.
- [779] Shay E, Kheirkhah A, Liang L, Sheha H, Gregory DG, Tseng SC. Amniotic membrane transplantation as a new therapy for the acute ocular manifestations of Stevens-Johnson syndrome and toxic epidermal necrolysis. *Surv Ophthalmol* 2009 Nov-Dec;54(6):686–96.
- [780] Arya SK, Bhala S, Malik A, Sood S. Role of amniotic membrane transplantation in ocular surface disorders. *Nepal J Ophthalmol* 2010 Jul-Dec;2(2):145–53.
- [781] Gregory DG. Treatment of acute Stevens-Johnson syndrome and toxic epidermal necrolysis using amniotic membrane: a review of 10 consecutive cases. *Ophthalmology* 2011;118(5):908–14.
- [782] Cheng AM, Zhao D, Chen R, Yin HY, Tighe S, Sheha H, et al. Accelerated Restoration of Ocular Surface Health in Dry Eye Disease by Self-Retained Cryopreserved Amniotic Membrane. *Ocul Surf* 2016;14(1):56–63.
- [783] Dopamine MA, Ishii T, Ono F, Sakuragawa N. Evidence for the presence of elowamine D1 receptor mRNA and binding sites in monkey amniotic epithelial cells. *Neurosci Lett* 1999;262(1):9–12.
- [784] Elwan MA, Thangavel R, Ono F, Sakuragawa N. Synthesis and release of catecholamines by cultured monkey amniotic epithelial cells. *J Neurosci Res* 1998;53(1):107–13.
- [785] Meller D, Schröder A, Steuhl KP, Theiss C. Neurotrophic Effect of Amniotic Membrane on Neuronal Cell Cultures: An in vitro Model to Study Underlying Action Mechanisms of Amniotic Membrane in the Treatment of Neurotrophic Keratopathy. *Invest Ophthalmol Vis Sci* 2005;46:875.
- [786] Sakuragawa N, Elwan MA, Uchida S, Fujii T, Kawashima K. Non-neuronal neurotransmitters and neurotrophic factors in amniotic epithelial cells: expression and function in humans and monkey. *Jpn J Pharmacol* 2001;85(1):20–3.
- [787] Stelnicki EJ, Doolabh V, Lee S, Levis C, Baumann FG, Longaker MT, et al. Nerve dependency in scarless fetal wound healing. *Plast Reconstr Surg* 2000;105(1):140–7.
- [788] Ryff K, Ryff B, Lighthizer N. Insert and remove and amniotic membrane graft. *Rev Optom* 2015;152:23–5.
- [789] Suri K, Kosker M, Raber IM, Hammersmith KM, Nagra PK, Ayres BD, et al. Sutureless amniotic membrane ProKera for ocular surface disorders: short-term results. *Eye Contact Lens* 2013;39(5):341–7.
- [790] Kolomeyer AM, Do BK, Tu Y, Chu DS. Placement of ProKera in the management of ocular manifestations of acute Stevens-Johnson syndrome in an outpatient. *Eye Contact Lens* 2013;39(3):e7–11.
- [791] Kwon JW, Kim JS, Choi SB, Lee JH, Wee WR. Experimental study of an automated system for the delivery of eyedrops using a microinfusion pump. *Am J Ophthalmol* 2005;139(3):547–9.
- [792] Murube J, Murube E, ChenZhuo L, Rivas L. Subcutaneous abdominal artificial tears pump-reservoir for severe dry eye. *Orbit* 2003;22(1):29–40.
- [793] Murube J, Geerling G. Mechanical pump dacryoreservoirs. *Dev Ophthalmol* 2008;41:269–82.
- [794] Geerling G, Honnicke K, Schröder C, Framme C, Sieg P, Lauer I, et al. Quality of salivary tears following autologous submandibular gland transplantation for severe dry eye. *Graefes Arch Clin Exp Ophthalmol* 2000;238(1):45–52.
- [795] Murube J, Manyari A, ChenZhuo L, Rivas L, Murube I. Labial Salivary Gland Transplantation in Severe Dry Eye. *Oper Tech Oculoplast Orbital Reconstr Surg* 1998;2:104–10.
- [796] Filatov V, Chevaljev V. Surgical Treatment of Parenchymatous Ophthalmoxerosis. *J Ophthalmol Odessa* 1951;3:131–7.
- [797] Geerling G, Sieg P. Transplantation of the major salivary glands. *Dev Ophthalmol* 2008;41:255–68.
- [798] Murube-del-Castillo J. Transplantation of salivary gland to the lacrimal basin. *Scand J Rheumatol Suppl* 1986;61:264–7.
- [799] Qin J, Zhang L, Cai ZG, Mao C, Liu XJ, Lv L, et al. Microvascular autologous transplantation of partial submandibular gland for severe keratoconjunctivitis sicca. *Br J Ophthalmol* 2013;97(9):1123–8.
- [800] Geerling G, Garrett JR, Paterson KL, Sieg P, Collin JR, Carpenter GH, et al. Innervation and secretory function of transplanted human submandibular salivary glands. *Transplantation* 2008;85(1):135–40.
- [801] Lasudry J. Experimental approach to surgical treatment of lacrimal insufficiency by microvascular submandibular salivary gland autotransplantation. *Bull Soc Belge Ophthalmol* 1992;245:45–51.
- [802] Kumar PA, Macleod AM, O'Brien BM, Hickey MJ, Knight KR. Microvascular submandibular gland transfer for the management of xerophthalmia; an experimental study. *Br J Plast Surg* 1990;43(4):431–6.
- [803] Murube J, Marcos MG, Javate R. Amylase in mare lacrimale in patients with submandibular salivary gland transplantation to the lacrimal basin. *Adv Exp Med Biol* 1994;350:565–70.
- [804] MacLeod AM, Robbins SP. Submandibular gland transfer in the correction of dry eye. *Aust N Z J Ophthalmol* 1992;20(2):99–103.
- [805] Geerling G, Sieg P, Bastian GO, Laqua H. Transplantation of the autologous submandibular gland for most severe cases of keratoconjunctivitis sicca. *Ophthalmology* 1998;105(2):327–35.
- [806] Paniello RC. Submandibular gland transfer for severe xerophthalmia. *Laryngoscope* 2007;117(1):40–4.
- [807] Borrelli M, Schröder C, Dart JK, Collin JR, Sieg P, Cree IA, et al. Long-term follow-up after submandibular gland transplantation in severe dry eyes secondary to cicatrizing conjunctivitis. *Am J Ophthalmol* 2010;150(6):894–904.
- [808] Lauer I, Sieg P, Bähre M, Richter E. Salivary gland scintigraphy using technetium-99m-pertechnetate after autotransplantation of the submandibular salivary gland in the correction of dry eye. *Eur J Nucl Med* 1998;25(2):128–31.
- [809] Jacobsen HC, Hakim SG, Trenkle T, Nitschke M, Steven P, Sieg P. Allogenic submandibular gland transplantation following hematopoietic stem cell transplantation. *J Craniomaxillofac Surg* 2013;41(8):764–9.
- [810] Keegan DJ, Geerling G, Lee JP, Blake G, Collin JR, Plant GT. Botulinum toxin treatment for hyperlacrimation secondary to aberrant regenerated seventh nerve palsy or salivary gland transplantation. *Br J Ophthalmol* 2002;86(1):43–6.
- [811] Cai JR, Shan XF, Cai ZG, Zhang X, Yu GY. A new treatment for epiphora secondary to submandibular gland transplantation: transcutaneous atropine gel. *Ocul Surf* 2014;12(3):221–6.
- [812] Leibovitch I, Hoyama E, Limawararut V, Crompton J, Selva D. Novel technique to control hypersecretion from a transplanted autologous submandibular salivary gland for keratoconjunctivitis sicca. *Cornea* 2006;25(10):1251–3.
- [813] Song B, Zhang L, Liu XJ, Ding C, Wu LL, Gan YH, et al. Proteomic analysis of secretion from human transplanted submandibular gland replacing lacrimal gland with severe keratoconjunctivitis sicca. *Biochim Biophys Acta* 2012;1824(4):550–60.
- [814] Wenkel H, Rummelt V, Naumann GO. Long term results after autologous nasal mucosal transplantation in severe mucus deficiency syndromes. *Br J Ophthalmol* 2000;84(3):279–84.
- [815] Kuckelkorn R, Schrage N, Redbrake C, Kottek A, Reim M. Autologous transplantation of nasal mucosa after severe chemical and thermal eye burns. *Acta Ophthalmol Scand* 1996;74(5):442–8.
- [816] Wang Z, Shen MM, Liu XJ, Si Y, Yu GY. Characteristics of the saliva flow rates of minor salivary glands in healthy people. *Arch Oral Biol* 2015;60(3):385–92.
- [817] Marinho DR, Burmann TG, Kwitko S. Labial salivary gland transplantation for severe dry eye due to chemical burns and Stevens-Johnson syndrome. *Ophthalmol Plast Reconstr Surg* 2010 May-Jun;26(3):182–4.
- [818] Sant' Anna AE, Hazarbasanov RM, de Freitas D, Gomes JÁ. Minor salivary glands and labial mucous membrane graft in the treatment of severe symblepharon and dry eye in patients with Stevens-Johnson syndrome. *Br J Ophthalmol* 2012;96(2):234–9.
- [819] Fortes MB, Diment BC, Di Felice U, Gunn AE, Kendall JL, Esmaeelpour M, et al. Tear fluid osmolarity as a potential marker of hydration status. *Med Sci Sports Exerc* 2011;43(8):1590–7.
- [820] Walsh NP, Fortes MB, Esmaeelpour M. Influence of modest changes in whole-body hydration on tear fluid osmolarity: important considerations for dry eye disease detection. *Cornea* 2011;30:1517. author reply -8.
- [821] Walsh NP, Fortes MB, Raymond-Barker P, Bishop C, Owen J, Tye E, et al. Is whole-body hydration an important consideration in dry eye? *Invest Ophthalmol Vis Sci* 2012;53(10):6622–7.
- [822] Simopoulos AP. Omega-6/omega-3 essential fatty acids: biological effects. *World Rev Nutr Diet* 2009;99:1–16.
- [823] Harris W. Omega-6 and omega-3 fatty acids: partners in prevention. *Curr Opin Clin Nutr Metab Care* 2010;13(2):125–9.
- [824] Calder PC. N-3 polyunsaturated fatty acids and inflammation: from molecular biology to the clinic. *Lipids* 2003;38(4):343–52.
- [825] Serhan CN, Petasis NA. Resolvins and protectins in inflammation resolution. *Chem Rev* 2011;111(10):5922–43.
- [826] Simopoulos AP. Evolutionary aspects of diet: the omega-6/omega-3 ratio and the brain. *Mol Neurobiol* 2011;44(2):203–15.
- [827] Simopoulos AP. The importance of the ratio of omega-6/omega-3 essential fatty acids. *Biomed Pharmacother* 2002;56(8):365–79.
- [828] Endres S, Ghorbani R, Kelley VE, Georgilis K, Lonnemann G, van der Meer JW, et al. The effect of dietary supplementation with n-3 polyunsaturated fatty acids on the synthesis of interleukin-1 and tumor necrosis factor by mononuclear cells. *N Engl J Med* 1989;320(5):265–71.
- [829] Meydani SN, Endres S, Woods MM, Goldin BR, Soo C, Morrill-Labrode A, et al. Oral (n-3) fatty acid supplementation suppresses cytokine production and lymphocyte proliferation: comparison between young and older women. *J Nutr* 1991;121:547–55.
- [830] Khan NA, Yessoufou A, Kim M, Hichami A. N-3 fatty acids modulate Th1 and Th2 dichotomy in diabetic pregnancy and macrosomia. *J Autoimmun* 2006;26(4):268–77.
- [831] Purasiri P, Mckechnie A, Heys SD, Eremin O. Modulation in vitro of human natural cytotoxicity, lymphocyte proliferative response to mitogens and cytokine production by essential fatty acids. *Immunology* 1997;92(2):166–72.
- [832] Zurier RB, Rossetti RG, Seiler CM, Laposata M. Human peripheral blood T

- lymphocyte proliferation after activation of the T cell receptor: effects of unsaturated fatty acids. *Prostaglandins Leukot Essent Fatty Acids* 1999;60(5–6):371–5.
- [833] Hampel U, Krüger M, Kunnen C, Garreis F, Willcox M, Paulsen F. In vitro effects of docosahexaenoic and eicosapentaenoic acid on human meibomian gland epithelial cells. *Exp Eye Res* 2015;140:139–48.
- [834] Liu Y, Kam WR, Sullivan DA. Influence of Omega 3 and 6 Fatty Acids on Human Meibomian Gland Epithelial Cells. *Cornea* 2016;35(8):1122–6.
- [835] Schnebel C, Viau S, Grégoire S, Joffre C, Creuzot-Garcher CP, Bron AM, et al. Nutrition for the eye: different susceptibility of the retina and the lacrimal gland to dietary omega-6 and omega-3 polyunsaturated fatty acid incorporation. *Ophthalmic Res* 2009;41(4):216–24.
- [836] Viau S, Maire MA, Pasquis B, Grégoire S, Acar N, Bron AM, et al. Efficacy of a 2-month dietary supplementation with polyunsaturated fatty acids in dry eye induced by scopolamine in a rat model. *Graefes Arch Clin Exp Ophthalmol* 2009;247(8):1039–50.
- [837] Rashid S, Jin Y, Ecoiffier T, Barabino S, Schaumberg DA, Dana MR. Topical omega-3 and omega-6 fatty acids for treatment of dry eye. *Arch Ophthalmol* 2008;126(2):219–25.
- [838] Li Z, Choi JH, Oh HJ, Park SH, Lee JB, Yoon KC. Effects of eye drops containing a mixture of omega-3 essential fatty acids and hyaluronic acid on the ocular surface in desiccating stress-induced murine dry eye. *Curr Eye Res* 2014;39(9):871–8.
- [839] Dartt DA, Hodges RR, Li D, Shatos MA, Lashkari K, Serhan CN. Conjunctival goblet cell secretion stimulated by leukotrienes is reduced by resolvins D1 and E1 to promote resolution of inflammation. *J Immunol* 2011;186(7):4455–66.
- [840] Erdinest N, Ovadia H, Kormas R, Solomon A. Anti-inflammatory effects of resolvins-D1 on human corneal epithelial cells: in vitro study. *J Inflamm (Lond)* 2014;11(1):6.
- [841] Li N, He J, Schwartz CE, Gjørstrup P, Bazan HE. Resolvin E1 improves tear production and decreases inflammation in a dry eye mouse model. *J Ocul Pharmacol Ther* 2010;26(5):431–9.
- [842] de Paiva Cintia S, Schwartz C Eric, Gjørstrup Per, Pflugfelder Stephen C. Resolvin E1 (RX-10001) Reduces Corneal Epithelial Barrier Disruption and Protects Against Goblet Cell Loss in a Murine Model of Dry Eye. *Cornea* 2012;31(11):1299–303.
- [843] Torricelli AA, Santhanam A, Agrawal V, Wilson SE. Resolvin E1 analog RX-10045 0.1% reduces corneal stromal haze in rabbits when applied topically after PRK. *Mol Vis* 2014;20:1710–6.
- [844] Cortina MS, He J, Li N, Bazan NG, Bazan HE. Neuroprotectin D1 synthesis and corneal nerve regeneration after experimental surgery and treatment with PEDF plus DHA. *Invest Ophthalmol Vis Sci* 2010;51(2):804–10.
- [845] Cortina MS, He J, Li N, Bazan NG, Bazan HE. Recovery of corneal sensitivity, calcitonin gene-related peptide-positive nerves, and increased wound healing induced by pigment epithelial-derived factor plus docosahexaenoic acid after experimental surgery. *Arch Ophthalmol* 2012;130(1):76–83.
- [846] Miljanovic B, Trivedi KA, Dana MR, Gilbard JP, Buring JE, Schaumberg DA. Relation between dietary n-3 and n-6 fatty acids and clinically diagnosed dry eye syndrome in women. *Am J Clin Nutr* 2005;82:887–93.
- [847] Walter SD, Gronert K, McClellan AL, Levitt RC, Sarantopoulos KD, Galor A. ω -3 Tear Film Lipids Correlate With Clinical Measures of Dry Eye. *Invest Ophthalmol Vis Sci* 2016;57(6):2472–8.
- [848] Sullivan BD, Cermak JM, Sullivan RM, Pappas AS, Evans JE, Dana MR, et al. Correlations between nutrient intake and the polar lipid profiles of meibomian gland secretions in women with Sjögren's syndrome. *Adv Exp Med Biol* 2002;506(Pt A):441–7.
- [849] Macsai MS. The role of omega-3 dietary supplementation in blepharitis and meibomian gland dysfunction (an AOS thesis). *Trans Am Ophthalmol Soc* 2008;106:336–56.
- [850] Wojtowicz JC, Butovich I, Uchiyama E, Aronowicz J, Agee S, McCulley JP. Pilot, prospective, randomized, double-masked, placebo-controlled clinical trial of an omega-3 supplement for dry eye. *Cornea* 2011;30(3):308–14.
- [851] Bhargava R, Kumar P, Kumar M, Mehra N, Mishra A. A randomized controlled trial of omega-3 fatty acids in dry eye syndrome. *Int J Ophthalmol* 2013;6(6):811–6.
- [852] Olenik A, Jiménez-Alfaro I, Alejandre-Alba N, Mahillo-Fernández I. A randomized, double-masked study to evaluate the effect of omega-3 fatty acids supplementation in meibomian gland dysfunction. *Clin Interv Aging* 2013;8:1133–8.
- [853] Kawakita T, Kawabata F, Tsuji T, Kawashima M, Shimmura S, Tsubota K. Effects of dietary supplementation with fish oil on dry eye syndrome subjects: randomized controlled trial. *Biomed Res* 2013;34(5):215–20.
- [854] Kangari H, Eftekhari MH, Sardari S, Hashemi H, Salamzadeh J, Ghassemi-Broumand M, et al. Short-term consumption of oral omega-3 and dry eye syndrome. *Ophthalmology* 2013;120(11):2191–6.
- [855] Pinazo-Durán MD, Galbis-Estrada C, Pons-Vázquez S, Cantú-Diboldo J, Marco-Ramírez C, Benítez-del-Castillo J. Effects of a nutraceutical formulation based on the combination of antioxidants and ω -3 essential fatty acids in the expression of inflammation and immune response mediators in tears from patients with dry eye disorders. *Clin Interv Aging* 2013;8:139–48.
- [856] Olenik A. Effectiveness and tolerability of dietary supplementation with a combination of omega-3 polyunsaturated fatty acids and antioxidants in the treatment of dry eye symptoms: results of a prospective study. *Clin Ophthalmol* 2014;8:169–76.
- [857] Bhargava R, Kumar P, Arora Y. Short-Term Omega 3 Fatty Acids Treatment for Dry Eye in Young and Middle-Aged Visual Display Terminal Users. *Eye Contact Lens* 2016;42(4):231–6.
- [858] Deinema LA, Vingrys AJ, Wong CY, Jackson DC, Chinnery HR, Downie LE. A Randomized, Double-Masked, Placebo-Controlled Clinical Trial of Two Forms of Omega-3 Supplements for Treating Dry Eye Disease. *Ophthalmology* 2017;124(1):43–52.
- [859] Epitropoulos AT, Donnenfeld ED, Shah ZA, Holland EJ, Gross M, Faulkner WJ, et al. Effect of Oral Re-esterified Omega-3 Nutritional Supplementation on Dry Eyes. *Cornea* 2016;35(9):1185–91.
- [860] Chinnery HR, Naranjo Golborne C, Downie LE. Omega-3 supplementation is neuroprotective to corneal nerves in dry eye disease: a pilot study. *Ophthalmic Physiol Opt* 2017 Jul;37(4):473–81.
- [861] Liu A, Ji J. Omega-3 essential fatty acids therapy for dry eye syndrome: a meta-analysis of randomized controlled studies. *Med Sci Monit* 2014;20:1583–9.
- [862] Buckley MS, Goff AD, Knapp WE. Fish oil interaction with warfarin. *Ann Pharmacother* 2004;38(1):50–2.
- [863] Roncone M, Bartlett H, Eperjesi F. Essential fatty acids for dry eye: A review. *Cont Lens Anter Eye* 2010;33:49–54. quiz 100.
- [864] Brasky TM, Darke AK, Song X, Tangen CM, Goodman PJ, Thompson IM, et al. Plasma phospholipid fatty acids and prostate cancer risk in the SELECT trial. *J Natl Cancer Inst* 2013;105(15):1132–41.
- [865] Brenna JT, Burdge GC, Crawford MA, Clayton P, Cunnane SC, Gow R, et al. RE: Plasma phospholipid fatty acids and prostate cancer risk in the SELECT trial. *J Natl Cancer Inst* 2014;106:dju015.
- [866] Szymanski KM, Wheeler DC, Mucci LA. Fish consumption and prostate cancer risk: a review and meta-analysis. *Am J Clin Nutr* 2010;92(5):1223–33.
- [867] Manthorpe R, Hagen Petersen S, Prause JU. Primary Sjögren's syndrome treated with Efamol/Efavit. A double-blind cross-over investigation. *Rheumatol Int* 1984;4(4):165–7.
- [868] Oxholm P, Manthorpe R, Prause JU, Horrobin D. Patients with primary Sjögren's syndrome treated for two months with evening primrose oil. *Scand J Rheumatol* 1986;15(2):103–8.
- [869] Theander E, Horrobin DF, Jacobsson LT, Manthorpe R. Gammalinolenic acid treatment of fatigue associated with primary Sjögren's syndrome. *Scand J Rheumatol* 2002;31(2):72–9.
- [870] Aragona P, Bucolo C, Spinella R, Giuffrida S, Ferreri G. Systemic omega-6 essential fatty acid treatment and pge1 tear content in Sjögren's syndrome patients. *Invest Ophthalmol Vis Sci* 2005;46(12):4474–9.
- [871] Pinna A, Piccinini P, Carta F. Effect of oral linoleic and gamma-linolenic acid on meibomian gland dysfunction. *Cornea* 2007;26(3):260–4.
- [872] Creuzot C, Passemard M, Viau S, Joffre C, Pouliquen P, Elena PP, et al. Improvement of dry eye symptoms with polyunsaturated fatty acids. *J Fr Ophthalmol* 2006;29:868–73.
- [873] Larmo PS, Järvinen RL, Setälä NL, Yang B, Viitanen MH, Engblom JR, et al. Oral sea buckthorn oil attenuates tear film osmolarity and symptoms in individuals with dry eye. *J Nutr* 2010;140(8):1462–8.
- [874] Brignole-Baudouin F, Baudouin C, Aragona P, Rolando M, Labetoulle M, Pisella PJ, et al. A multicentre, double-masked, randomized, controlled trial assessing the effect of oral supplementation of omega-3 and omega-6 fatty acids on a conjunctival inflammatory marker in dry eye patients. *Acta Ophthalmol* 2011;89(7):e591–7.
- [875] Jackson MA, Burrell K, Gaddie IB, Richardson SD. Efficacy of a new prescription-only medical food supplement in alleviating signs and symptoms of dry eye, with or without concomitant cyclosporine A. *Clin Ophthalmol* 2011;5:1201–6.
- [876] Creuzot-Garcher C, Baudouin C, Labetoulle M, Pisella PJ, Mouriaux F, Meddeb-Ouertani A, et al. Efficacy assessment of Nutrilarm(R), a per os omega-3 and omega-6 polyunsaturated essential fatty acid dietary formulation versus placebo in patients with bilateral treated moderate dry eye syndrome. *J Fr Ophthalmol* 2011;34:448–55.
- [877] Sheppard Jr JD, Singh R, McClellan AJ, Weikert MP, Scoper SV, Joly TJ, et al. Long-term Supplementation With n-6 and n-3 PUFAs Improves Moderate-to-Severe Keratoconjunctivitis Sicca: A Randomized Double-Blind Clinical Trial. *Cornea* 2013;32(10):1297–304.
- [878] Zhu W, Wu Y, Li G, Wang J, Li X. Efficacy of polyunsaturated fatty acids for dry eye syndrome: a meta-analysis of randomized controlled trials. *Nutr Rev* 2014;72(10):662–71.
- [879] Ng SM, Lindsley K, Akpek EK. Omega-3 and omega-6 polyunsaturated fatty acids for dry eye syndrome (Protocol). *Cochrane Database Syst Rev* 2014;3:CD011016.
- [880] Ren J, Mozurkewich EL, Sen A, Vahratian AM, Ferreri TG, Morse AN, et al. Total Serum Fatty Acid Analysis by GC-MS: Assay Validation and Serum Sample Stability. *Curr Pharm Anal* 2013;9(4):331–9.
- [881] Danjo Y, Lee M, Horimoto K, Hamano T. Ocular surface damage and tear lactoferrin in dry eye syndrome. *Acta Ophthalmol (Copenh)* 1994;72(4):433–7.
- [882] Boukes RJ, Boonstra A, Breebaart AC, Reits D, Glasius E, Luyendyk L, et al. Analysis of human tear protein profiles using high performance liquid chromatography (HPLC). *Doc Ophthalmol* 1987 Sep-Oct;67(1–2):105–13.
- [883] Seal DV. The effect of ageing and disease on tear constituents. *Trans Ophthalmol Soc U K* 1985;104(Pt 4):355–62.
- [884] Mackie IA, Seal DV. Diagnostic implications of tear protein profiles. *Br J Ophthalmol* 1984;68(5):321–4.

- [885] Goren MB, Goren SB. Diagnostic tests in patients with symptoms of keratoconjunctivitis sicca. *Am J Ophthalmol* 1988;106(5):570–4.
- [886] Versura P, Nanni P, Bavelloni A, Blalock WL, Piazzini M, Roda A, et al. Tear proteomics in evaporative dry eye disease. *Eye (Lond)* 2010;24(8):1396–402.
- [887] Kawashima M, Kawakita T, Inaba T, Okada N, Ito M, Shimmura S, et al. Dietary lactoferrin alleviates age-related lacrimal gland dysfunction in mice. *PLoS One* 2012;7:e33148.
- [888] Dogru M, Matsumoto Y, Yamamoto Y, Goto E, Saiki M, Shimazaki J, et al. Lactoferrin in Sjögren's syndrome. *Ophthalmology* 2007;114(12):2366–7.
- [889] Devendra J, Singh S. Effect of Oral Lactoferrin on Cataract Surgery Induced Dry Eye: A Randomised Controlled Trial. *J Clin Diagn Res* 2015;9(10):NC06–9.
- [890] Dogru M, Wakamatsu T, Kojima T, Matsumoto Y, Kawakita T, Schnider C, et al. The role of oxidative stress and inflammation in dry eye disease. *Cornea* 2009;28(suppl1):S70–S4.
- [891] Blades KJ, Patel S, Aidoo KE. Oral antioxidant therapy for marginal dry eye. *Eur J Clin Nutr* 2001;55(7):589–97.
- [892] Drouault-Holowacz S, Bieuevet S, Burckel A, Rigal D, Dubray C, Lichon JL, et al. Antioxidants intake and dry eye syndrome: a crossover, placebo-controlled, randomized trial. *Eur J Ophthalmol* 2009 May-Jun;19(3):337–42.
- [893] Hitoe S, Tanaka J, Shimoda H, MaquiBright standardized maqui berry extract significantly increases tear fluid production and ameliorates dry eye-related symptoms in a clinical pilot trial. *Panminerva Med* 2014;56:1–6.
- [894] Cakatay U. Pro-oxidant actions of alpha-lipoic acid and dihydrolipoic acid. *Med Hypotheses* 2006;66(1):110–7.
- [895] Andrade AS, Salomon TB, Behling CS, Mahl CD, Hackenhaar FS, Putti J, et al. Alpha-lipoic acid restores tear production in an animal model of dry eye. *Exp Eye Res* 2014;120:1–9.
- [896] Kawashima M, Tsubota K. Effect of calorie restriction on change in lacrimal gland with age. *Cornea* 2011;30(Suppl 1):S29–33.
- [897] Kawashima M, Nakamura S, Izuta Y, Inoue S, Tsubota K. Dietary Supplementation with a Combination of Lactoferrin, Fish Oil, and Enterococcus faecium WB2000 for Treating Dry Eye: A Rat Model and Human Clinical Study. *Ocul Surf* 2016;14(2):255–63.
- [898] Ho KC, Jalbert I, Watt K, Golebiowski BA. Possible Association Between Dry Eye Symptoms and Body Fat: A Prospective, Cross-Sectional Preliminary Study. *Eye Contact Lens* 2017. In press.
- [899] Kim JH, Kim JH, Nam WH, Yi K, Choi DG, Hyon JY, et al. Oral alcohol administration disturbs tear film and ocular surface. *Ophthalmology* 2012;119(5):965–71.
- [900] Choi W, Kim JC, Kim WS, Oh HJ, Yang JM, Lee JB, et al. Clinical Effect of Antioxidant Glasses Containing Extracts of Medicinal Plants in Patients with Dry Eye Disease: A Multi-Center, Prospective, Randomized, Double-Blind, Placebo-Controlled Trial. *PLoS One* 2015;10:e0139761.
- [901] Pisella PJ, Pouliquen P, Baudouin C. Prevalence of ocular symptoms and signs with preserved and preservative free glaucoma medication. *Br J Ophthalmol* 2002;86(4):418–23.
- [902] Jaenen N, Baudouin C, Pouliquen P, Manni G, Figueiredo A, Zeyen T. Ocular symptoms and signs with preserved and preservative-free glaucoma medications. *Eur J Ophthalmol* 2007 May-Jun;17(3):341–9.
- [903] Leung EW, Medeiros FA, Weinreb RN. Prevalence of ocular surface disease in glaucoma patients. *J Glaucoma* 2008;17(5):350–5.
- [904] Erb C, Gast U, Schremmer D. German register for glaucoma patients with dry eye. I. Basic outcome with respect to dry eye. *Graefes Arch Clin Exp Ophthalmol* 2008;246(11):1593–601.
- [905] Fechtner RD, Godfrey DG, Budenz D, Stewart JA, Stewart WC, Jasek MC. Prevalence of ocular surface complaints in patients with glaucoma using topical intraocular pressure-lowering medications. *Cornea* 2010;29(6):618–21.
- [906] Rossi GC, Pasinetti GM, Scudeller L, Raimondi M, Lanteri S, Bianchi PE. Risk factors to develop ocular surface disease in treated glaucoma or ocular hypertension patients. *Eur J Ophthalmol* 2013 May-Jun;23(3):296–302.
- [907] Chen HY, Lin CL, Tsai YY, Kao CH. Association between Glaucoma Medication Usage and Dry Eye in Taiwan. *Optom Vis Sci* 2015;92(9):e227–32.
- [908] Iester M, Telani S, Frezzotti P, Motolese I, Figus M, Fogagnolo P, et al. Ocular surface changes in glaucoma patients treated with and without preservatives beta-blockers. *J Ocul Pharmacol Ther* 2014;30(6):476–81.
- [909] Ciancaglini M, Carpineto P, Agnifili L, Nubile M, Fasanella V, Lanzini M, et al. An in vivo confocal microscopy and impression cytology analysis of preserved and unpreserved levobunolol-induced conjunctival changes. *Eur J Ophthalmol* 2008;18:400–7.
- [910] Renieri G, Führer K, Scheith K, Lorenz K, Pfeiffer N, Thieme H. Efficacy and tolerability of preservative-free eye drops containing a fixed combination of dorzolamide and timolol in glaucoma patients. *J Ocul Pharmacol Ther* 2010;26(6):597–603.
- [911] Uusitalo H, Chen E, Pfeiffer N, Brignole-Baudouin F, Kaarniranta K, Leino M, et al. Switching from a preserved to a preservative-free prostaglandin preparation in topical glaucoma medication. *Acta Ophthalmol* 2010;88(3):329–36.
- [912] Freeman P, David, Kahook Malik Y. Preservatives in topical ophthalmic medications: historical and clinical perspectives. *Expert Rev Ophthalmol* 2009;4(1):59–64.
- [913] Labbé A, Pauly A, Liang H, Brignole-Baudouin F, Martin C, Warnet JM, et al. Comparison of toxicological profiles of benzalkonium chloride and polyquaternium-1: an experimental study. *J Ocul Pharmacol Ther* 2006;22(4):267–78.
- [914] Henry JC, Peace JH, Stewart JA, Stewart WC. Efficacy, safety, and improved tolerability of travoprost BAK-free ophthalmic solution compared with prior prostaglandin therapy. *Clin Ophthalmol* 2008;2(3):613–21.
- [915] Katz G, Springs CL, Craven ER, Montecchi-Palmer M. Ocular surface disease in patients with glaucoma or ocular hypertension treated with either BAK-preserved latanoprost or BAK-free travoprost. *Clin Ophthalmol* 2010;4:1253–61.
- [916] Aihara M, Oshima H, Araie M, group EXs. Effects of SofZia-preserved travoprost and benzalkonium chloride-preserved latanoprost on the ocular surface – a multicentre randomized single-masked study. *Acta Ophthalmol* 2013;91:e7–14.
- [917] Wong J, Lan W, Ong LM, Tong L. Non-hormonal systemic medications and dry eye. *Ocul Surf* 2011;9(4):212–26.
- [918] Yokoi N, Bron AJ, Georgiev GA. The precorneal tear film as a fluid shell: the effect of blinking and saccades on tear film distribution and dynamics. *Ocul Surf* 2014;12(4):252–66.
- [919] Tsubota K, Nakamori K. Dry eyes and video display terminals. *N Engl J Med* 1993;328(8):584.
- [920] Tsubota K, Nakamori K. Effects of ocular surface area and blink rate on tear dynamics. *Arch Ophthalmol* 1995;113(2):155–8.
- [921] Uchino M, Yokoi N, Uchino Y, Dogru M, Kawashima M, Komuro A, et al. Prevalence of dry eye disease and its risk factors in visual display terminal users: the Osaka study. *Am J Ophthalmol* 2013;156(4):759–66.
- [922] Stapleton F, Alves M, Bunya VY, Jalbert I, Lekhanont K, Malet F, et al. TFOS DEWS II Epidemiology report. *Ocul Surf* 2017;15:334–65.
- [923] Uchino M, Schaumberg DA, Dogru M, Uchino Y, Fukagawa K, Shimmura S, et al. Prevalence of dry eye disease among Japanese visual display terminal users. *Ophthalmology* 2008;115(11):1982–8.
- [924] Fenga C, Aragona P, Cacciola A, Spinella R, Di Nola C, Ferreri F, et al. Meibomian gland dysfunction and ocular discomfort in video display terminal workers. *Eye (Lond)* 2008;22(1):91–5.
- [925] Wu H, Wang Y, Dong N, Yang F, Lin Z, Shang X, et al. Meibomian gland dysfunction determines the severity of the dry eye conditions in visual display terminal workers. *PLoS One* 2014;9:e105575.
- [926] Uchino Y, Uchino M, Yokoi N, Dogru M, Kawashima M, Okada N, et al. Alteration of tear mucin 5AC in office workers using visual display terminals: The Osaka Study. *JAMA Ophthalmol* 2014;132(8):985–92.
- [927] Nakamura S, Shibuya M, Nakashima H, Hisamura R, Masuda N, Imagawa T, et al. Involvement of oxidative stress on corneal epithelial alterations in a blink-suppressed dry eye. *Invest Ophthalmol Vis Sci* 2007;48:1552–8.
- [928] Miura DL, Hazarbasanov RM, Yamasato CK, Bandeira e Silva F, Godinho CJ, Gomes JA. Effect of a light-emitting timer device on the blink rate of non-dry eye individuals and dry eye patients. *Br J Ophthalmol* 2013;97(8):965–7.
- [929] Cardona G, Gómez M, Quevedo L, Gispest J. Effects of transient blur and VDT screen luminance changes on eyeblink rate. *Cont Lens Anter Eye* 2014;37(5):363–7.
- [930] Blehm C, Vishnu S, Khattak A, Mitra S, Yee RW. Computer vision syndrome: a review. *Surv Ophthalmol* 2005 May-Jun;50(3):253–62.
- [931] McCulley JP, Uchiyama E, Aronowicz JD, Butovich IA. Impact of evaporation on aqueous tear loss. *Trans Am Ophthalmol Soc* 2006;104:121–8.
- [932] Abusharha AA, Pearce EI. The effect of low humidity on the human tear film. *Cornea* 2013;32(4):429–34.
- [933] Alex A, Edwards A, Hays JD, Kerkstra M, Shih A, de Paiva CS, et al. Factors predicting the ocular surface response to desiccating environmental stress. *Invest Ophthalmol Vis Sci* 2013;54:3325–32.
- [934] López-Miguel A, Tesón M, Martín-Montañez V, Enríquez-de-Salamanca A, Stern ME, Calonge M, et al. Dry eye exacerbation in patients exposed to desiccating stress under controlled environmental conditions. *Am J Ophthalmol* 2014;157(4):788–98. e2.
- [935] Lopez-Miguel A, Teson M, Martin-Montanez V, Enriquez-de-Salamanca A, Stern ME, Gonzalez-Garcia MJ, et al. Clinical and Molecular Inflammatory Response in Sjogren Syndrome-Associated Dry Eye Patients Under Desiccating Stress. *Am J Ophthalmol* 2016;161:133–41 e1–2.
- [936] Oh HJ, Li Z, Park SH, Yoon KC. Effect of hypotonic 0.18% sodium hyaluronate eyedrops on inflammation of the ocular surface in experimental dry eye. *J Ocul Pharmacol Ther* 2014;30(7):533–42.
- [937] Hill-Bator A, Misiuk-Hojto M, Marycz K, Grzesiak J. Trehalose-based eye drops preserve viability and functionality of cultured human corneal epithelial cells during desiccation. *Biomed Res Int* 2014;2014:292139.
- [938] Moore QL, De Paiva CS, Pflugfelder SC. Effects of Dry Eye Therapies on Environmentally Induced Ocular Surface Disease. *Am J Ophthalmol* 2015;160(1):135–42. e1.
- [939] Dohlman TH, Chauhan SK, Kodati S, Hua J, Chen Y, Omoto M, et al. The CCR6/CCL20 axis mediates Th17 cell migration to the ocular surface in dry eye disease. *Invest Ophthalmol Vis Sci* 2013;54(6):4081–91.
- [940] Goyal S, Chauhan SK, Zhang Q, Dana R. Amelioration of murine dry eye disease by topical antagonist to chemokine receptor 2. *Arch Ophthalmol* 2009;127(7):882–7.
- [941] Urashima Hiroki, Takeji Yasuhiro, Okamoto Takashi, Fujisawa Shigeki, Shinohara Hisashi. Rebamipide Increases Mucin-Like Substance Contents and Periodic Acid Schiff Reagent-Positive Cells Density in Normal Rabbits. *J Ocul Pharmacol Ther* 2012;28(3):264–70.

- [942] Nakamura S, Shibuya M, Nakashima H, Imagawa T, Uehara M, Tsubota K. D-beta-hydroxybutyrate protects against corneal epithelial disorders in a rat dry eye model with jogging board. *Invest Ophthalmol Vis Sci* 2005;46:2379–87.
- [943] Hirayama M, Murat D, Liu Y, Kojima T, Kawakita T, Tsubota K. Efficacy of a novel moist cool air device in office workers with dry eye disease. *Acta Ophthalmol* 2013;91(8):756–62.
- [944] Willis RM, Folberg R, Krachmer JH, Holland EJ. The treatment of aqueous-deficient dry eye with removable punctal plugs: A clinical and impression-cytologic study. *Ophthalmology* 1987;94(5):514–8.
- [945] Tsubota K, Yamada M, Urayama K. Spectacle side panels and moist inserts for the treatment of dry-eye patients. *Cornea* 1994;13(3):197–201.
- [946] Yee RW, Sperling HG, Kattak A, Paukert MT, Dawson K, Garcia M, et al. Isolation of the ocular surface to treat dysfunctional tear syndrome associated with computer use. *Ocul Surf* 2007;5(4):308–15.
- [947] Wakamatsu TH, Dogru M, Tsubota K. Tearful relations: oxidative stress, inflammation and eye diseases. *Arq Bras Oftalmol* 2008 Nov-Dec;71(6 Suppl):72–9.
- [948] Satici A, Bitiren M, Ozardali I, Vural H, Kilic A, Guzey M. The effects of chronic smoking on the ocular surface and tear characteristics: a clinical, histological and biochemical study. *Acta Ophthalmol Scand* 2003;81(6):583–7.
- [949] Altinors DD, Akça S, Akova YA, Bilezikçi B, Goto E, Dogru M, et al. Smoking associated with damage to the lipid layer of the ocular surface. *Am J Ophthalmol* 2006;141(6):1016–21.
- [950] Thomas J, Jacob GP, Abraham L, Noushad B. The effect of smoking on the ocular surface and the precorneal tear film. *Australas Med J* 2012;5(4):221–6.
- [951] Matsumoto Y, Dogru M, Goto E, Sasaki Y, Inoue H, Saito I, et al. Alterations of the tear film and ocular surface health in chronic smokers. *Eye (Lond)* 2008;22(7):961–8.
- [952] Rummenie VT, Matsumoto Y, Dogru M, Wang Y, Hu Y, Ward SK, et al. Tear cytokine and ocular surface alterations following brief passive cigarette smoke exposure. *Cytokine* 2008;43(2):200–8.
- [953] Jones L, Brennan NA, González-Mejome J, Lally J, Maldonado-Codina C, Schmidt TA, et al. The TFOS International Workshop on Contact Lens Discomfort: report of the contact lens materials, design, and care subcommittee. *Invest Ophthalmol Vis Sci* 2013;54(11):TFOS37–70.
- [954] Efron N, Jones L, Bron AJ, Knop E, Arita R, Barabino S, et al. The TFOS International Workshop on Contact Lens Discomfort: report of the contact lens interactions with the ocular surface and adnexa subcommittee. *Invest Ophthalmol Vis Sci* 2013;54:TFOS98–122.
- [955] Zhou WY, Li YH. A survey on treatment of dry eye by traditional chinese medicine and integrative chinese and Western medicine. *Chin J Integr Med* 2006;12(2):154–9.
- [956] Wu GL, Pu XH, Li TY, Yu GY, Lu WW, Fan YS. Effect of yangyin yiqi huoxue recipe on immune balance of Th1/Th2 in serum and submaxillary glands of NOD mice with Sjögren's syndrome. *Zhongguo Zhong Xi Yi Jie He Za Zhi* 2013;33:1653–7.
- [957] Wu X, Ren C, Zhou H, Zhang L, Juan C, Yang Y. Therapeutic effect of Zeng Ye decoction on primary Sjögren's syndrome via upregulation of aquaporin1 and aquaporin5 expression levels. *Mol Med Rep* 2014;10(1):429–34.
- [958] Luo H, Li X, Liu J, Andrew F, George L. Chinese Herbal Medicine in Treating Primary Sjögren's Syndrome: A Systematic Review of Randomized Trials. *Evid Based Complement Altern Med* 2012;2012:640658.
- [959] Chang YH, Lin HJ, Li WC. Clinical evaluation of the traditional chinese prescription Chi-Ju-Di-Huang-Wan for dry eye. *Phytother Res* 2005;19(4):349–54.
- [960] Hu W, Qian X, Guo F, Zhang M, Lyu C, Tao J, et al. Traditional Chinese medicine compound ShengJinRunZaoYangXue granules for treatment of primary Sjögren's syndrome: a randomized, double-blind, placebo-controlled clinical trial. *Chin Med J* 2014;127(15):2721–6.
- [961] Boukraa L. Additive activity of royal jelly and honey against *Pseudomonas aeruginosa*. *Altern Med Rev* 2008;13(4):330–3.
- [962] Tartakovskaia AI. Apilak (royal jelly) in the therapy of trophic disorders of the cornea in eye burns. *Vestn Oftalmol* 1966;79:59–61.
- [963] Hussein SZ, Yusoff KM, Makpol S, Yusof YA. Antioxidant capacities and total phenolic contents increase with gamma irradiation in two types of Malaysian honey. *Molecules* 2011;16(8):6378–95.
- [964] Lusby PE, Coombes AL, Wilkinson JM. Bactericidal activity of different honeys against pathogenic bacteria. *Arch Med Res* 2005 Sep-Oct;36(5):464–7.
- [965] Imada T, Nakamura S, Kitamura N, Shibuya I, Tsubota K. Oral administration of royal jelly restores tear secretion capacity in rat blink-suppressed dry eye model by modulating lacrimal gland function. *PLoS One* 2014;9:e106338.
- [966] Albiets JM, Lenton LM. Effect of antibacterial honey on the ocular flora in tear deficiency and meibomian gland disease. *Cornea* 2006;25(9):1012–9.
- [967] Craig JP, Rupenthal ID, Seyfoddin A, Cheung IM, Uy B, Wang MT, et al. Pre-clinical development of MGO Manuka Honey microemulsion for blepharitis management. *BMJ Open Ophthalmol* 2017;0:e000065.
- [968] Craig JP, Wang MT, Ganesalingam K, Rupenthal ID, Swift S, Loh CS, et al. Randomised masked trial of the clinical safety and tolerability of MGO Manuka Honey eye cream for the management of blepharitis. *BMJ Open Ophthalmol* 2017;0:e000066.
- [969] Ajite KO, Fadamiro OC. Prevalence of harmful/traditional medication use in traumatic eye injury. *Glob J Health Sci* 2013;5(4):55–9.
- [970] Prajna NV, Pillai MR, Manimegalai TK, Srinivasan M. Use of Traditional Eye Medicines by corneal ulcer patients presenting to a hospital in South India. *Indian J Ophthalmol* 1999;47(1):15–8.
- [971] Verd S. Switch from antibiotic eye drops to instillation of mother's milk drops as a treatment of infant epiphora. *J Trop Pediatr* 2007;53(1):68–9.
- [972] Ghaemi S, Navaei P, Rahimirad S, Behjati M, Kelishadi R. Evaluation of preventive effects of colostrum against neonatal conjunctivitis: A randomized clinical trial. *J Educ Health Promot* 2014;3:63.
- [973] Singh M, Sugathan PS, Bhujwala RA. Human colostrum for prophylaxis against sticky eyes and conjunctivitis in the newborn. *J Trop Pediatr* 1982;28(1):35–7.
- [974] Baynham JT, Moorman MA, Donnellan C, Cevallos V, Keenan JD. Antibacterial effect of human milk for common causes of paediatric conjunctivitis. *Br J Ophthalmol* 2013;97(3):377–9.
- [975] Ibhahesebhor SE, Otobo ES. In vitro activity of human milk against the causative organisms of ophthalmia neonatorum in Benin City, Nigeria. *J Trop Pediatr* 1996;42(6):327–9.
- [976] Chaumeil C, Liotet S, Kogbe O. Treatment of severe eye dryness and problematic eye lesions with enriched bovine colostrum lactoserum. *Adv Exp Med Biol* 1994;350:595–9.
- [977] Bucolo C, Topumeci M, Salomone S, Romano GL, Leggio GM, Gagliano C, et al. Effects of Topical Fucosyl-Lactose, a Milk Oligosaccharide, on Dry Eye Model: An Example of Nutraceutical Candidate. *Front Pharmacol* 2015;6:280.
- [978] Cheng KJ. Neurobiological mechanisms of acupuncture for some common illnesses: a clinician's perspective. *J Acupunct Meridian Stud* 2014;7(3):105–14.
- [979] Lan W, Tong L. Acupuncture has effect on increasing tear break-up time: acupuncture for treating dry eye, a randomized placebo-controlled trial. *Acta Ophthalmol* 2012;90:e73.
- [980] Kim TH, Kang JW, Kim KH, Kang KW, Shin MS, Jung SY, et al. Acupuncture for the treatment of dry eye: a multicenter randomised controlled trial with active comparison intervention (artificial teardrops). *PLoS One* 2012;7:e36638.
- [981] Gong L, Sun X, Chapin WJ. Clinical curative effect of acupuncture therapy on xerophthalmia. *Am J Chin Med* 2010;38(4):651–9.
- [982] Yang L, Yang Z, Yu H, Song H. Acupuncture therapy is more effective than artificial tears for dry eye syndrome: evidence based on a meta-analysis. *Evid Based Complement Altern Med* 2015;2015:143858.
- [983] Lin T, Gong L, Liu X, Ma X. Fourier-domain optical coherence tomography for monitoring the lower tear meniscus in dry eye after acupuncture treatment. *Evid Based Complement Altern Med* 2015;2015:492150.
- [984] Nepp J, Wedrich A, Akramian J, Derbolav A, Mudrich C, Ries E, et al. Dry eye treatment with acupuncture. A prospective, randomized, double-masked study. *Adv Exp Med Biol* 1998;438:1011–6.
- [985] Tseng KL, Liu HJ, Tso KY, Woung LC, Su YC, Lin JG. A clinical study of acupuncture and SSP (silver spike point) electro-therapy for dry eye syndrome. *Am J Chin Med* 2006;34(2):197–206.
- [986] Shin MS, Kim JI, Lee MS, Kim KH, Choi JY, Kang KW, et al. Acupuncture for treating dry eye: a randomized placebo-controlled trial. *Acta Ophthalmol* 2010;88(8):e328–33.
- [987] Na KS, Han K, Park YG, Na C, Joo CK. Depression, Stress, Quality of Life, and Dry Eye Disease in Korean Women: A Population-Based Study. *Cornea* 2015;34(7):733–8.
- [988] Kim KW, Han SB, Han ER, Woo SJ, Lee JJ, Yoon JC, et al. Association between depression and dry eye disease in an elderly population. *Invest Ophthalmol Vis Sci* 2011;52:7954–8.
- [989] Li M, Gong L, Sun X, Chapin WJ. Anxiety and depression in patients with dry eye syndrome. *Curr Eye Res* 2011;36(1):1–7.
- [990] Ayaki M, Kawashima M, Negishi K, Tsubota K. High prevalence of sleep and mood disorders in dry eye patients: survey of 1,000 eye clinic visitors. *Neuropsychiatr Dis Treat* 2015;11:889–94.
- [991] DeGargino J. Children's Health and the Environment: A Global Perspective. Geneva, Switzerland: World Health Organization; 2004.
- [992] Seligman ME, Steen TA, Park N, Peterson C. Positive psychology progress: empirical validation of interventions. *Am Psychol* 2005 Jul-Aug;60(5):410–21.
- [993] Kawashima M, Uchino M, Yokoi N, Uchino Y, Dogru M, Komuro A, et al. Associations between subjective happiness and dry eye disease: a new perspective from the Osaka study. *PLoS One* 2015;10:e0123299.
- [994] Kawashima M, Uchino M, Yokoi N, Uchino Y, Dogru M, Komuro A, et al. The Association between Dry Eye Disease and Physical Activity as well as Sedentary Behavior: Results from the Osaka Study. *J Ophthalmol* 2014;2014:943786.
- [995] Sano K, Kawashima M, Ito A, Inaba T, Morimoto K, Watanabe M, et al. Aerobic exercise increases tear secretion in type 2 diabetic mice. *Invest Ophthalmol Vis Sci* 2014;55(7):4287–94.
- [996] Begley CG, Chalmers RL, Abetz L, Venkataraman K, Mertzanis P, Caffery BA, et al. The relationship between habitual patient-reported symptoms and clinical signs among patients with dry eye of varying severity. *Invest Ophthalmol Vis Sci* 2003;44(11):4753–61.
- [997] Schein OD, Tielsch JM, Munoz B, Bandeen-Roche K, West S. Relation between signs and symptoms of dry eye in the elderly. A population-based perspective. *Ophthalmology* 1997;104(9):1395–401.
- [998] Nichols KK, Nichols JJ, Mitchell GL. The lack of association between signs and symptoms in patients with dry eye disease. *Cornea* 2004;23(8):762–70.

- [999] Savini G, Prabhawat P, Kojima T, Grueterich M, Espana E, Goto E. The challenge of dry eye diagnosis. *Clin Ophthalmol* 2008;2(1):31–55.
- [1000] Adatia FA, Michaeli-Cohen A, Naor J, Caffery B, Bookman A, Slomovic A. Correlation between corneal sensitivity, subjective dry eye symptoms and corneal staining in Sjögren's syndrome. *Can J Ophthalmol* 2004;39(7):767–71.
- [1001] Bourcier T, Acosta MC, Borderie V, Borrás F, Gallar J, Bury T, et al. Decreased corneal sensitivity in patients with dry eye. *Invest Ophthalmol Vis Sci* 2005;46(7):2341–5.
- [1002] Baudouin C, Aragona P, Van Setten G, Rolando M, Irkeç M, Benítez del Castillo J, et al. Diagnosing the severity of dry eye: a clear and practical algorithm. *Br J Ophthalmol* 2014;98(9):1168–76.