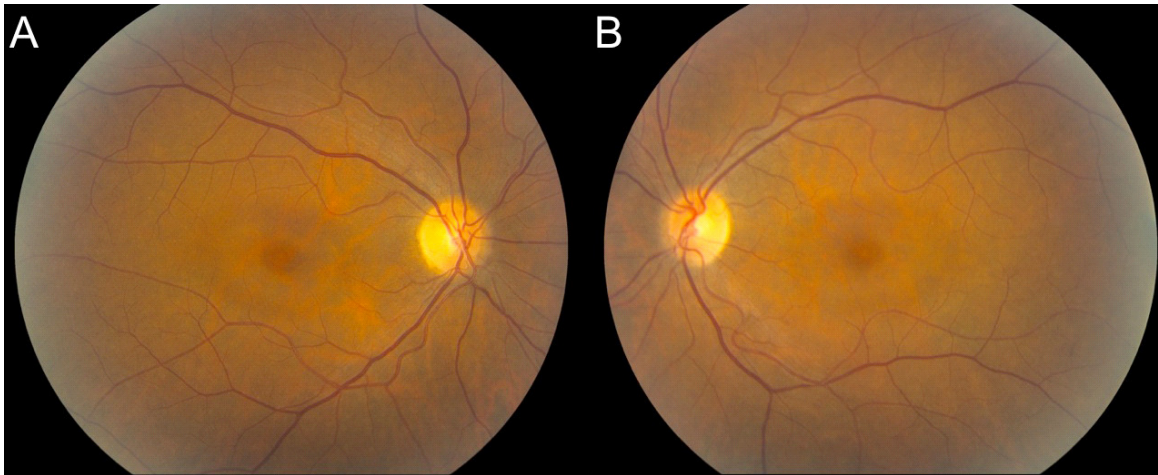

Examples of examination findings indicating medication-induced toxicity

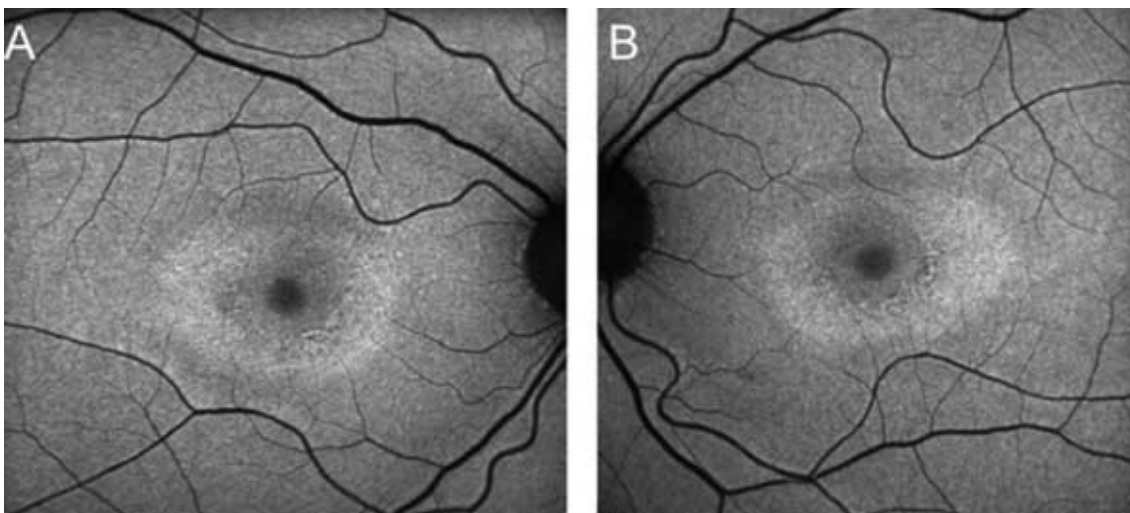
- **Fundus photo/retinal exam:**

Example showing abnormal mild paracentral depigmentation of the RPE that spares the central fovea



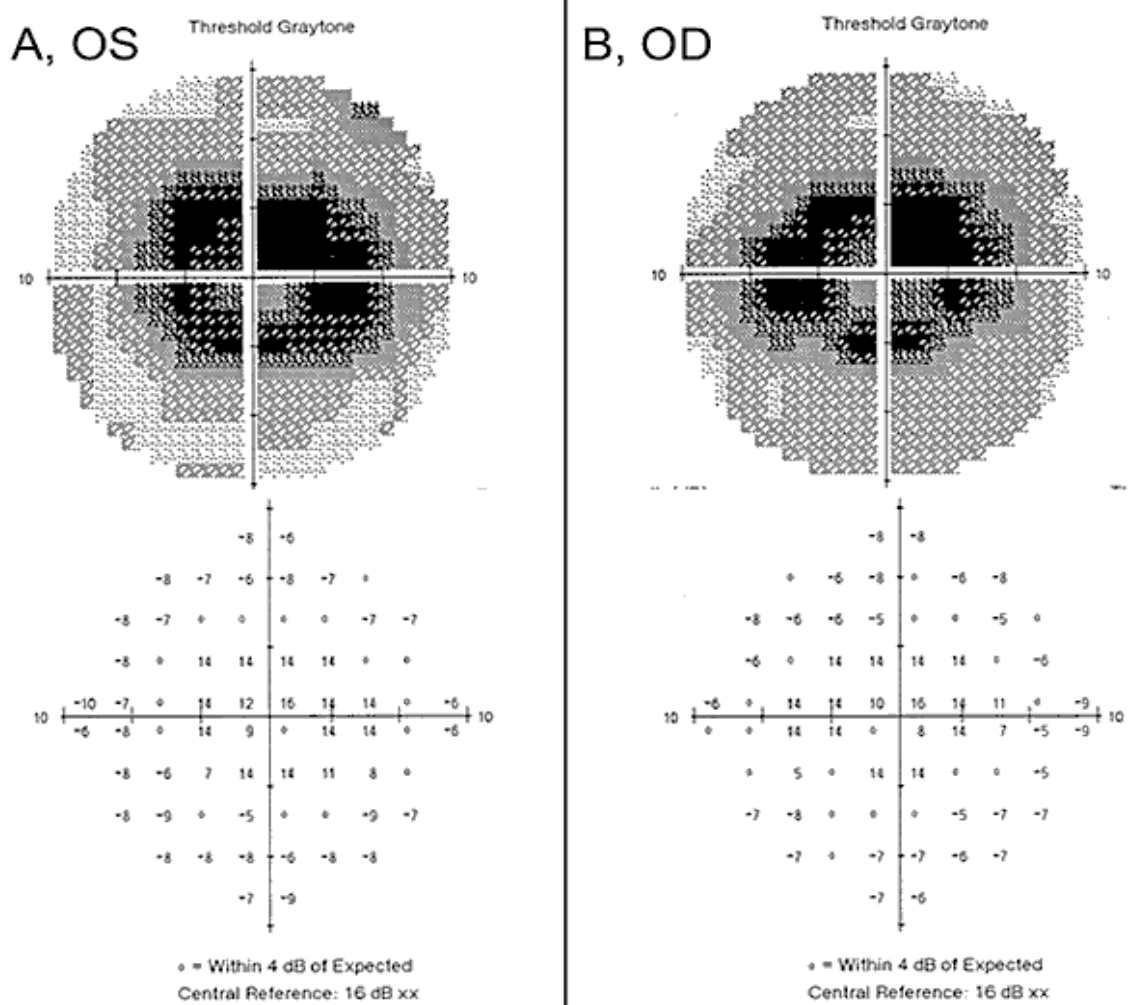
- **Auto-fluorescence imaging by scanning laser ophthalmoscope (SLO):**

Example showing an abnormal increase in signal in the parafoveal region



- **Central visual fields 10-2:**

Example demonstrating paracentral scotomas with decreased foveal sensitivity - consider abnormal



- **Spectral Domain Optical Coherence Tomography (SD-OCT):**

Example demonstrating abnormal loss of photoreceptor integrity and thinning of the outer retina in the parafoveal region (arrows)

